

Are your **MRI contrast agents** cost-effective?

Learn more about generic **Gadolinium-Based Contrast Agents**.



FRESENIUS  
KABI

caring for life

**AJNR**

**Intraoperative sonography during lumbar laminectomy: work in progress.**

G A Gooding, J E Boggan and P R Weinstein

*AJNR Am J Neuroradiol* 1984, 5 (6) 751-753

<http://www.ajnr.org/content/5/6/751>

This information is current as  
of May 16, 2024.

# Intraoperative Sonography during Lumbar Laminectomy: Work in Progress

Gretchen A. W. Gooding<sup>1</sup>  
James E. Boggan<sup>2</sup>  
Philip R. Weinstein<sup>2</sup>

**The feasibility of intraoperative sonography during lumbar laminectomy was demonstrated in six cases. The most obvious advantage was the ability to image the spinal canal anterior to the spinal cord or cauda equina, which cannot be seen directly from the posterior operative approach. A water bath of warm saline serves as an ideal acoustic window. This technique has the potential to be a significant contribution to intraoperative exploration and localization.**

There is little in the literature on the use of sonography in the visualization of diseases of the spine. DeSantos and Goldstein [1] reported on the use of sonography to visualize large tumors arising from the spine and bony pelvis causing pelvic and abdominal masses. Reid [2] identified a cervical cord cystic astrocytoma using sonography through the interlaminar spaces. Miller et al. [3] demonstrated its use in the evaluation of spinal dysraphism in children, and Scheible et al. [4] expanded on the diagnosis of occult spinal dysraphism using high-resolution real-time sonography. Forsberg and Walloe [5] investigated the sagittal diameter of the spinal canal by sonography and showed a relative stenosis in 10 patients with sciatica. Braun et al. [6], using sonography, visualized the spinal canal and its contents in 10 postoperative patients. Rubin and Dohrmann [7] reported two cases of intraoperative sonography of the spine; both cases demonstrated tumors of the spinal cord. In another series [8], they reported 10 cases of intraoperative sonography of the spine that included examples of syringomyelia, spinal cord cyst, intramedullary tumor, and extradural/intramedullary neoplasm. Knake et al. [9] described their experience with three extramedullary spinal tumors examined intraoperatively. We report our initial intraoperative experience in six patients who had lumbar laminectomy for disease entities that included spinal stenosis, arachnoiditis, and disk disease.

## Subjects and Methods

Six men were examined in the lumbosacral areas after lumbar laminectomy during the intraoperative procedure. All were examined using an ATL NeuroSectOR machine with a 3.5, 5, and 7.5 MHz transducer in parasagittal and transverse planes. The technique involves placing some sterile gel on the head of the transducer and then encasing the transducer and cord with a translucent custom-made rubber sheath. The sheath fits snugly but is further stabilized with sterile rubber bands. The operative site, rather deep to the skin surface, was filled with warm saline, and after the microbubbles had resorbed, scanning through the water bath was accomplished with ease. A clear plastic sheet placed across the flat surface of the operating panel of the sonographic machine allowed the surgical personnel to operate the unit without breaking sterile technique. Dimming the lights improved the sonographic image on the screen. Each case was video-taped with freeze-frames of particular views. Thereafter, in the sonography laboratory, the study was photographed for a more accessible permanent record.

Our cases can be summarized as follows: Case 1, with a prior lumbar laminectomy, had

Received November 28, 1983; accepted after revision March 15, 1984.

<sup>1</sup> Department of Radiology, University of California, San Francisco, and Radiology Service (114), Veterans Administration Medical Center, 4150 Clement St., San Francisco, CA 94121. Address reprint requests to G. A. W. Gooding.

<sup>2</sup> Department of Neurosurgery, University of California, San Francisco, and Veterans Administration Medical Center, San Francisco, CA 94121.

**AJNR 5:751-753, November/December 1984**  
0195-6108/84/0506-0751

© American Roentgen Ray Society



an L4–L5 disk. Case 2, with a prior lumbar laminectomy, had a mild disk protrusion at L2–L3 and at L4–L5, arachnoiditis at L4–L5, and spinal stenosis. Case 3 had a decompressive lumbar laminectomy for spinal stenosis. Case 4, with prior lumbar laminectomy, had spinal stenosis and a bulging disk at L4–L5. Case 4 had a decompressive lumbar laminectomy from T12 to L5 for spinal stenosis with a large disk protrusion at L1–L2. Case 6 had a microlaminectomy for L4–L5 disk removal.

## Results

Initially, microbubbles were prominent in the water bath of the surgical site, but after a few minutes they resorbed to produce a clear space above the dural sheath. It was not necessary to actually put the transducer on the dural sheath

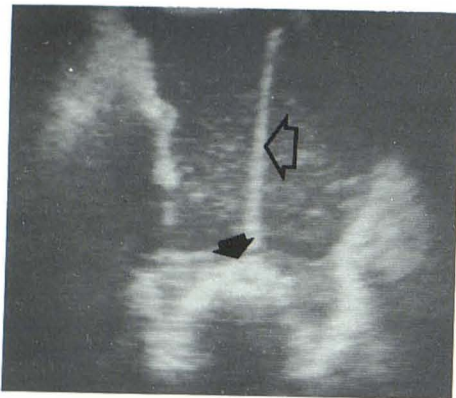

Fig. 1.—Case 1. Transverse intraoperative sonogram of L4–L5 laminectomy site. Microbubbles in saline bathe dural sac. Metal cannula (*open arrow*) demarcates dural interface (*solid arrow*), which is thickened and impedes acoustic signal to further through-transmission.

itself since the fluid acted as an effective acoustic window. With time, red blood cells and other debris would settle out of the solution to form an echogenic layer on the dural sac that could be scrambled with stirring of the liquid bath. A Bovie electrocautery device, when connected, caused significant artifact and electrical interference. Disconnection during the sonographic examination markedly improved the image.

Of the six patients, all but one had a standard lumbar laminectomy with excellent visualization of the exposed anatomy. One patient had a microlaminectomy for L4–L5 disk disease, and this small incision was not large enough to accommodate the transducer effectively. Visualization of the dural sheath was not successful in this instance.

Except for the case of microlaminectomy, the dural sheath was readily appreciated during the examinations. In case 1, dural scarring from prior laminectomy was so dense and thick that it caused acoustic shadowing beyond that interface, and no neural roots could be identified within the sac (fig. 1). In the other four patients, the dural sac was well defined, as were the nerve roots running within the sac (figs. 2 and 3). Cerebrospinal fluid (CSF) could be seen bathing the nerve roots. Protruding disks were seen easily (cases 2, 4, and 5) (figs. 2A and 3C) and were distinguished from adjacent osteophytic spurring by the presence of through-transmission of the acoustic beam behind the bulge with a disk and no through-transmission behind the protrusion caused by bony spurs. Slight rotation of the transducer could distinguish one from another when osteophytic spurs were in close association to the disk.

Irregular thickened fascia was identified over a prior laminectomy site (fig. 3C). In case 2, when L2–L3 had been exposed before further resection at L4–L5 and L5–S1, the fluid-filled dural sac markedly expanded during the anesthesiologist's manipulation of deep inspiration for a Valsalva-like maneuver of the patient (fig. 2C). Thereafter, with expiration, the dural sac decompressed with rest (fig. 2B). After decompression

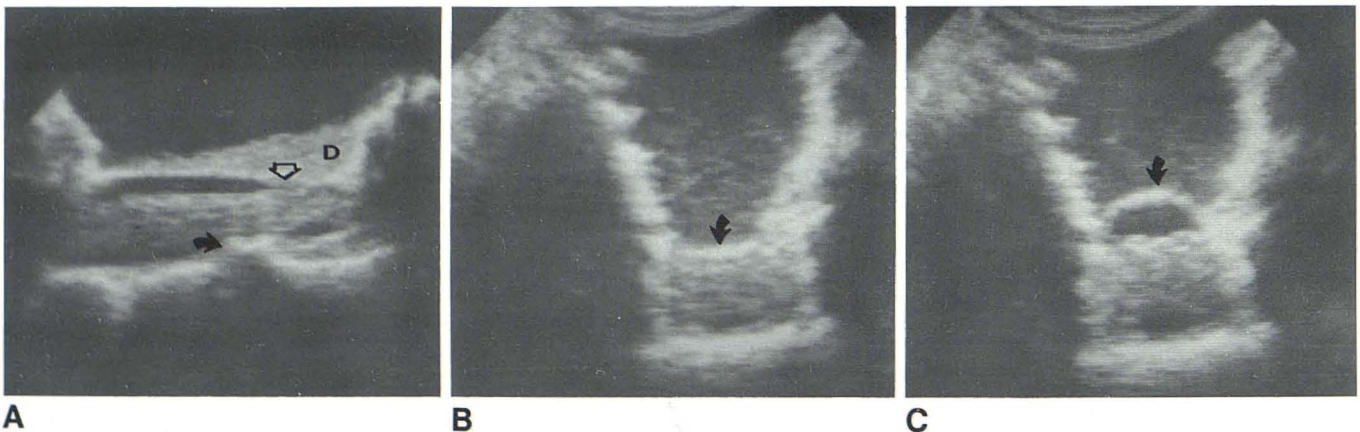


Fig. 2.—Case 2. **A**, Longitudinal intraoperative sonogram after lumbar laminectomy defines some narrowing of dural sheath posteriorly by thickening secondary to arachnoiditis (*open arrow*) and anteriorly by mildly protruding disk at L4–L5 with associated osteophytic spurring (*closed arrow*) causing acoustic shadow just inferior to disk. Some layering of debris (D) along the posterior surface of dural sac. Arachnoiditis suspected on CT by clumping of nerve roots

in dural sac was confirmed at surgery. **B**, Transverse intraoperative sonogram at L2–L3. Dural sheath is at rest (*arrow*). **C**, During Valsalva-like maneuver. Expansion of CSF volume within dural sheath (*arrow*) at L2–L3 could not be duplicated after decompressive lumbar laminectomy at lower level (L4–L5), probably because increased pressure produced by Valsalva-like maneuver was transmitted along entire length of dural sac after extensive laminectomy.



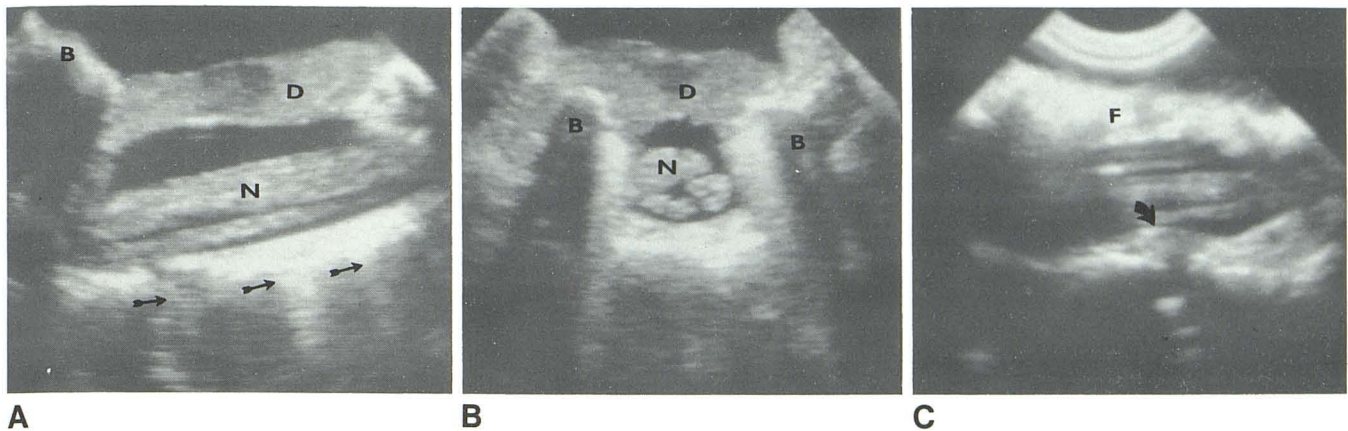


Fig. 3.—Case 4. **A**, Longitudinal intraoperative sonogram after lumbar laminectomy. Hypertrophic bone (B) from prior laminectomy, layer of debris (D) that has fallen out of solution from saline suspension onto dural sheath, nerve roots (N) bathed in CSF, and normal disk spaces (arrows). **B**, Transverse intraoperative sonogram after lumbar laminectomy. Bony facets (B), dural

sheath, CSF bathing nerve roots (N), and layer of debris (D) that has fallen out of solution from saline suspension onto dural sheath. **C**, Protruding disk is apparent at L4–L5 on longitudinal intraoperative sonogram after lumbar laminectomy (arrow). Even though overlying fascia (F) is thickened from prior laminectomy, dural sac and nerve roots are apparent.

sion of the distal sac at L4–L5 and L5–S1, which was constricted by arachnoiditis and spinal stenosis, there was no longer an apparent response of the dural sac to the Valsalva-like maneuver. Theoretically, the explanation for this response is that when distal obstruction to free expansion of the dural sac was present before laminectomy at L4–L5, a Valsalva-like maneuver produced increased intraabdominal pressure, which was transmitted to the dural sac and caused overdistension in the area of L2–L3, an area relieved of compression secondary to spinal stenosis. This focal area was free of bony restraint and susceptible to pressure changes. After decompressive laminectomy of the length of the lumbar spine, the pressure differences induced by the Valsalva-like maneuver were transmitted down the length of the dural sac, and visible changes did not occur.

### Discussion

Early experience with sonography during lumbar laminectomy suggests that it has a role to play in these operative cases. Filling of the surgical site with saline provides an ideal window to the dural sheath and nerve roots without actually touching these delicate structures with the sonographic probe. Disk protrusion, not visually apparent to the surgeon looking into the field, is readily noted anterior to the cord and can be differentiated from osteophytic spurs. After lumbar laminectomy, adhesions and narrowing of the subarachnoid space by arachnoiditis can be appreciated, and response to respiratory maneuvers is apparent (fig. 2).

Further experience is needed to elucidate the sensitivity of this technique. Our results indicate that it is a feasible technique, but at the present time its usefulness is limited to

patients who have an extensive laminectomy. When microincisions are used, there is need for transducers of pencil thickness. Further studies will evaluate its effectiveness for other applications, including visualizing bone fragments in cases of spinal fracture; detecting epidural neoplasms in metastatic disease; and revealing disk fragments, either intradural, free, and unattached or impacted beneath the longitudinal ligament.

### REFERENCES

1. DeSantos LA, Goldstein HM. Ultrasonography in tumors arising from the spine and bony pelvis. *AJR* 1977;129:1061–1064
2. Reid MH. Ultrasonic visualization of a cervical cord cystic astrocytoma. *AJR* 1978;131:907–908
3. Miller JH, Reid BS, Kemberling CR. Utilization of ultrasound in the evaluation of spinal dysraphism in children. *Radiology* 1982;143:737–740
4. Scheible W, James HE, Leopold GR, Hilton SW. Occult spinal dysraphism in infants: screening with high-resolution real-time ultrasound. *Radiology* 1983;146:743–746
5. Foresberg L, Walloe A. Ultrasound in sciatica. *Acta Orthop Scand* 1982;53:393–395
6. Braun IF, Raghavendra VN, Kricheff II. Spinal cord imaging using real-time high-resolution ultrasound. *Radiology* 1983;147:459–465
7. Rubin JM, Dohrmann GJ. Work in progress: intraoperative ultrasonography of the spine. *Radiology* 1983;146:173–175
8. Dohrmann GJ, Rubin JM. Intraoperative ultrasound imaging of the spinal cord: syringomyelia, cysts, and tumors—a preliminary report. *Surg Neurol* 1982;18:395–399
9. Knake JE, Chandler WF, McGillicuddy JE, et al. Intraoperative sonography of intraspinal tumors; initial experience. *AJNR* 1983;4:1199–1201