

Are your MRI contrast agents cost-effective?

Learn more about generic Gadolinium-Based Contrast Agents.



**FRESENIUS
KABI**

caring for life

AJNR

Simplified patient positioning to reduce beam hardening in CT of the lower neck.

G D Harvey, D P Mayer and P D Radecki

AJNR Am J Neuroradiol 1984, 5 (6) 796

<http://www.ajnr.org/content/5/6/796.citation>

This information is current as
of May 7, 2024.

Simplified Patient Positioning to Reduce Beam Hardening in CT of the Lower Neck

Gregory D. Harvey,¹ David P. Mayer, and Paul D. Radecki

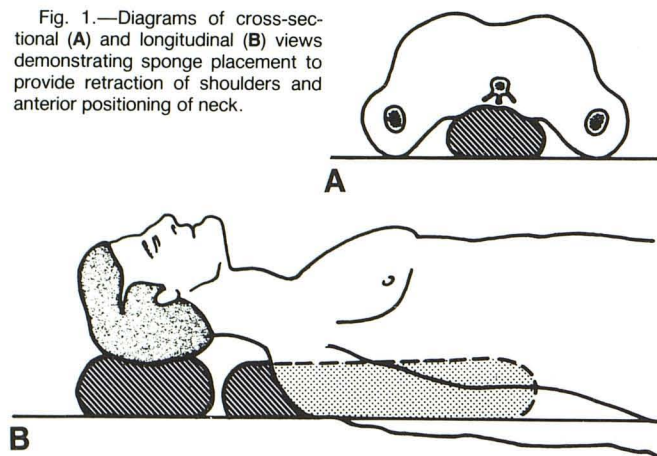
Certain regions of the body can be relatively difficult to image optimally by computed tomography (CT). The lower neck falls into this category. A routine transverse image at this level includes the shoulders, which can cause beam hardening [1]. Beam hardening reduces subject contrast and often produces streak artifacts between the shoulders [2, 3]. This image degradation is especially troublesome when searching for small soft-tissue masses in the neck, such as parathyroid adenomas [4]. Although software packages are available to compensate for beam hardening, the correction is only partial; some deleterious effects on the interpretative value of lower neck scans persist [5].

We present a positioning technique that reduces the beam hardening encountered in CT evaluation of the lower neck. A commercially available cylindrical or triangular sponge about 15 cm in diameter and 35 cm long is placed between the scapulae of the supine patient while a second, smaller sponge is used to elevate the head (fig. 1). This allows for posterior positioning of the shoulders relative to the chest and neck, thus providing significant exclusion of the shoulders from the plane of interest and permitting transverse CT imaging of the lower neck without extensive beam hardening.

Our CT studies of the neck are performed without gantry angulation or target image reconstruction on the Siemens DR3 unit, which has a continuously variable reconstruction circle. The magnification factor is adjusted to maximally enlarge the region of interest without excluding significant details (average magnification, $\times 3.5$). Our neck images usually are obtained with 4.5 sec, 125 kVp, and 345 mAs exposures. The patient usually is instructed to suspend respiration and swallowing during the scanning cycle. If specific structures such as the vocal cords are being evaluated, quiet respiration or phonation during the scanning cycle sometimes provides useful information. We usually administer intravenous contrast material via continuous infusion and/or bolus injection to provide delineation of vascular structures and enhancement of soft-tissue masses.

A recent technical note suggests the use of a custom-formed device to facilitate CT examination of the lower neck [6]. We have used our relatively simple technique for over a year with moderate success. However, since satisfactory application of the technique requires a reasonable degree of shoulder mobility, it may be less effective for patients in whom such mobility is limited (e.g., extremely obese patients or those whose mobility is pathologically restricted).

Fig. 1.—Diagrams of cross-sectional (A) and longitudinal (B) views demonstrating sponge placement to provide retraction of shoulders and anterior positioning of neck.



REFERENCES

1. Mancuso AA, Hanafee WN. *Computed tomography of the head and neck*. Baltimore: Williams & Wilkins, 1981:1-11
2. Coulam CM, Erickson JJ. Image considerations in computed tomography. In: Coulam CM, Erickson JJ, Rollo FD, James AE. *The physical basis of medical imaging*. New York: Appleton-Century-Crofts, 1981:189-211
3. Duerinckx AJ, Macovski A. Polychromatic streak artifacts in CT scanning. *J Comput Assist Tomogr* 1978;2:481-487
4. Adams JE, Adams PH, Mamtora H, Isherwood I. Computed tomography and the localization of parathyroid tumors. *Clin Radiol* 1981;32:251-254
5. McDavid WD, Waggner RD, Payne WH, Dennis MJ. Correction for spectral artefacts in cross-sectional reconstruction from x-rays. *Med Phys* 1977;4:54-57
6. Stark DD, Moss AA, Gooding GAW, Clark OH. Parathyroid scanning by computed tomography. *Radiology* 1983;148:297-299

Received October 31, 1983; accepted after revision May 16, 1984.

¹ Department of Diagnostic Imaging, Temple University Hospital, 3401 N. Broad St., Philadelphia, PA 19140. Address reprint requests to G. D. Harvey.