

# Generic Contrast Agents

Our portfolio is growing to serve you better. Now you have a *choice*.



[VIEW CATALOG](#)

# AJNR

## **Vertebral arteriovenous fistula: an unusual complication of Swan-Ganz catheter insertion.**

D P Colley

*AJNR Am J Neuroradiol* 1985, 6 (1) 103-104

<http://www.ajnr.org/content/6/1/103.citation>

This information is current as  
of May 10, 2025.

## Vertebral Arteriovenous Fistula: An Unusual Complication of Swan-Ganz Catheter Insertion

David P. Colley<sup>1</sup>

The leading causes of trauma to the major craniocerebral vessels include penetrating and nonpenetrating trauma [1, 2]. Because the vertebral artery is confined to the incomplete bony canal formed by the successive foramina in the transverse processes of the upper cervical vertebrae, it is less susceptible to penetrating injury than is the carotid artery [2].

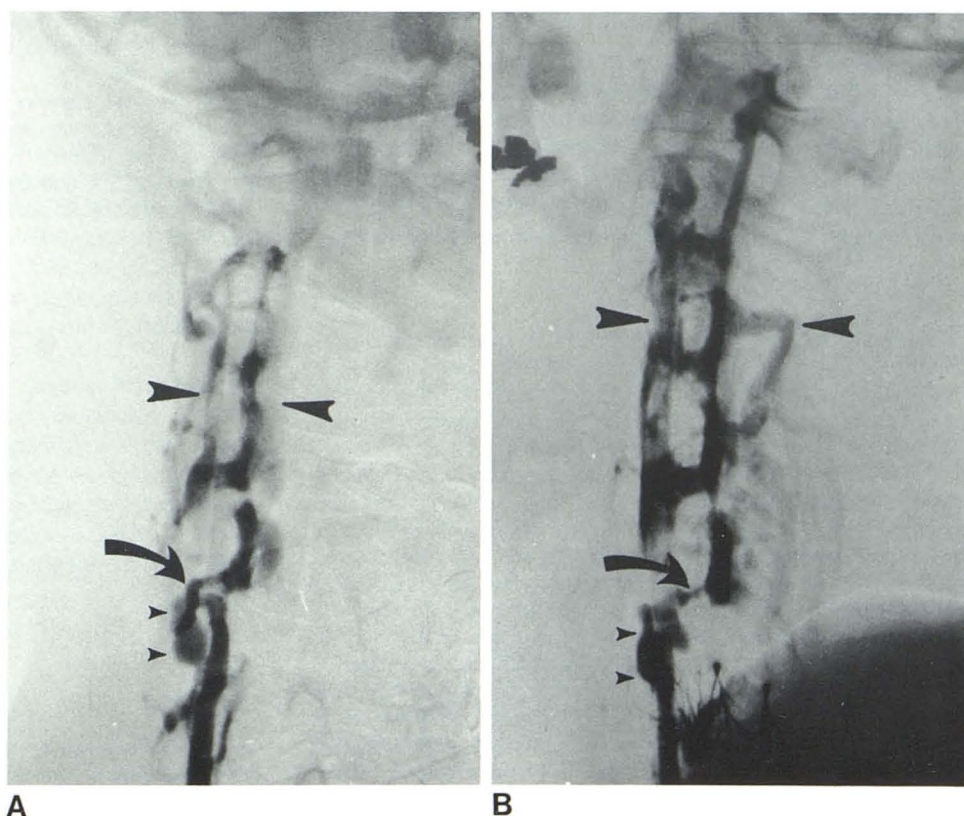
A review of the literature has uncovered no previous examples of pseudoaneurysm or arteriovenous fistula specifically involving the vertebral artery as a complication of percutaneous internal jugular vein cannulation [3, 4]. We describe

such a complication, its angiographic evaluation, and the surgical correction required, emphasizing the anatomic relations that make this problem a rare complication of venous catheterization.

### Case Report

A 58-year-old man with aortic stenosis was admitted to the hospital for aortic valve replacement. As part of his intraoperative management, an 8-French Swan-Ganz catheter was introduced percutaneously in the standard manner [5] through the right internal jugular

Fig. 1.—Left posterior oblique (A) and lateral (B) subtraction films from right vertebral arteriography demonstrate  $5 \times 9$  mm vertebral pseudoaneurysm (*small arrowheads*) and arteriovenous fistula (*curved arrow*). Rapid filling of numerous adjacent paravertebral veins (*large arrowheads*).



Received August 4, 1983; accepted after revision October 7, 1983.

<sup>1</sup> Department of Radiology, Hospital of Saint Raphael, New Haven, CT 06511.

vein and its tip positioned in the right pulmonary artery. Position of the catheter was confirmed by pressure tracings and postoperative chest radiographs until the catheter was removed 4 days after surgery. The patient recovered fully and was discharged from the hospital.

Routine follow-up examinations revealed a right-sided cervical bruit extending to the right sternal border. The bruit was audible to the patient as well as to his physicians. Because of increasing loudness of the bruit and right-sided headache, he was referred for angiographic investigation of what was thought clinically to be a small arteriovenous fistula between the right carotid artery and jugular vein. A right carotid arteriogram demonstrated a normal carotid artery and jugular vein. A right vertebral angiogram (fig. 1) outlined a false aneurysm of that artery at the level of the sixth cervical vertebra. Associated with the false aneurysm was prompt filling of the paravertebral venous plexus through a fistula originating at the same level.

At operation the right transverse processes of C5 and C6 were removed to gain access to the artery and to isolate the venous connection. The vertebral artery was ligated proximally and distally to the site of the fistula as was the direct venous communication. The patient recovered without further complication.

## Discussion

Complications of percutaneous internal jugular vein cannulation are quite uncommon in view of the large numbers of such procedures that are currently performed. The lateral approach is recognized as being associated with a greater risk of complication than the now standard approach from above (as was used in our patient), in which the needle is aimed at the suprasternal notch and generally follows the direction of flow in the jugular vein [5]. The posteromedial location of the vertebral artery relative to the carotid artery and jugular vein coupled with the protection afforded by the bony foramina transversaria make the vertebral artery relatively immune to injury in comparison with neighboring ves-

sels. Injury to the vertebral artery secondary to carotid puncture or direct vertebral puncture for percutaneous angiography, though well known, has decreased dramatically as a result of the increased use of catheter techniques for angiographic studies.

Occasionally the vertebral artery takes an anomalous course, entering its bony canal not at C6 but at a higher level—anywhere from C5 to C1 [6]. No such anomaly was present in our patient. The lack of any such congenital variation only serves to underscore the fortuitous nature of a needle misdirection all the way through the jugular vein with concomitant laceration of both the vertebral artery and its surrounding venous complex on the first (and successful) attempt at jugular vein cannulation. Nonetheless, this complication must be added to the potential hazards of this technique.

## REFERENCES

1. Newton TH, Mani RL. The vertebral artery. In: Newton TH, Potts DG, eds. *Radiology of the skull and brain*, vol 2: *Radiography*. St. Louis: Mosby, 1974:1693-1700
2. Davidson KC, Weiford EC, Dixon GD. Traumatic vertebral artery pseudoaneurysm following chiropractic manipulation. *Radiology* 1975;115:651-652
3. Mitchell GE, Clark RA. Complications of central venous catheterization. *Radiology* 1979;133:467-476
4. Shield CF, Richardson JD, Buckley CJ, Hagood CO. Pseudoaneurysm of the brachiocephalic arteries: a complication of percutaneous internal jugular vein catheterization. *Surgery* 1975;78:190-194
5. Jernigan WR, Gardner WC, Mahr MM, Wilburn JL. Use of the internal jugular vein for placement of central venous catheter. *Surg Gynecol Obstet* 1970;130:520-524
6. Taveras JM, Wood EH. Cerebral angiography. In: *Diagnostic neuroradiology*, 2d ed. Baltimore: Williams & Wilkins, 1976:779-780