

Are your MRI contrast agents cost-effective?

Learn more about generic **Gadolinium-Based Contrast Agents**.



**FRESENIUS
KABI**

caring for life

AJNR

Computed Tomography and Chymopapain Chemonucleolysis: Preliminary Findings

Ben Maurice Brown, Edward H. Stark, Garry Dion and Hirohisa Ono

AJNR Am J Neuroradiol 1985, 6 (1) 51-54

<http://www.ajnr.org/content/6/1/51>

This information is current as
of March 27, 2025.

Computed Tomography and Chymopapain Chemonucleolysis: Preliminary Findings

Ben Maurice Brown¹
Edward H. Stark²
Garry Dion³
Hirohisa Ono⁴

Ten lumbar disk levels in nine patients were examined by computed tomography (CT) before and 6 weeks after chymopapain chemonucleolysis of herniated nucleus pulposus (HNP). Patient selection for chemonucleolysis was partly based on CT scans demonstrating morphologic HNP criteria favoring a successful treatment outcome. Posttreatment CT scans disclosed a measurable HNP size decrease of 1–3 mm at nine of 10 levels studied as well as an increase in HNP attenuation at many levels. CT findings correlated closely with objective clinical parameters used to assess treatment outcomes.

Over the past decade chemonucleolysis therapy in selected cases of lumbosacral herniated nucleus pulposus (HNP) has gained increasing acceptance as an alternative to surgical discectomy, laminectomy, and fusion [1–8]. Several recent large-scale clinical evaluations have reported 70%–74% improvement rates in symptoms and signs after chemonucleolysis [9–13] compared with a 41% improvement rate after placebo intradiskal injections [14]. Furthermore, a recent prospective study reported a 91% clinical improvement rate for chymopapain-treated patients who had failed to improve after recent intradiskal placebo injections [14].

Clinical improvement after chymopapain chemonucleolysis appears to be from marked HNP size reduction, which results in decreased mass effect on adjacent nerve roots [15]. To date, clinical evaluations of chemonucleolysis outcomes have relied primarily on changes in symptomatic complaints and physical findings. However, a recently published text on diagnostic imaging of spinal column disorders includes three brief reports of computed tomographic (CT) findings in postchemonucleolysis patients [16–18]. Insofar as CT served as the primary imaging method guiding selection of chemonucleolysis patients at our institution, we undertook to evaluate chemonucleolysis outcomes by CT in patients treated by this means at our hospital.

This article appears in the January/February 1985 issue of *AJNR* and the April 1985 issue of *AJR*.

Received February 2, 1984; accepted after revision August 3, 1984.

¹ Department of Radiology, Computed Tomography Section, Kaiser Sunnyside Medical Center, 10200 S.E. Sunnyside Rd., Clackamas, OR 97015. Address reprint requests to B. M. Brown.

² Department of Orthopedics, Kaiser Sunnyside Medical Center, Clackamas, OR 97015.

³ Department of Radiology, Ultrasound Section, Kaiser Sunnyside Medical Center, Clackamas, OR 97015.

⁴ Department of Neurosurgery, Kaiser Sunnyside Medical Center, Clackamas, OR 97015.

AJNR 6:51–54, January/February 1985

0195–6108/85/0601–0051 \$00.00

© American Roentgen Ray Society

Subjects and Methods

The first nine patients treated with chemonucleolysis at our institution between September 1983 and May 1984 were included in our prospective study. Patients were scanned 1 week before and 6 weeks after treatment. Ten chemonucleolysis-treated lumbosacral disk levels were evaluated before and after chemonucleolysis.

Patients were selected for chemonucleolysis therapy by E. H. S. and H. O. after meeting each of seven criteria: (1) persistence of unremitting sciatica symptoms for at least 12 months without treatment or for at least 3 months during a trial of conservative therapy; (2) ipsilateral extensor hallucis longus weakness for patients with L4–L5 HNP; (3) diminution of ipsilateral Achilles tendon reflex for patients with L5–S1 HNP; (4) positive straight-leg-raising test; (5) positive electromyographic findings; (6) CT findings of HNP without distally migrated disk fragments; and (7) patient preference for chemonucleolysis therapy over the alternative of either continued conservative management or surgical discectomy and fusion.

From September to December 1983, scanning was performed on a GE 8800 CT/T scanner using 120 kVp, 400 mA, 3 msec pulse width, and 9.6 sec scan time. Prospective Soft Tissue

TABLE 1: CT Changes after Chemonucleolysis

Case No.	Level	Mean HNP Size (mm)			Relative HNP Attenuation (H)		
		Pre-treatment	Post-treatment	Change	Pre-treatment	Post-treatment	Change
1	L3-L4	7	5	-2	40	47	+7
1	L4-L5	8	6	-2	44	50	+6
2	L5-S1	8	7	-1	105	125	+20
3	L5-S1	9	7	-2	90	89	-1
4	L4-L5	7	5	-2	37	40	+10
5	L4-L5	7	4	-3	89	89	0
6	L4-L5	8	6	-2*	60	70	+10*
7	L5-S1	7	4	-3	45	57	+12
8	L5-S1	5	4	-1	78	84	+6
9	L5-S1	8	5	-3	121	131	+10
10	L5-S1	5	5	0	101	100	-1

Note.—HNP = herniated nucleus pulposus.

* Rescanning at 12 weeks postchymopapain disclosed minimal interval progression in HNP size decrease (from -2 to -3 mm) and relative attenuation increase (from +10 to +14 H) since 6 week postchymopapain scan.

ReView Reconstruction algorithm was used with target magnification to a 20 cm field of view using 35 or 42 cm norms and 1.7 photographic magnification of axial images at soft-tissue settings. From January to May 1984, scanning was performed on a GE 9800 B CT/T scanner using 140 kV, 170 mA, 3 sec scan time. Standard reconstruction algorithm with a 12.8 cm field of view and 512 × 512 display matrix. All axial scans were obtained using 5 mm collimation, 3 mm consecutive intervals (2 mm through narrow interspaces), and gantry angulation approximating interspaces. All axial scans were photographed at soft-tissue settings (width, 150–250 H; variable levels) using a one-on-one format. All axial scans were also rephotographed at bone settings (width, 1200–1500 H; level, 350–450 H) without magnification using a four on one format.

All GE 8800 scans requiring comparison with GE 9800 B scans were enlarged to a 512 × 512 display matrix before comparison. Scans clearly disclosing HNPs were photographed three times: unblinked, blinked for HNP, and blinked for thecal sac using a blink window of 25 H. Careful matching of anatomic landmarks was performed to select the most similar axial images depicting HNPs on pre- and posttreatment scans.

Perfect matching of all anatomic landmarks on pre- and posttreatment scans was not possible due to the 6 week interval between these scans as well as the interspace narrowing that frequently occurred after chymopapain injections. Optimal matching was performed by making comparisons of all adjacent scans obtained at 2–3 mm consecutive intervals through the disk space of interest on pre- and posttreatment scans. The single pair of matched pre- and posttreatment axial scans affording clearest HNP visualization was selected for HNP size and attenuation measurements in all cases. These scans usually disclosed the largest midsagittal HNP dimension demonstrable on any axial image.

Caliper measurements of maximal HNP size (to the nearest millimeter) were performed in the parasagittal plane by two observers (B. M. B. and G. D.) without knowledge of clinical outcome of chemonucleolytic treatment. The difference between pre- and posttreatment maximal HNP size measurements was then determined for each level studied.

Pre- and posttreatment HNP attenuations were then interactively measured using blink-level adjustments on the same axial images selected for HNP size measurements. Each image was first examined while blinking the majority of HNP pixels, then reexamined while blinking the majority of thecal sac pixels. Absolute attenuation values (in Hounsfield units) were then recorded for HNP (A_{HNP}) and for thecal sac (A_{TS}) based on blink-mode measurements. As an internal control for variable beam-hardening artifacts generated by tissues surrounding the HNP, thecal sac attenuation values were used to calculate a

relative HNP attenuation (RA_{HNP}) in accordance with the formula: $RA_{HNP} = A_{HNP} - A_{TS}$. Posttreatment change in relative HNP attenuation (ΔRA_{HNP}) was then calculated: $\Delta RA_{HNP} = RA_{HNP}$ (posttreatment) - RA_{HNP} (pretreatment).

Clinical evaluations of posttreatment outcomes were performed 6 weeks after chymopapain by E. H. S. and H. O. who had selected chemonucleolysis patients and performed the chymopapain injections. Clinical outcomes were rated without knowledge of CT findings on a 1–5 scale (least to most) using parameters of reliability of patient history, improvement in presenting symptomatic complaints, and improvement in presenting abnormal physical findings. Improvement was rated from 1 (no improvement) to 5 (marked improvement). Patients were also assessed in terms of resumption of prior employment when applicable.

Results

Pre- and postchemonucleolysis CT measurements of HNP size and density are presented in table 1. Nine of 10 levels showed measurable HNP size decreases of 1–3 mm after chymopapain injection (figs. 1 and 2), although these size changes were not always obvious on initial inspection of hard-copy scans. These measurable changes represented a 12.5%–43.5% diminution in initial HNP size 6 weeks after treatment. A further slight HNP diminution (from 2 to 3 mm) was also noted 6–12 weeks posttreatment in a single case scanned twice after chemonucleolysis (case 6). Many of the levels disclosing HNP reductions also showed interspace narrowing on lateral scout views as well as interval appearance of central interspace gas collections. About one-half of levels also showed at least a 10 H increase in relative HNP density after treatment (fig. 3).

Clinical evaluation data are presented in table 2. Seven of nine patients disclosed moderate to marked improvement in presenting symptoms and signs. Two patients reported new onset of diffuse back pain without radicular symptoms or signs during the first month after treatment. Both of these patients disclosed marked improvement of presenting symptoms and physical findings at rescanning. One patient (case 10) reported no symptomatic relief after chemonucleolysis and disclosed neither an improvement in physical findings nor size decrease in a moderately large HNP with possible migrated disk fragment. Another patient (case 1) denied any

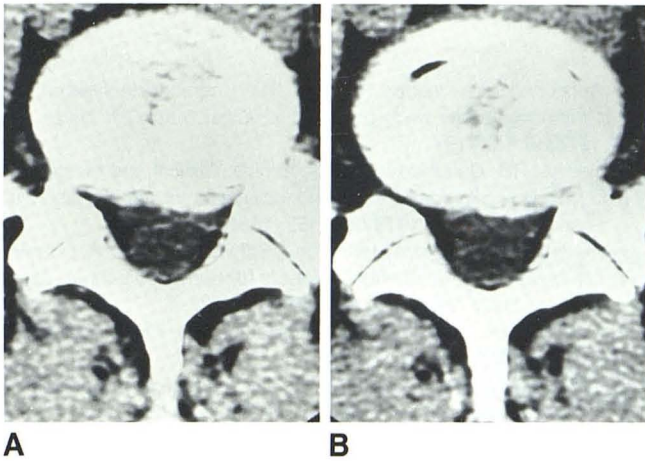


Fig. 1.—Case 8. HNP at L5–S1. **A**, Before chemonucleolysis. **B**, After chemonucleolysis. HNP is 1 mm smaller. Improvement in presenting symptoms and signs.

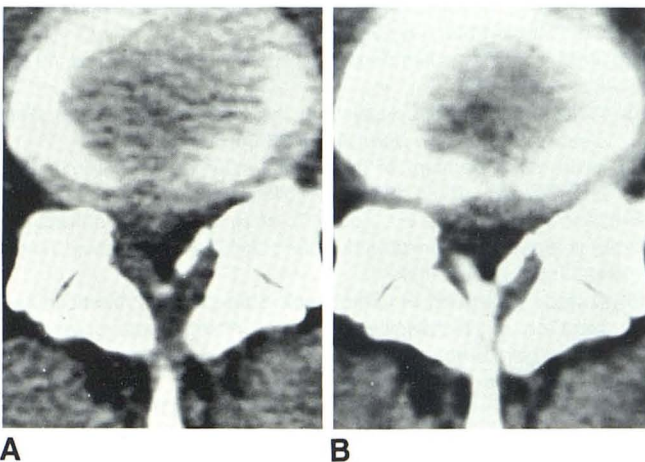


Fig. 2.—Case 4. HNP at L4–L5. **A**, Before chemonucleolysis. **B**, After chemonucleolysis. HNP is 2 mm smaller. Improvement in presenting symptoms and signs.

symptomatic relief despite unequivocal improvement in presenting signs as well as HNP size decreases on CT scans through each of two treated disks. Concordance between improvement in presenting abnormalities on physical examination and HNP size decreases on CT scans was noted in nine of 10 levels studied.

Discussion

Chymopapain is a proteolytic enzyme that lyses voluminous chondromucoprotein gel complexes in HNP fragments. Both the proteoglycans (glycosamino glyco-gen) and the intercellular matrix comprising chondromucoproteins appear to be hydrolysed by chymopapain, [19, 20]. Collagen fibers that, in addition to chondromucoproteins, constitute a major structural component of the nucleus pulposus, are unaffected by chymopapain [20]. Chondromucoprotein gel complexes (due

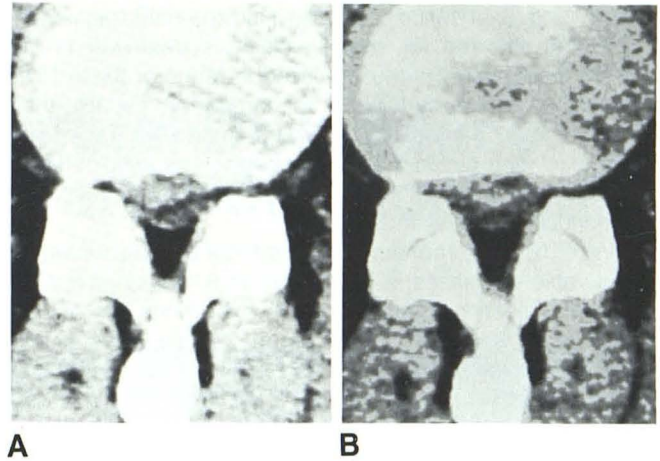


Fig. 3.—Case 1. HNP at L3–L4. **A**, Before chemonucleolysis. Mild central canal stenosis. **B**, After chemonucleolysis. Blink-mode display suggests increase in absolute HNP attenuation from 53 H before to 78 H after chemonucleolysis. Patient rated as unreliable historian who disclosed 3 mm decrease in HNP size and improvement in physical findings but denied symptomatic relief.

TABLE 2: Clinical Changes after Chemonucleolysis

Case No.	Level	Reliability of Patient History	Improvement over Presentation in:		Resumption of Employment
			Symptoms	Signs	
1	L3–L4	2	1	3	NA
1	L4–L5	2	1	3	NA
2	L5–S1	5	5	5	Yes
3	L5–S1	5	5	5	Yes
4	L4–L5	5	5	4	Yes
5	L4–L5	5	3	4	NA
6	L4–L5	3	4	5	NA
7	L4–L5	5	4	5	NA
8	L4–L5	5	5	5	Yes
9	L5–S1	5	5	5	Yes
10	L5–S1	5	1	1	No

Note.—Improvement was rated from 1 (no improvement) to 5 (marked improvement). NA concerns patients receiving disability compensation for an extended period before chemonucleolysis.

to their high water-binding capacity) have a much greater volume than collagen fibers and hence serve as the major determinant of HNP fragment size [21]. This chymopapain-induced hydrolysis of HNP chondromucoproteins acts to reduce HNP fragment size and extrinsic mass effect on adjacent nerve roots.

Chymopapain binds strongly and immediately upon contact with chondromucoprotein complexes after intradiskal injection [20, 22]. Thus, hydrolytic activity remains closely localized to the site of injection. Furthermore, chymopapain undergoes early rapid inactivation by circulating proteolytic enzyme inhibitors in plasma (alpha 2 macroglobulins), and delayed antibody formation to the chymopapain enzyme also occurs [15]. The resulting spatial and temporal constraints on the extent of chymopapain action significantly influences HNP morphology criteria for chemonucleolysis patient selection.

Several widely accepted patient HNP morphology criteria favor successful chemonucleolysis outcome: (1) relatively small HNP size, (2) localization of HNP at posterior disk

margin, and (3) absence of distally migrated HNP fragments.

Patients selected for chemonucleolysis treatment in the current study were readily assessed in terms of these HNP morphology criteria by CT. CT appeared more capable than myelography of diagnosing distally migrated HNP fragments, which excluded patients as chemonucleolysis candidates at our institution. As a result, CT served an essential function in chemonucleolysis patient selection.

Nine of 10 posttreatment CT scans in our patients disclosed measurable decreases in HNP sizes at 6 weeks after chymopapain injections. Absolute HNP size decreases of 1–3 mm at times were not obvious on cursory visual inspection and required careful measurement of HNP size on pre- and posttreatment scans closely matched for anatomic location. An earlier study [23] demonstrated that decreases in vertebral body interspaces occurred primarily within 2 months postchemonucleolysis, although minimal additional decreases were observed up to 6 months. Although a minimal incremental HNP size decrease 6–12 weeks posttreatment was noted in a single instance in our study, it appeared that CT was capable of routinely demonstrating HNP size changes at 6 weeks after chemonucleolysis.

Many disk levels evaluated in our study disclosed a measurable change in HNP attenuation after chemonucleolysis. This increase in posttreatment HNP density probably reflects desiccation of HNP material after chymopapain injection. A recent magnetic resonance imaging study of lumbar disk herniation [24] suggested that desiccation of HNP material may also be the mechanism responsible for an observed decrease in the normal high-intensity nucleus pulposus signal after chemonucleolysis.

Improvement in objective physical findings agreed closely with CT findings of decreased HNP size in the current study. Most patients showed improvement in initial symptoms and signs at 6 weeks after chymopapain treatment. Most employed patients were able to return to work after treatment. One patient, rated as an unreliable historian with a long-term unemployment record, denied any symptomatic relief after treatment despite unequivocal improvement in presenting physical findings and a decrease in HNP size on CT. Mild central canal stenosis was present on this patient's scans and may have contributed to persistence of his symptoms. A review of this case suggested that this patient should probably not be regarded as a treatment failure due to improvement in both physical findings and decrease in HNP size on CT scans. The significance of two instances of initial diffuse back pain posttreatment is unclear, although both of these patients disclosed improvement in both presenting symptoms and signs, as well as CT findings by 6 weeks after chymopapain injection.

Our preliminary experience suggests that CT is capable of detecting HNP size decreases at 6 weeks after chemonucleolysis and thus may contribute to the objective evaluation of outcome for this treatment. Additional experience with pre- and postchemonucleolysis CT should help define the role of CT in patients who report persistent posttreatment symptomatology and might be uniformly designated as treatment failures in the absence of objective treatment outcome criteria.

REFERENCES

1. Apfelbach HW, Jacobs RL, Ray RD. Chemonucleolysis in the treatment of low back pain and sciatica. *Surg Clin North Am* **1975**;55:187–197
2. Herrick RB, Daugherty JS, Hoover BB. Clinical and electromyographic evaluation after chemonucleolysis for lumbar disc disease. *South Med J* **1978**;68:1552–1555
3. Martins AN, Ramirez A, Johnston J, Schwetschenau PR. Double-blind evaluation of chemonucleolysis for herniated lumbar discs. Late results. *J Neurosurg* **1978**;49:816–827
4. Massaro TA, Javid M. Chemonucleolysis. *J Neurosurg* **1977**;46:696–697
5. Schoedinger GR III, Ford LT Jr. The use of chymopapain in ruptured lumbar discs. *South Med J* **1982**;64:333–336
6. Smith L. Enzyme dissolution of the nucleus pulposus in humans. *JAMA* **1964**;187:177–180
7. Watts C. Chemonucleolysis: an appeal for objectivity. *J Neurosurg* **1975**;42:488
8. Ford LT. Chymopapain for chemonucleolysis for lumbar disc disease in the United States. *Orthop Rev* **1978**;7:25–28
9. Dabezies EJ, Brunet M. Chemonucleolysis vs laminectomy. *Orthopedics* **1978**;1:26–29
10. McCulloch JA. Chemonucleolysis: experience with 2000 cases. *Clin Orthop* **1980**;146:128–135
11. McCulloch JA. Chemonucleolysis. *J Bone Joint Surg* **1977**;59:45–52
12. Wiltse LL. Chemonucleolysis in the treatment of lumbar disc disease. *Orthop Clin North Am* **1983**;14:605–622
13. Javid MJ. Treatment of herniated lumbar disc syndrome with chymopapain. *JAMA* **1980**;243:2043–2048
14. Javid MJ, Nordbye EJ, Ford LT, et al. Safety and efficacy of chymopapain in herniated nucleus pulposus with sciatica. *JAMA* **1983**;249:2489–2494
15. American Academy of Orthopaedic Surgeons and American Association of Neurological Surgeons. *Postgraduate course on intradiscal therapy* (syllabus). Los Angeles: University of Southern California, **1983**
16. Coin CG, Coin JT, Garrett JK. Experimental CT controlled discolysis. In: Post MJD, ed. *Computer tomography of the spine*. Baltimore, Williams & Wilkins, **1983**
17. McCulloch JS. Computed tomography before and after chemonucleolysis. In: Post MJD, ed. *Computer tomography of the spine*. Baltimore: Williams & Wilkins, **1983**
18. Heithoff KP. High resolution computer tomography and stenosis. In: Post MJD, ed. *Computer tomography of the spine*. Baltimore: Williams & Wilkins, **1983**
19. Zaleske DJ, Ehrlich MG, Huddleston JI Jr. Combined biochemical and clinical investigation of chemonucleolysis failures. *Clin Orthop* **1977**;126:121–126
20. Postacchini F, Bellocci M, Ippolito E, McCulloch JA. Effects of chymopapain on intervertebral disc and cartilage. *Ital J Orthop Traumatol* **1982**;8:445–455
21. Garvin PJ, Jennings RB, Stern IJ. Enzymatic digestion of the nucleus pulposus: a review of experimental studies with chymopapain. *Orthop Clin North Am* **1977**;8:27–35
22. Gesler RM. Pharmacologic properties of chymopapain. *Clin Orthop* **1969**;67:47–51
23. Bitz DM, Ford LT. An evaluation of narrowing following intradiscal injection of chymopapain. *Clin Orthop* **1977**;129:191–195
24. Chafetz NI, Genant HK, Moon KL, Helms CA, Morris JM. Recognition of lumbar disk herniation with NMR. *AJNR* **1984**;5:23–26, *AJR* **1983**;141:1153–1156