

Are your **MRI contrast agents** cost-effective?

Learn more about generic **Gadolinium-Based Contrast Agents**.



FRESENIUS
KABI

caring for life

AJNR

Value of Intravenous Contrast Enhancement in the CT Evaluation of Intraspinial Tumors

J. S. Lapointe, D. A. Graeb, R. A. Nugent and W. D. Robertson

AJNR Am J Neuroradiol 1985, 6 (6) 939-943

<http://www.ajnr.org/content/6/6/939>

This information is current as of May 5, 2024.

Value of Intravenous Contrast Enhancement in the CT Evaluation of Intraspinal Tumors

J. S. Lapointe¹
D. A. Graeb
R. A. Nugent
W. D. Robertson

The usefulness of intravenous contrast-enhanced CT in delineating intraspinal cord tumors has not been well documented. To determine if intradural spinal tumors enhance, if the location and type of tumor can be determined, and if a double dose of contrast material provides more information than a single dose, a retrospective study of 23 patients with proven intradural extramedullary or intramedullary tumors was performed. All the tumors studied with CT after intravenous contrast enhancement showed that most lesions (18/23) enhanced, contrary to published reports. Contrast-enhanced studies delineated the extent of the tumor, helping to separate solid and cystic components. The enhancement pattern of ependymomas and astrocytomas was similar, while schwannomas had a characteristic appearance. A double dose of intravenous contrast material had no apparent advantage over a single dose.

Intravenous iodinated contrast material has been used to enhance intracranial lesions since the early days of CT scanning. Isolated reports of contrast enhancement of intraspinal lesions were published when body scanning first became available [1, 2]. Subsequently, little attention has been paid to delineation of intramedullary spinal cord lesions with intravenous contrast material, because it is believed that little or no enhancement occurs in these lesions, although enhancement of intradural extramedullary lesions has been documented [3, 4]. The aims of our retrospective study were threefold: (1) to determine how often intradural spinal tumors enhance; (2) to determine if an intravenously enhanced CT scan adds useful information concerning the location of the tumor and the type of tumor; and (3) to determine if a double dose of intravenous contrast material provides more information than a single dose.

Materials and Methods

The myelograms, metrizamide-enhanced CT scans, and the intravenously enhanced CT scans of 23 patients with proven spinal intradural mass lesions, either intramedullary or extramedullary, were reviewed retrospectively. Nineteen myelograms and 18 metrizamide CT scans were available. In all patients, CT was performed after intravenous administration of contrast material, and in two patients this was the only examination.

Eleven of the 23 patients had noncontrast studies. Eight patients received a single dose of contrast material (42 g I as 300 ml of iohalamate meglumine 30%) by drip infusion, while 15 patients received a double dose (84 g I as 300 ml of iohalamate meglumine 60%). Contrast material was dripped as rapidly as possible, usually over a 15 min period, and scanning was initiated toward the end of the infusion or immediately after it was completed.

All CT scans were obtained with a General Electric 8800 or 9800 scanner. Slice thickness was 5 mm, and, while slices were contiguous in most cases, slices were spaced every 10–30 mm in patients with intramedullary lesions, extending from the cervical to the lumbar region.

The location and length of the intraspinal mass was determined on the myelogram or metrizamide CT scan. The height of one vertebral body was taken to correspond to one involved segment of spinal cord. The number of segments involved on the myelogram or

This article appears in the November/December 1985 issue of *AJNR* and the January 1985 issue of *AJR*.

Received December 28, 1984; accepted after revision April 9, 1985.

¹ All authors: Department of Radiology, University of British Columbia, and Vancouver General Hospital, 855 W. 12th Ave., Vancouver, British Columbia, Canada V5Z 1M9. Address reprint requests to J. S. Lapointe.

AJNR 6:939–943, November/December 1985
0195–6108/85/0606–0939

© American Roentgen Ray Society

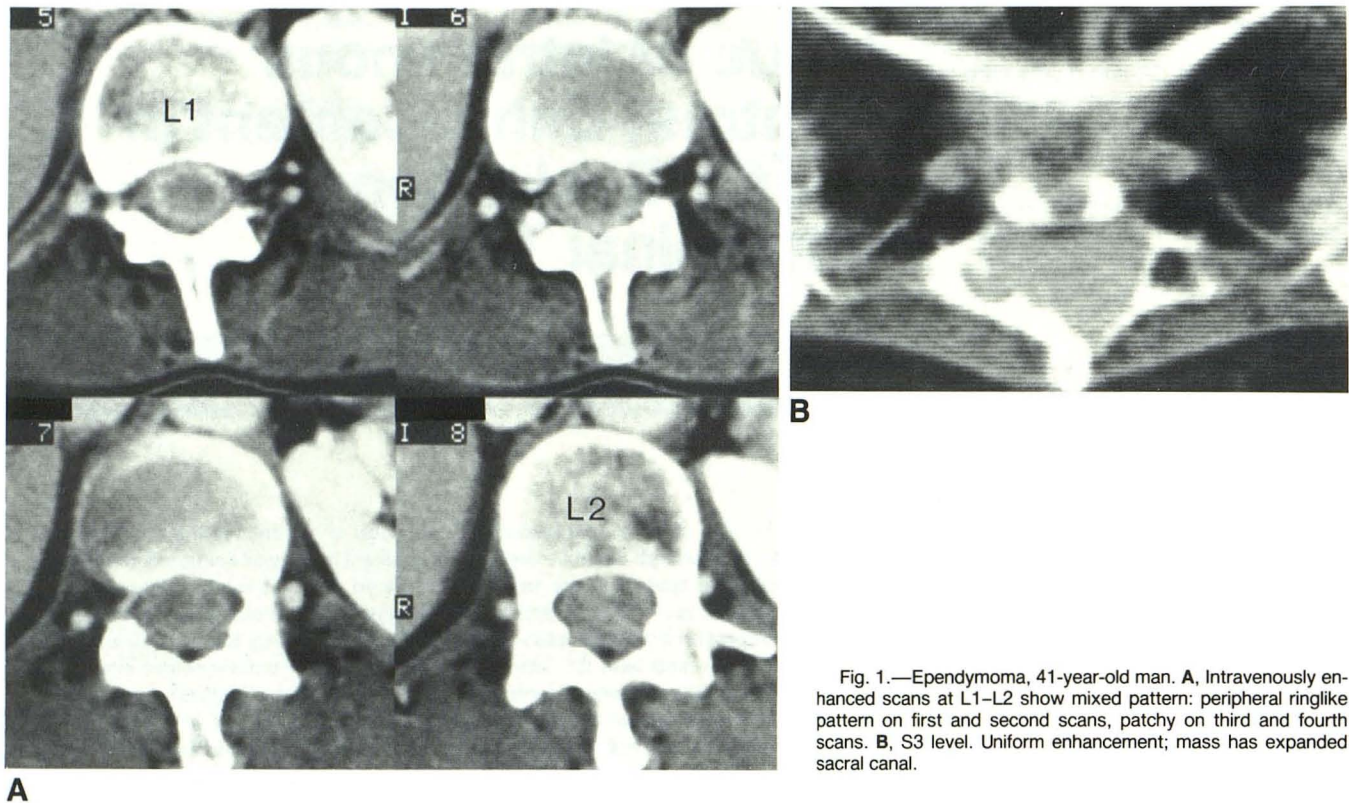


Fig. 1.—Ependymoma, 41-year-old man. **A**, Intravenously enhanced scans at L1–L2 show mixed pattern: peripheral ringlike pattern on first and second scans, patchy on third and fourth scans. **B**, S3 level. Uniform enhancement; mass has expanded sacral canal.

metrizamide-enhanced CT scan was compared with the number of enhancing segments seen on the intravenously enhanced scan.

The patterns of enhancement of the intramedullary and extramedullary lesions were evaluated separately to see if certain features could help in predicting histology. A search for areas of decreased attenuation, definite cerebrospinal fluid (CSF) density, and solid enhancing nodules was made. Cysts were diagnosed radiologically if the lesion was of CSF density or if it filled with metrizamide. Areas of low attenuation were considered cystic when a fluid-filled cavity was encountered at surgery or autopsy. Isodense lesions were similar to spinal cord density on unenhanced or intravenously enhanced scans.

Enhancement of the lesions was classified as mild, moderate, or marked, as Hounsfield measurements were not available in all cases. Correlation with the amount of contrast material administered was then made.

The histology of the lesions was confirmed at surgery or autopsy in all cases, except for a cervicomedullary junction intramedullary mass that was explored but not biopsied.

Results

Lesions were found in 16 males and seven females between the ages of 10 months and 68 years. Fifteen patients (13 males and two females) were young adults between the ages of 16 and 36. Fourteen intramedullary lesions and nine intradural extramedullary lesions were diagnosed. Lesions affecting all parts of the spinal cord were demonstrated, but they predominated in the cervical region (eight cervical, three cervicomedullary, four thoracic, four thoracolumbar, three lum-

bosacral, one cervical to lumbar). The results in the intra- and extramedullary lesions are tabulated separately.

Intramedullary Lesions

Eleven gliomas, one metastasis, one ependymal cyst of the conus, and one intramedullary lipoma were found. Eight of 11 gliomas and the intramedullary metastasis enhanced moderately to markedly (fig. 1). Two gliomas enhanced mildly and one did not enhance (fig. 2). The intramedullary lipoma was of fat density and the ependymal cyst of the conus was of CSF density; neither enhanced. Unenhanced scans were available in seven of 14 intramedullary tumors, with a variety of densities found within tumors of similar histologies. Only one of four ependymomas was hypodense before enhancement. All ependymomas and astrocytomas were of low grade, histologically.

Intravenously enhanced CT scans helped to localize the solid component of the intramedullary mass in 11 of 14 cases. Of the 11 enhancing lesions, five tumors were of the same length on the myelogram and on the intravenously enhanced CT scan, and five lesions were shorter on CT than on the myelogram. Four of these five lesions had a cyst or area of low density adjacent to the enhancing part of the tumor. In one case, the intravenously enhanced CT scan demonstrated extension of the mass (an ependymoma) into the sacral canal to the level of S3 (fig. 1). This had not been seen on the

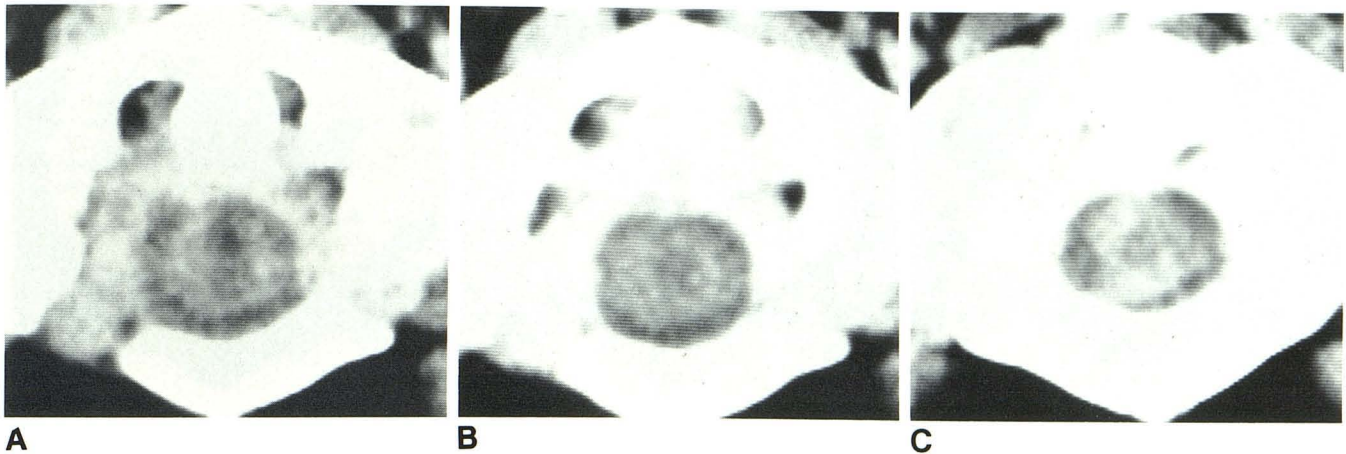


Fig. 2.—Astrocytoma, 47-year-old man. **A**, Unenhanced scan at C1–C2 level. Slightly hyperdense cord with central cyst (narrow window and level settings). Contrast-enhanced scans at C1 (**B**) and C2 (**C**) show cyst to better advantage and mild enhancement of tumor (same settings).

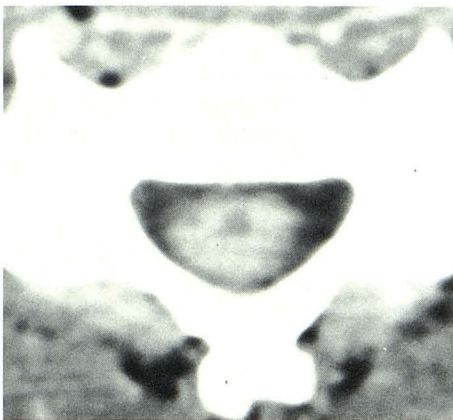


Fig. 3.—Astrocytoma, 26-year-old man. Dense enhancement of cord at C5 level with small midline lucency, which probably represents part of cyst, above and below solid nodule. Cyst contained clear oily fluid, and parts of cyst above and below solid nodule were not demonstrated on delayed metrizamide or intravenously enhanced scans.

myelogram because the dural sac ended at the L5–S1 disk space.

The average length of enhancing cord was three vertebral segments, with two patients having enhancing lesions over eight and 11 segments, respectively. Two other patients had a widened cord from C2 to T11 and T2 to L3, respectively. Both had extensive cysts associated with a short enhancing portion. The first patient's solid nodule was at the C4–C6 level with the cyst proximal and distal to it. The cyst, which contained clear oily fluid, was not seen on metrizamide- or intravenously enhanced CT scans, but was demonstrated at surgery using sonography and was shunted at the T8 level (fig. 3). In the second patient, metrizamide had filled the cyst between T2 and T9, with no cyst evident between T10 and

L3. With intravenous contrast material administered at the same time, moderate enhancement at the L1 and L2 levels was found. At surgery, this tumor extended from T10 to L3–L4 (fig. 4).

The histology, the amount of contrast material, and the degree of enhancement of the 14 intramedullary mass lesions are summarized in table 1. Predicting tumor histology by its appearance was not rewarding. Both ependymomas and astrocytomas demonstrated solid, patchy, or ringlike enhancement with cysts or areas of low attenuation (figs. 1–3).

Intradural, Extradural Lesions

The results of the nine intradural extradural masses are also summarized in table 1. Four schwannomas and one each of meningioma, hemangioblastoma, hemangiopericytoma, lymphosarcoma, and tonsillar cyst were discovered. Five masses enhanced markedly, two only mildly, and two did not enhance. The nonenhancing lesions were the tonsillar cyst (of CSF density) and one small (1 cm) schwannoma.

Only four unenhanced scans were obtained. The meningioma contained punctate calcifications, a large isodense schwannoma had areas of decreased attenuation, and the hemangioblastoma and the hemangiopericytoma (in patients with von Hippel-Lindau disease) were isodense.

In all cases, the area of enhancement corresponded with the location of the mass on myelography. The meningioma, the hemangioblastoma, and one schwannoma enhanced in a dense uniform fashion. Two schwannomas and the lymphosarcoma had patchy, irregular enhancement with areas of low density, and mild uniform enhancement of the hemangiopericytoma was seen.

The degree of extraspinal extension was better appreciated on the intravenously enhanced scan than on the myelogram in two schwannomas (fig. 5). The other lesions had no extradural extension.

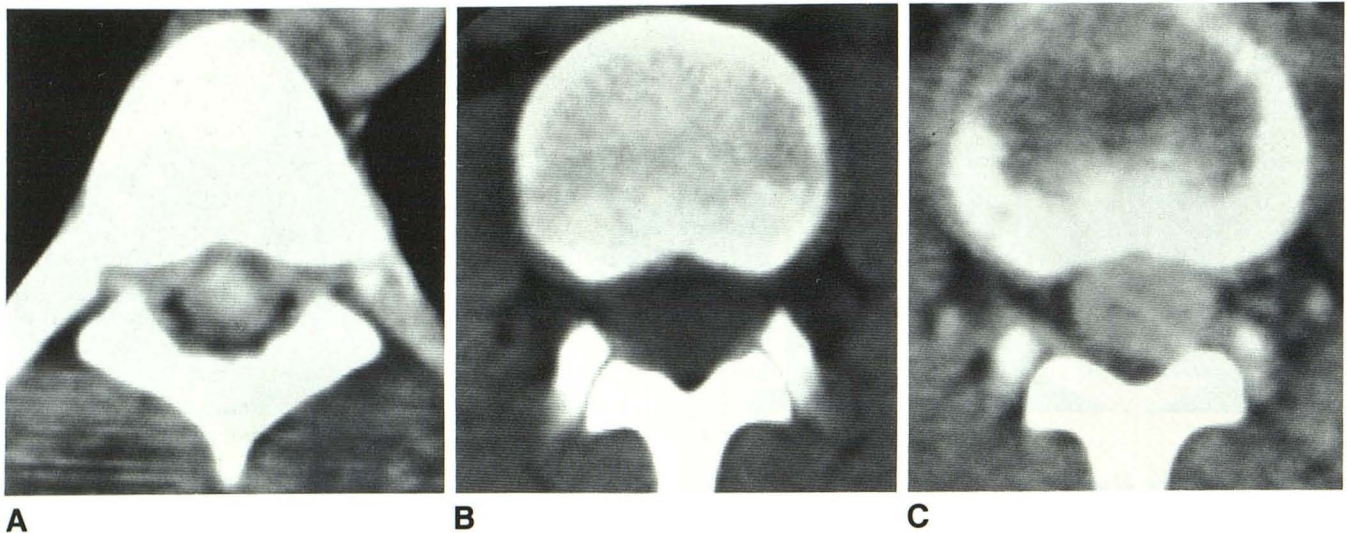


Fig. 4.—Ependymoma, 16-year-old boy. A, Unenhanced scan 20 hr after metrizamide myelogram. Dense collection of metrizamide in tumor cyst at T6 level. B, L1–L2 level. No cyst is seen. C, Same level immediately after B and administration of intravenous contrast material. Moderate enhancement of solid tumor nodule, which occupies cord at this level.

TABLE 1: CT Characteristics of Intradural Masses

| Histology | No. of Tumors | | | | |
|-----------------------------------|---------------|----------|-----------|--|--------|
| | Total | Isodense | Enhancing | Degree of Enhancement | Cystic |
| Intramedullary: | | | | | |
| Ependymoma | 6 | 2 | 6 | Moderate to marked: 2 SD, 3 DD; mild: 1 SD | 4 |
| Astrocytoma | 4 | 1 | 3 | Marked: 1 SD, 1 DD; mild: 1 SD; none: 1 DD | 2 |
| Glioma (unknown type) | 1 | ... | 1 | Marked: DD | 1 |
| Metastasis (lung) | 1 | 1 | 1 | Marked: SD | 0 |
| Lipoma | 1 | ... | 0 | None: DD | FD |
| Ependymal cyst of conus | 1 | ... | 0 | None: DD | 1 |
| Extramedullary: | | | | | |
| Schwannoma | 4 | 1 | 3 | Marked: 2 DD; mild: 1 DD; none: 1 DD | 1 |
| Hemangioblastoma | 1 | 1 | 1 | Marked: SD | 0 |
| Hemangioendothelioma | 1 | 1 | 1 | Mild: DD | 0 |
| Meningioma* | 1 | 0 | 1 | Marked: DD | 0 |
| Lymphosarcoma | 1 | ... | 1 | Marked: SD | 0 |
| Tonsillar cyst | 1 | ... | 0 | None: DD | 1 |

Note.—Isodensity was evaluated on unenhanced scans only, which were not obtained in all cases. Cystic findings were evaluated on either unenhanced or enhanced scans. SD = single dose; DD = double dose; FD = fat density.
* Calcification present.

Single versus Double Doses of Contrast Material

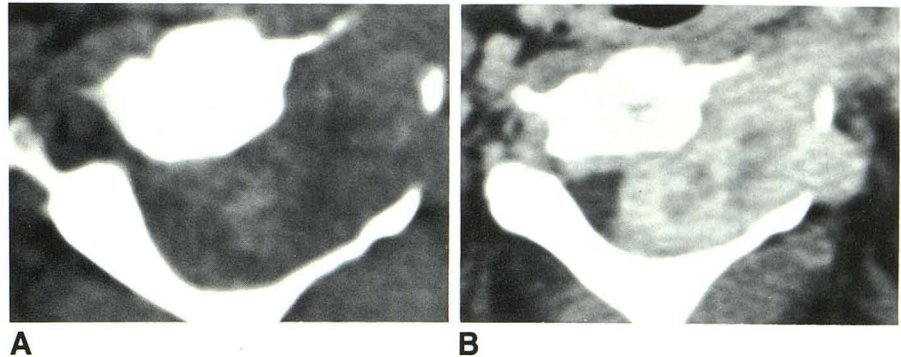
Enhancement ranging from mild to marked was present in 18 of 23 lesions. The two cysts and the lipoma were not expected to enhance. However, one astrocytoma and one schwannoma did not enhance. Both patients had received a double dose of contrast material. Of the four lesions that enhanced mildly (see table 1), two patients had received a single dose and two patients a double dose of contrast material. Fourteen masses enhanced moderately to markedly. Six of these patients had received a single dose and eight a double dose.

Discussion

The spinal cord is difficult to image without the use of intrathecal contrast material [1]. While absorption of metrizamide by the cord may increase attenuation values by about 30 H, intravenous administration of contrast material results in an increase of about 10 H [5].

Previous reports of intravenous contrast enhancement of intramedullary tumors showed disappointing results, with only one of six ependymomas and one of five astrocytomas actually enhancing [1, 3, 6]. Cystic degeneration, known to occur in almost one-half of ependymomas and in more than

Fig. 5.—Schwannoma, 30-year-old woman. **A**, Unenhanced scan at C2 level. Large mass of mixed density within spinal canal, expanding left intervertebral foramen and extending into paravertebral soft tissues. **B**, Contrast-enhanced scan at same level. Marked tumor enhancement with central lucent defects. Extension of tumor outside foramen and canal and marked displacement of spinal cord to right are better appreciated.



one-third of spinal cord astrocytomas, appeared as hypodense areas in one astrocytoma and in two ependymomas [3, 6–8]. Fifteen of 17 schwannomas enhanced [1, 2, 6], while six intramedullary lipomas were of fat density and did not enhance [1, 6].

Only intramedullary hemangioblastomas have shown consistent enhancement, presumably because of their very vascular nature. One hemangioblastoma was hyperdense and two of three hemangioblastomas enhanced densely. Our two patients with von Hippel-Lindau disease had small extramedullary lesions measuring about 1 cm; one of them enhanced mildly and the other markedly. Four of five meningiomas also enhanced [1, 6].

Table 1 summarizes the CT characteristics of the tumors in this series. The findings on unenhanced scans are similar to published reports. However, our study shows that intramedullary lesions are likely to enhance, contrary to the findings in the literature. This is probably because of the better scanning technique now available with thinner cuts, better resolution, and better localization with scout views.

Predicting the histology of the intramedullary tumors was not rewarding, as the characteristics of ependymoma and astrocytoma were similar. Better imaging techniques and a larger series may prove useful in the future.

Most important is the ability of intravenously enhanced CT to localize intramedullary tumors, as surgical removal is now feasible. Differentiating the solid from the cystic component of the tumor may help to limit the length of the laminectomy. Intraoperative sonography can also be used to localize the mass lesion.

Response to treatment and the presence of residual or recurrent tumors can also be assessed by intravenously enhanced scans, obviating repeat myelography.

A double dose of contrast material did not enhance tumors more densely than did a single dose (table 1).

As predicted by Pettersson and Harwood-Nash [5] in 1982, contrast enhancement of spinal cord tumors has proved valuable. Eighteen of 23 intradural tumors enhanced; enhancement of three of the other five lesions would not be expected. The contrast-enhanced study was useful in delineating the extent of the tumor, especially when a cyst was present, and in helping the surgeon localize the solid tumor before removal. The histology of intramedullary tumors could not be predicted accurately by the enhancement pattern. No advantage of a double dose of contrast material over a single dose was demonstrated in our series, but the study design precludes definite conclusions.

REFERENCES

1. Nakagama H, Huang YP, Malis LI, Wolf BS. Computed tomography of intraspinal and paraspinal neoplasms. *J Comput Assist Tomogr* 1977;1:377–389
2. Balériaux-Waha D, Terwinghe G, Jeanmart L. The value of computed tomography for the diagnosis of hourglass tumors of the spine. *Neuroradiology* 1977;14:31–32
3. Lee BCP, Kazam E, Newman AD. Computed tomography of the spine and spinal cord. *Radiology* 1978;128:95–102
4. Houghton VM, Williams AL. *Computed tomography of the spine*. St. Louis: Mosby, 1982
5. Pettersson H, Harwood-Nash DCF. *CT and myelography of the spine and cord—techniques, anatomy and pathology in children*. New York: Springer-Verlag, 1982
6. Aubin ML, Jardin C, Bar D, Vignaud J. Computerized tomography of 32 cases of intraspinal tumor. *J Neuroradiol* 1979;6:81–92
7. Handel S, Grossman R, Sarwar M. Computed tomography in the diagnosis of spinal cord astrocytoma. Case report. *J Comput Assist Tomogr* 1978;2:226–228
8. Dorwart RH, LaMasters DL, Watanabe TJ. Tumors. In: Newton TH, Potts DG, eds. *Modern neuroradiology*, vol 1. *Computed tomography of the spine and spinal cord*. San Anselmo, CA: Clavadel, 1983:115–130