

Are your **MRI contrast agents** cost-effective?

Learn more about generic **Gadolinium-Based Contrast Agents**.



FRESENIUS
KABI

caring for life

AJNR

Spinal myoclonus and clinical worsening after intravenous contrast medium in a patient with spinal arteriovenous malformation.

M Casazza, M Bracchi and F Girotti

AJNR Am J Neuroradiol 1985, 6 (6) 965-966

<http://www.ajnr.org/content/6/6/965.citation>

This information is current as of April 17, 2024.

Spinal Myoclonus and Clinical Worsening after Intravenous Contrast Medium in a Patient with Spinal Arteriovenous Malformation

M. Casazza,¹ M. Bracchi,² and F. Girotti¹

Spinal myoclonus with arteriovenous malformations (AVMs) of the spinal cord after intravenous administration of contrast material is extremely rare. Only one case of spinal myoclonus after intravenous infusion of contrast medium for computed tomography (CT) was found in our literature review [1]. We report a second case of spinal myoclonus and symptoms of a transverse spinal lesion consequent to the intravenous administration of urographic contrast medium in a patient subsequently proven to have an AVM.

Case Report

A 71-year-old man experienced 2 years of gradually increasing burning back pain and weakness of the legs—with consequent difficulty in walking and standing and frequent falls. About 6 months after the initial onset of symptoms, he experienced urinary frequency and hesitancy; these symptoms progressed over 1 year and resulted in incontinence. A permanent vesical catheter was required, and the patient was admitted to a urologic division elsewhere. Rectal exploration excluded any prostate pathology, and 1 month later he underwent urography with infusion of 250 ml of 30% Angiographin (Schering, Berlin). At the end of the infusion, the patient developed rhythmic 3-min clonic jerks, consisting of vigorous extension of both legs and associated with profuse perspiration. At the end of this episode, which lasted about 30 min, the patient had paraplegia and complete loss of superficial sensation, which affected all modalities and extended below the tenth thoracic dermatome. In the next 48 hr, only partial recovery occurred.

Two days after urography, the patient was admitted to our neurologic department. Examination showed a severely paraparetic gait, bilateral ankle clonus, Babinski sign on the right, hyperactive reflexes in the legs, diminished superficial sensation bilaterally below the tenth thoracic dermatome, and impaired vibratory sense in both legs. Cardiologic examination and electrocardiography revealed signs of cardiac failure and a left bundle branch block. Cutaneous discoloration, probably the outcome of thrombophlebitis 2 years before, was evident at the distal third of the left leg. Arterial pulses were regular. The patient had a vesical catheter and a urinary infection.

Shortly after his admission, the patient underwent myelography: lopamidol (Iopamiro 300, Bracco, Milan) was introduced into the subarachnoid lumbar space. At the lower thoracic level (T10–T12),

myelography showed tortuous filling defects over the posterior surface of the cord (fig. 1). Other similar but less tortuous defects were present at the upper thoracic and cervical levels. The spinal cord appeared atrophic, particularly at the thoracic level. The appearance suggested the presence of an extradural posterior angioma of the lower thoracic cord, with intradural venous drainage. A few days later the patient developed atrial fibrillation, and his right leg and foot showed signs of an arterial thromboembolism. Because of his general condition, selective spinal angiography was not performed. Although intensive cardiovascular therapy was administered, 2 days after the thromboembolic episode, the patient died suddenly. Autopsy was refused by relatives.

Discussion

Intravenous administration of contrast agents may produce seizures [2, 3], and this is particularly common in patients with metastatic lesions of the brain. It has been demonstrated that the most commonly used intravenous contrast agents increase brain endothelial cell permeability in relation to contact time, anion concentration, and dose, besides iodine concentration and osmolality [4]. The flow of contrast medium through any parenchymal lesion, with alteration of the blood-brain barrier, may further damage barrier permeability and exert a direct irritative effect [4, 5]. In our patient, the contrast medium injection caused a violent spinal myoclonus that involved both legs.

Various causes of spinal myoclonus have been reported in the literature, and three cases of AVMs with myoclonic symptomatology have been described [1, 6, 7]. The pathophysiology of spinal myoclonus is still uncertain but may be from a disinhibition of spinal interneurons. Experimentally, even water-soluble radiographic contrast agents have been reported to transiently inhibit inhibitory postsynaptic potentials [8]. Kennard (cited in [9]) demonstrated that the disinhibition of spinal interneurons leads to paroxysmal discharges, similar to those recorded in cortical epileptogenic foci.

Uhl et al. [1] reported an analogous case of a patient with AVM who had clonic jerks after intravenous infusion of con-

Received April 9, 1984; accepted after revision November 19, 1984.

¹ Department of Neurology, Istituto Neurologico "C. Besta," Via Celoria 11, 20133 Milan, Italy. Address reprint requests to M. Casazza.

² Department of Neuroradiology, Istituto Neurologico "C. Besta," 20133 Milan, Italy.

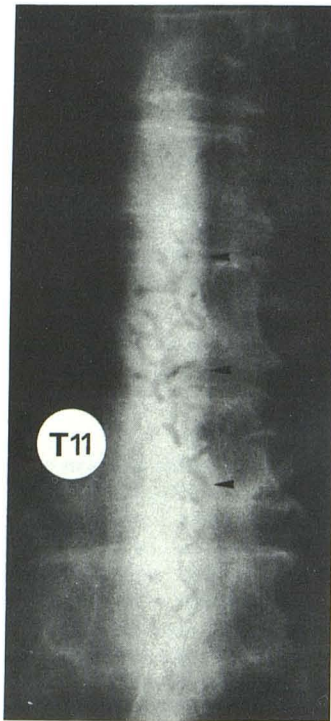


Fig. 1.—Iopamidol myelogram. Tortuous filling defects indicative of spinal AVM at lower thoracic level (arrowheads).

trast medium for a cranial CT scan. Although electrophysiologic recordings were not obtained, the limitation of the involved segments and the complete lack of any alteration in consciousness suggested the presence of spinal myoclonus.

An alteration in the blood-cord barrier at the level of the AVM might be hypothesized, and radiologic intravenous contrast media could exert paroxysmal irritative effects resulting in spinal myoclonus. The worsening of motor and sensory deficits in the legs, which in our patient followed the myoclonic episode, could be induced by a deregulation of intramedullary

circulation. Ischemic hypoxia [10], caused by the increased venous pressure in the shunt, is now thought to be the pathophysiologic basis of the progressive neurologic damage in patients with spinal AVMs. The increase in blood requirements in the peripheral territories resulting from the clonic jerks in our patient could have critically reduced the spinal blood flow [10] and caused the worsening of the motor and sensory defects in the legs. Also, contrast agents [11] may directly produce vascular hypoxia, and the chronic cardiovascular failure in our patient further favored this event.

REFERENCES

1. Uhl GR, Martinez CR, Brooks BR. Spinal seizures following intravenous contrast in a patient with a cord AVM. *Ann Neurol* 1981;10:580-581
2. Lo Zito JC. Convulsions: a complication of contrast enhancement in computerized tomography. *Arch Neurol* 1977;34:649-650
3. Scott WR. A reaction to contrast media for computed tomography of the brain. *Radiology* 1980;137:359-361
4. Junck L, Marshall WH. Neurotoxicity of radiological contrast agents. *Ann Neurol* 1983;13:469-484
5. Fischer HW. Occurrence of seizure during cranial computed tomography. *Radiology* 1980;137:563-564
6. Aminoff MJ, Logue V. Clinical features of spinal vascular malformations. *Brain* 1974;97:197-210
7. Levy R, Plassche W, Riggs J, Shoulson I. Spinal myoclonus related to an arteriovenous malformation. *Arch Neurol* 1983;40:254-255
8. Bryan RN, Johnston D. Epileptogenic effects of radiographic contrast agents: experimental study. *AJNR* 1982;3:117-120
9. Egli M, Bernoulli C, Baumgartner G. Spinal Epilepsie: toxische Anfälle nach zervikalem Spinalis-anterior Syndrom. *Z EEG EMG* 1975;5:87-95
10. Aminoff MJ, Barnard RO, Logue V. The pathophysiology of spinal vascular malformations. *J Neurol Sci* 1974;23:255-263
11. Herrschaft H, Gleim F, Schmidt H. Effects of angiographic contrast media on regional cerebral blood flow and haemodynamics in man. *Neuroradiology* 1974;7:95-103