Spinal Epidural Lymphomas: CT Features in Seven Patients

James Beres[1]
Peter Pech
Thomas F. Berns
David L. Daniels
Alan L. Williams
Victor M. Haughton

The computed tomographic (CT) images and records of seven patients with epidural lymphomas were reviewed to analyze their CT characteristics. Although no single specific pattern was identified, several signs were seen: (1) an intraspinal epidural irregular mass extending over several vertebral levels; (2) a mass with osteolysis or sclerosis; and (3) a combined intra- and extraspinal mass. Lymphoma must be considered in epidural masses when there are associated bone changes.

Metastases (from breast, lung, or prostate), lymphoma, and sarcoma are the most common epidural neoplasms. Although lymphoma constitutes 10%–30% of all spinal malignancies [1, 2], the CT findings of spinal epidural lymphomas have not been described. We reviewed seven cases of spinal epidural lymphoma to determine whether it has a characteristic CT appearance.

Materials and Methods

From the medical records' computer files of three Milwaukee hospitals, patients with epidural lymphoma who had spinal CT between 1980 and 1984 were reviewed. The CT studies had been performed without and/or with intravenous or intrathecal contrast medium on a GE 9800 or 8800 scanner, with axial images 5 mm thick at 5 mm intervals, prospectively targeted and filmed at both bone (1000–2000 H) and soft-tissue (250–500 H) windows. An unmagnified view at each spinal level was also studied to evaluate the paraspinal region. The patients' charts and surgical reports and follow-up evaluations were reviewed. The diagnosis of lymphoma was verified by biopsy of the epidural mass in five cases. In two cases a spinal epidural mass was presumed to be lymphoma because lymphoma was documented by biopsy of an extraspinal site (marrow or lymph node) and by positive response of the epidural mass to radiation therapy.

Results

The patients were 20–87 years old; five were 70 years or older. Of the seven cases studied, four were males. All lymphomas except one were of the non-Hodgkin type. Four of seven lesions involved the lumbosacral region, two involved only the thoracic spine, and one involved only the cervical spine. In three cases no extra-spinal site of lymphomatous involvement was detected at the time of diagnosis.

In each case CT showed a soft-tissue mass in the spinal epidural space with (six cases) or without (one case) an associated paravertebral soft mass (figs. 1–3). All lesions appeared homogeneous in density with CT numbers of 42–100 H. No calcifications and no areas of central necrosis were seen. Five cases had associated osseous changes including compression fractures (one case), erosion (two cases), or sclerosis (two cases) in the adjacent vertebra. In five of the seven cases the epidural mass extended over more than one vertebral segment.

One case had a small focal epidural lesion that was suggestive of herniated L5–

Received April 10, 1985; accepted after revision August 2, 1985.

[1]All authors: Department of Radiology, Medical College of Wisconsin, Froedtert Memorial Lutheran Hospital, 9200 W. Wisconsin Ave., Milwaukee, WI 53226. Address reprint requests to V. M. Haughton.

AJNR 7:327–328, March/April 1986
0195–6108/86/0702–0327

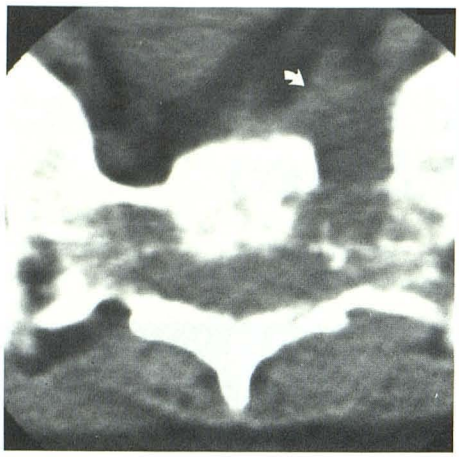

1

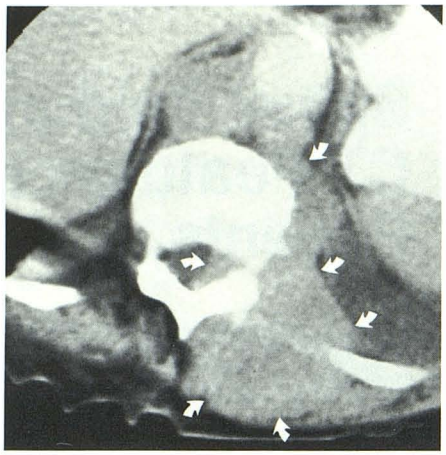

2

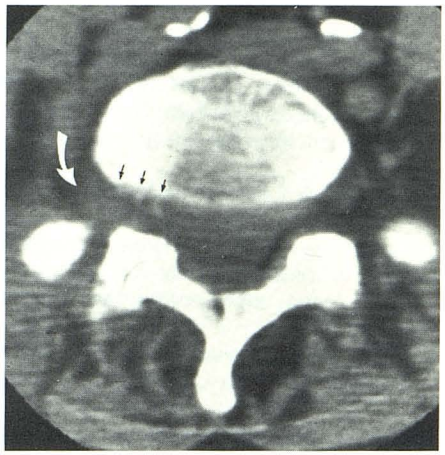

3

Fig. 1.—CT scan through sacrum. Large epidural lymphoma destroying bone and extending into retroperitoneum (*arrow*).

Fig. 2.—Large thoracic lymphoma (*arrows*) with both intra- and extraspinal components.

Fig. 3.—CT scan through L5–S1 intervertebral disk. Lymphoma (*white arrow*) in right intervertebral foramen displacing epidural fat. Osseous erosion and reactive bone changes (*black arrows*) distinguish it from herniated disk.

S1 nucleus pulposus except for subtle sclerosis and erosion of an adjacent vertebral body (fig. 3).

Discussion

The most common CT finding in our series was a paravertebral soft-tissue mass associated with an intraspinal one extending over at least one vertebral segment. These features in combination, or separately, suggest the diagnosis of lymphoma. No characteristic configuration or density of the soft-tissue mass in lymphomas was found.

In one case, epidural lymphoma simulated a laterally herniated nucleus pulposus (fig. 3). An extruded disk fragment may not be easily distinguished from lymphoma without sclerosis or destruction of the adjacent vertebra. Both may have similar densities and cause radicular pain. A location near the L4–L5 or L5–S1 disk and discrete margins suggest disk herniation [3], while indistinct margins and osseous erosion suggest tumor [4]. Differentiation of an anomalous root sheath simulating tumor or disk herniation is facilitated by intrathecally enhanced CT [4].

The radiographic differential diagnosis of a spinal epidural mass is extensive. It includes herniated disk, metastasis, neurofibroma, hematoma, and abscess. Metastases may have bone destruction or sclerosis and be indistinguishable from epidural lymphoma by CT. Neurofibromas may cause pressure erosion of bone and a mass that rarely extends over multiple vertebral segments. Chronic extradural hematomas tend to deform the posterolateral epidural space over multiple vertebral levels, creating a dural sac deformity with smooth margins and tapered ends [5]. Abscess usually presents with a clinical history of pain and fever before osseous changes are evident.

Conventional radiographic studies show osseous involvement in about 30% of spinal epidural lymphomas with either a compression fracture or evidence of erosion [1, 6] and associated paraspinal masses in 6% [1]. The substantially higher frequency of osseous changes and paraspinal masses in our series may be the result of better osseous and soft-tissue detail compared with older CT techniques or conventional radiographs.

In conclusion, although no findings are pathognomonic for spinal epidural lymphoma, lengthy involvement, coexistent bony lesions, and abnormal paravertebral soft tissue were the most common features. When these occur in any combination, spinal epidural lymphoma should be placed high on the radiographic differential diagnosis. Examination of spinal lesions is aided by obtaining soft tissue and bone windows of each CT slice and studying at least one unmagnified view in the region of each disk-space level to observe paravertebral soft tissues.

REFERENCES

1. Rao TV, Narayanaswamy KS, Shankar SK. "Primary" spinal epidural lymphomas. A clinico-pathological study. *Acta Neurochir (Wien)* **1982**;62:307:307–317
2. Gilbert RW, Kim JH, Posner JB. Epidural spinal cord compression from metastatic tumor: diagnosis and treatment. *Ann Neurol* **1978**;3:40–51
3. Williams AL, Haughton VM, Syvertsen A. Computed tomography in the diagnosis of herniated nucleus pulposus. *Radiology* **1980**;135:95–99
4. Williams AL, Haughton VM, Daniels DL, Grogan JP. Differential CT diagnosis of extruded nucleus pulposus. *Radiology* **1983**;148:141–148
5. Levitan LH, Wiens CW. Chronic lumbar extradural hematoma: CT findings. *Radiology* **1983**;148:707–708
6. Haddad P, Thaell JF, et al. Lymphoma of the spinal extradural space. *Cancer* **1976**;38:1862–1866