

Are your **MRI contrast agents** cost-effective?

Learn more about generic **Gadolinium-Based Contrast Agents**.



FRESENIUS
KABI

caring for life

AJNR

Microbubbles as a Contrast Agent for Neurosonography and Ultrasound-Guided Catheter Manipulation: In Vitro Studies

Donald J. Widder and Joseph F. Simeone

AJNR Am J Neuroradiol 1986, 7 (3) 433-438

<http://www.ajnr.org/content/7/3/433>

This information is current as
of April 19, 2024.

Microbubbles as a Contrast Agent for Neurosonography and Ultrasound-Guided Catheter Manipulation: In Vitro Studies

Donald J. Widder^{1,2}
Joseph F. Simeone

Tissue-equivalent ultrasound phantoms, including models of the ventricular system and cyst phantoms, may be useful for developing expertise in both biopsy procedures and shunt catheter placement that use ultrasound guidance. These phantoms have been constructed (1) to assess the ability to position biopsy needles and manipulate shunt catheters with conventional angiographic guidewires and (2) to evaluate the usefulness of microbubbles as an ultrasound contrast agent. Optimal catheter and needle position and catheter patency are demonstrated with microbubbles generated by hand injection of small volumes of saline, a safe ultrasound contrast agent that, to our knowledge, has not been previously exploited in neurosonography. Microbubbles can define biopsy needle location without direct imaging of the biopsy needle; they can also define the extent of communication or separation of fluid-filled or loculated spaces.

Interest in intraoperative transdural or transfontanelle ultrasound-guided biopsy and shunt placement has burgeoned over the past several years. The advantages of ultrasound include the definition of deep lesions without requiring either surface angiographic landmarks or a stereotactic frame and the characterization of the cystic and solid architecture of a lesion. Ultrasound appears to be a valuable tool that can minimize tissue loss during surgical resection, define the extent of resection of a lesion, and image possible intraoperative complications such as hemorrhage [1–3]. Ultrasound-guided ventricular shunt placement minimizes the morbidity associated with misplacement of the shunt and can diminish trauma to the choroid plexus and other intraventricular vascular structures. Preliminary reports indicate that shunt longevity is prolonged with optimal shunt placement by ultrasound guidance as compared with standard surgical placement without ultrasound control [4].

In the setting of an open anterior fontanelle or available dural surface, the brain provides a unique opportunity to exploit sonographic contrast material and interventional techniques that have been used in other organ systems. Because of the relatively uniform sonographic features of the brain, microbubbles that are strongly echogenic are readily visualized when they are generated in the ventricular system or in cystic lesions, and echogenic catheters and wires can be differentiated from normal anatomic structures. Echogenic microbubbles were evaluated in vitro to investigate the feasibility of manipulating ventricular shunt catheters with standard angiographic guidewires and of defining catheter location and patency with an ultrasound contrast agent.

Methods

Images were obtained with an ATL (Advanced Technology Labs) Mark III real-time mechanical sector scanner with 3- and 5-MHz transducers. An ATL biopsy transducer was used. The imaging was recorded on videotape. Additional images were obtained with a matrix multiformat camera during review of the videotape.

This article appears in the May/June 1986 issue of *AJNR* and the August issue of *AJR*.

Received January 29, 1985; accepted after revision September 12, 1985.

Presented in part at the annual meeting of the American Society of Neuroradiology, New Orleans, LA, February 1985.

¹ All authors: Department of Radiology, Massachusetts General Hospital, Fruit St., Boston, MA 02114. Address reprint requests to D. J. Widder.

² Present address: Department of Radiology, Santa Barbara Cottage Hospital, Pueblo at Bath St., Santa Barbara, CA 93102.

AJNR 7:433–438, May/June 1986
0195–6108/86/0703–0433

© American Society of Neuroradiology

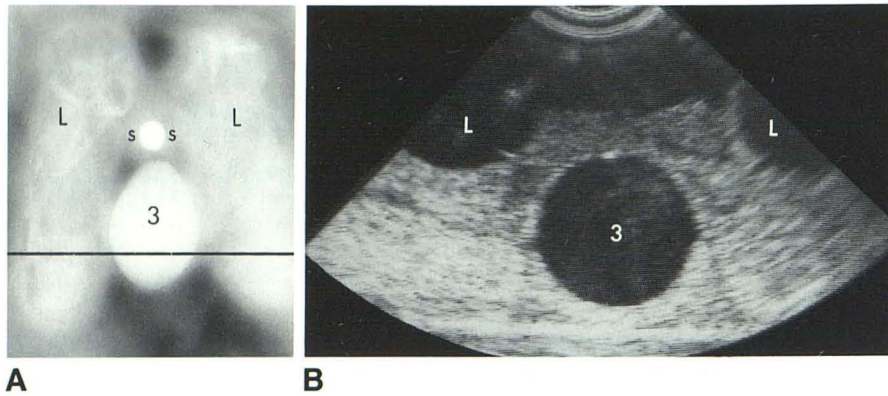


Fig. 1.—A, Anteroposterior radiograph of ventricular phantom filled with dilute contrast media. Black line indicates plane of ultrasound scan (1B). L = lateral ventricle, 3 = third ventricle, S = struts connecting lateral ventricles and third ventricle. B, Coronal sonogram shows dilated lateral and third ventricles. Image plane is posterior to struts connecting lateral and third ventricles.

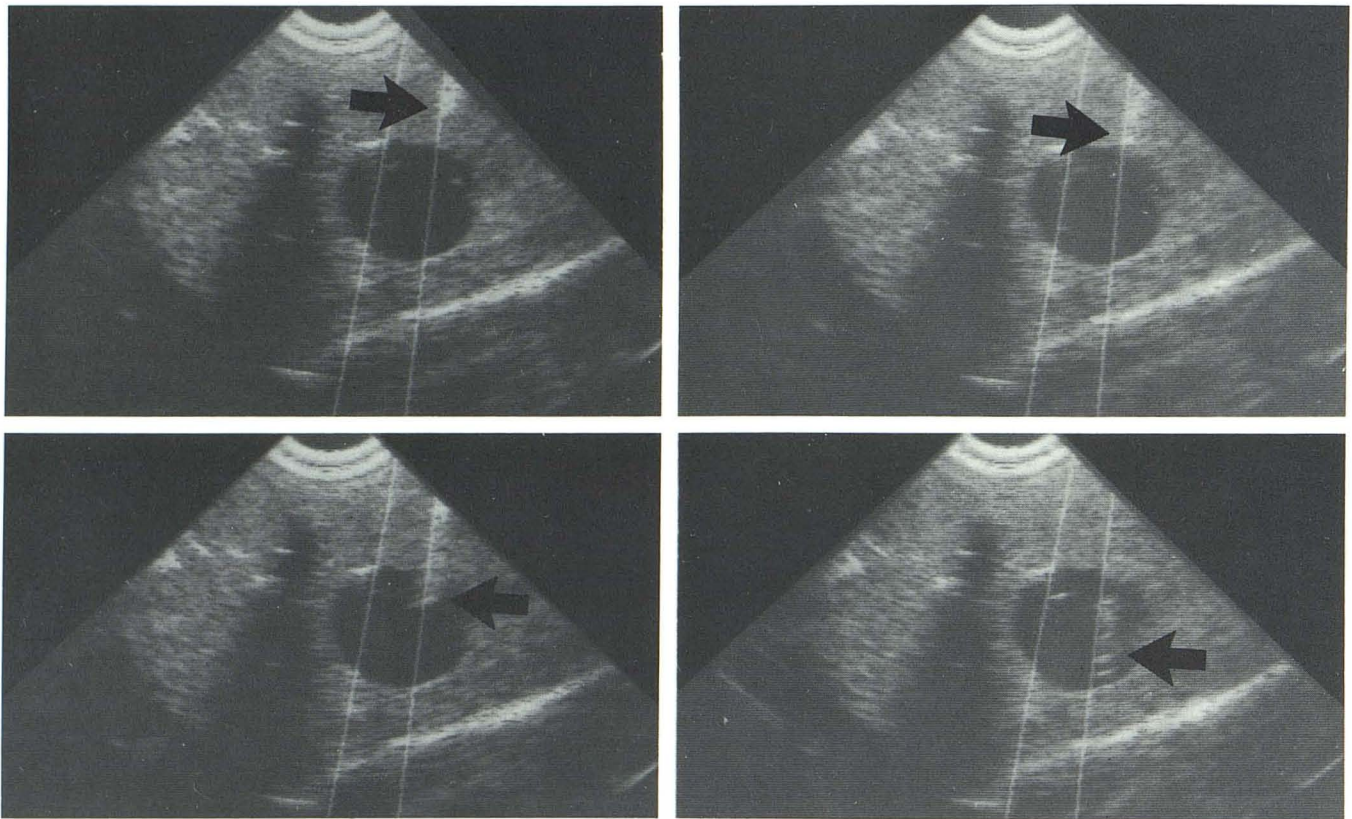


Fig. 2.—Coronal scan. Use of biopsy transducer for placement of ventricular shunt catheter (arrow). Series of images shows gradual passage of catheter

through agar and subsequently into balloon. Mechanical "calipers" (white lines) are generated by biopsy transducer.

Bacto agar, a purified, dehydrated agar preparation, was obtained from Difco Laboratories (Detroit, MI). It dissolves readily in boiling water (50 ml agar/1000 ml water), forming a clear solution, which was allowed to cool and solidify at room temperature. Latex and synthetic rubber balloons of various sizes were filled with 30% water-soluble radiographic contrast material (Renografin 30%; Squibb, Inc., Princeton, NJ). This contrast material allowed us to confirm the location of the balloons through standard radiography, as the solidified agar is visually opaque. Small balloons (less than 1 cm in diameter) were prepared by using the technique of Debrun et al. [5].

In the preparation of the ventricular model, solid cylinders of frozen contrast media were used as conduits to interconnect the balloons before the solidification of the agar. We froze both balloons and cylindrical struts, cut the balloons at the site of attachment, and then

froze the strut to the frozen exposed fluid within the balloon. In this way, the final structure is a communication of fluid-filled spaces encased by agar, resembling the ventricular system (Fig. 1). The balloons and struts were embedded in warm agar that was allowed to gel, so that the layer-by-layer assembly and interconnection needed to form the ventricular model was achieved. The warm agar gel was allowed to harden at room temperature. Since the ultrasound study could be performed only from the superior surface of the phantom, the phantom could be embedded at an obliquity to the surface so that it would more closely approach the intraoperative orientation of the ventricular ultrasound system for shunt placement.

A "cyst phantom" was made by suspending latex balloons, 1 cm in diameter, at depths of 4, 6, and 8 cm in agar gel. An additional phantom was constructed by placing one fluid-filled balloon into

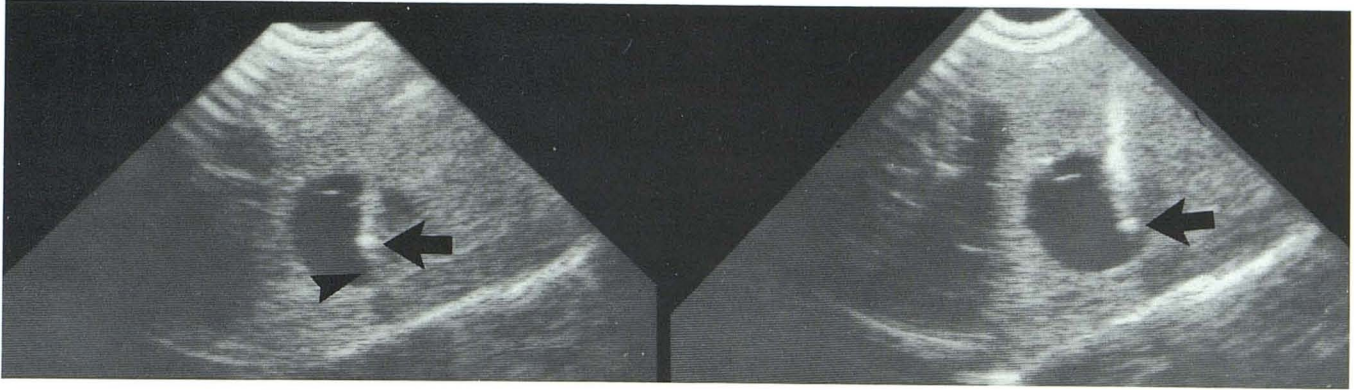


Fig. 3.—Guidewire generates strong echoes that are focused at its tip (*arrow*) and causes an acoustical shadow; guidewire can be differentiated from catheter (*arrowhead*).

another and partially deflating the outer balloon while that balloon is embedded in agar. This created three concentric fluid-filled spaces.

The phantoms were stored in sealed plastic containers and used for 3 weeks without problems of desiccation. Other authors have reported the prevention of desiccation by covering the gel with cellophane wrap. No antibacterial/fungal agents were added to the gel, although such agents may be useful, if long-term use of the phantom is anticipated. Azide preparations are also useful bacteriostatic agents.

Straight Silastic ventricular shunt catheters and Hakim shunts were provided by Cordis Co. (Miami, FL). Standard 19-gauge and 21-gauge spinal needles were used as biopsy needles. A 16-gauge needle was used with coaxial insertion of a 0.032-in. (cm) Newton LLT wire. A 22-gauge needle was used to inject saline or air into the Hakim reservoir chamber for evaluation of microbubbles as a contrast agent.

Findings

Four different phantoms, including two ventricular phantoms, were used. More than 30 passes of a biopsy needle or ventricular catheter with the ATL biopsy probe (Fig. 2) resulted in easy, reliable puncture of the cystic spaces in the various phantoms. We have had previous experience with this technique, but similar needle/catheter procedures are routinely performed by residents and fellows in our institution after a minimal period of training. Several passes with the Silastic catheter and introducer resulted in direct approximation of the catheter on the ventricular system; there was some difficulty with puncturing the soft, elastic walls of the balloon because of the absence of an end hole in the ventricular catheter and its blunted tip. The phantoms tolerated several punctures without considerable disruption of the morphology of the ventricular structures, but after numerous repeated punctures, considerable disruption and decompression of the cystic spaces occurred.

The biopsy transducer was used to position the 25-, 22-, 19-, and 16-gauge biopsy needles. Often only a single pass was required into cysts as small as 1 cm in diameter and 4, 6, and 8 cm deep to the surface. The characteristic "tram track" morphology of the ventricular catheter was easily imaged and differentiated from the strongly echogenic guidewire or metal introducer (Fig. 3). When positioned in the

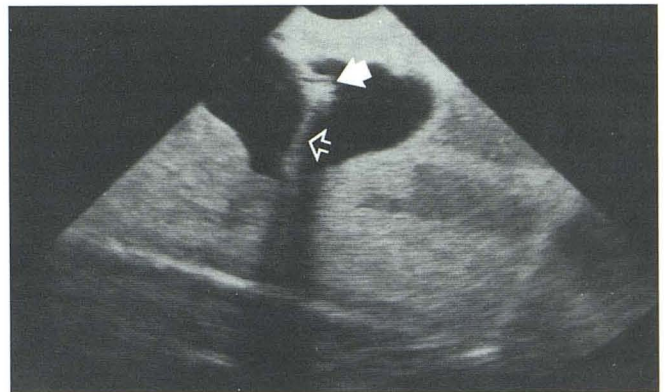


Fig. 4.—A 16-gauge needle (*large arrow*) pierces cyst (lateral ventricle, longitudinal scan) (see Fig. 1) and can be differentiated from guidewire, which is extruded centrally (*open arrow*).

ventricular system, the catheter could be manipulated throughout the ventricular system. This manipulation was aided by the insertion of both the stainless steel introducer and various wires that increased rigidity and control. The course of the echogenic, shadowing wires within the catheter could be visualized and differentiated from the catheter; the tip of the wire within the catheter could be determined by its strongly echogenic character. A tip-deflecting wire allowed for easy deflection of the catheter tip. The direction and extent of deflection, however, were not well controlled, and complex controlled manipulations of the ventricular catheter could not be achieved. When a 16-gauge needle was introduced into the cystic spaces, the morphology of the needle could be differentiated from a coaxially positioned guidewire (guidewires: Newton 0.035-in., 3-mm J, 15-mm J LLT, and 0.035-in. tip-deflecting wire; Cook Co.) (Fig. 4).

Injection of small volumes of saline into the cyst generates echogenic foci (microbubbles) (Fig. 5), which fill in the fluid-filled space. Microbubbles can be differentiated from the spurious echoes caused by reverberation artifact and sub-optimal focusing of the transducer in small deep cystic structures. The extrusion of echogenic material from the side holes of the catheter demonstrates the patency of these side holes.

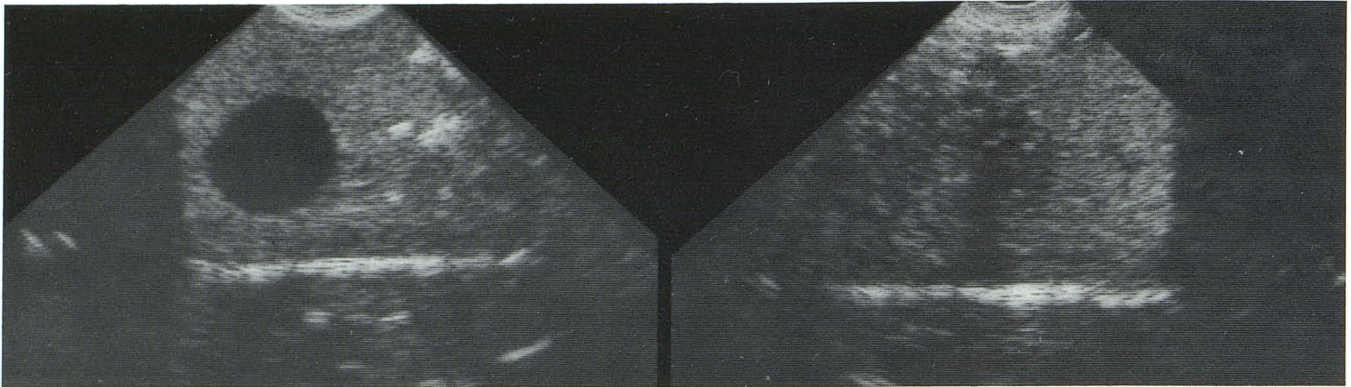


Fig. 5.—Hand injection of small volume of saline generates numerous echogenic foci (microbubbles) that fill in cyst. Injection needle is outside of ultrasound image plane.

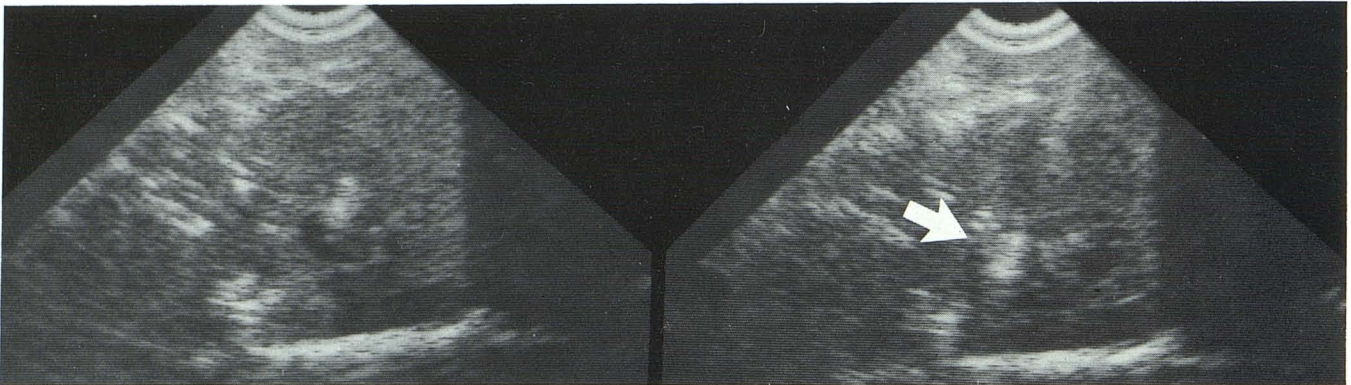


Fig. 6.—Shunt catheter pierces 1-cm "cyst" at a depth of 6 cm. Intracystic position is shown by injection of small amount of saline, which creates micro-

bubbles, the strongly echogenic foci that fill in cyst and collect superiorly (arrow).

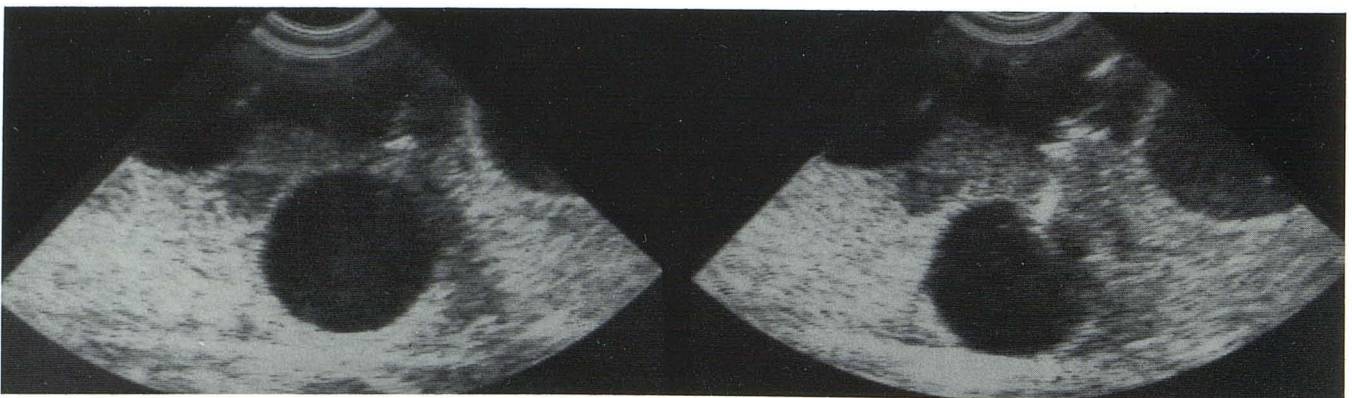


Fig. 7.—Microbubbles extruded along course of catheter show improper placement of shunt catheter outside of model ventricular system (coronal scan).

Intraparenchymal injection of microbubbles in vivo could cause neuronal damage.

Microbubbles are helpful in defining the location of the catheter and biopsy needle as intra- vs extraluminal (Figs. 6 and 7). Microbubbles that are distributed in a fluid-filled space mark the extent of communication of loculations in complex sonographic structures (Figs. 8 and 9). For example, micro-

bubbles clearly demonstrate the separation of three noncommunicating concentric cystic spaces (Fig. 9). In this model, microbubbles help to define the location of a 22-gauge biopsy needle positioned in the cystic structure even when the needle is not directly imaged (Fig. 9).

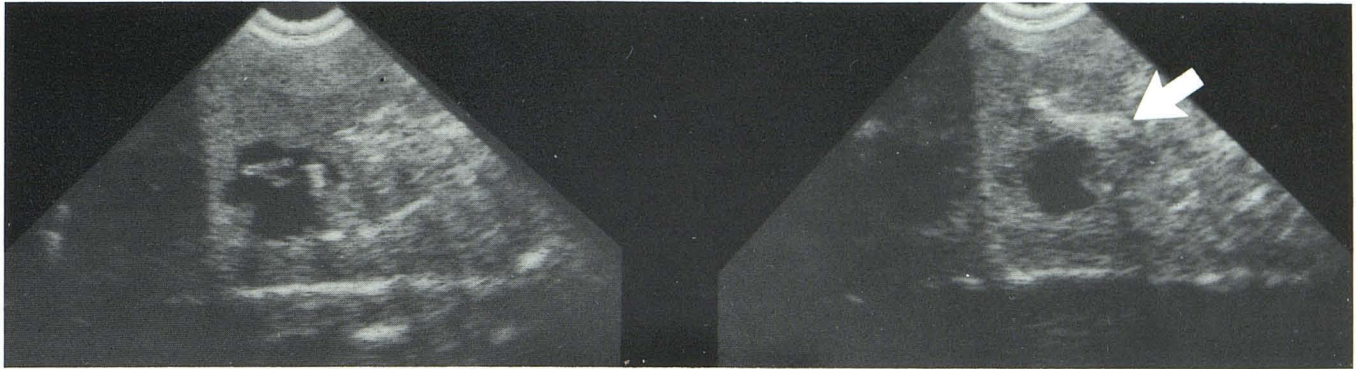


Fig. 8.—A septum was created by a partially deflated balloon. Microbubbles generated in upper aspect of cavity (arrow) show no communication between the two cavities.

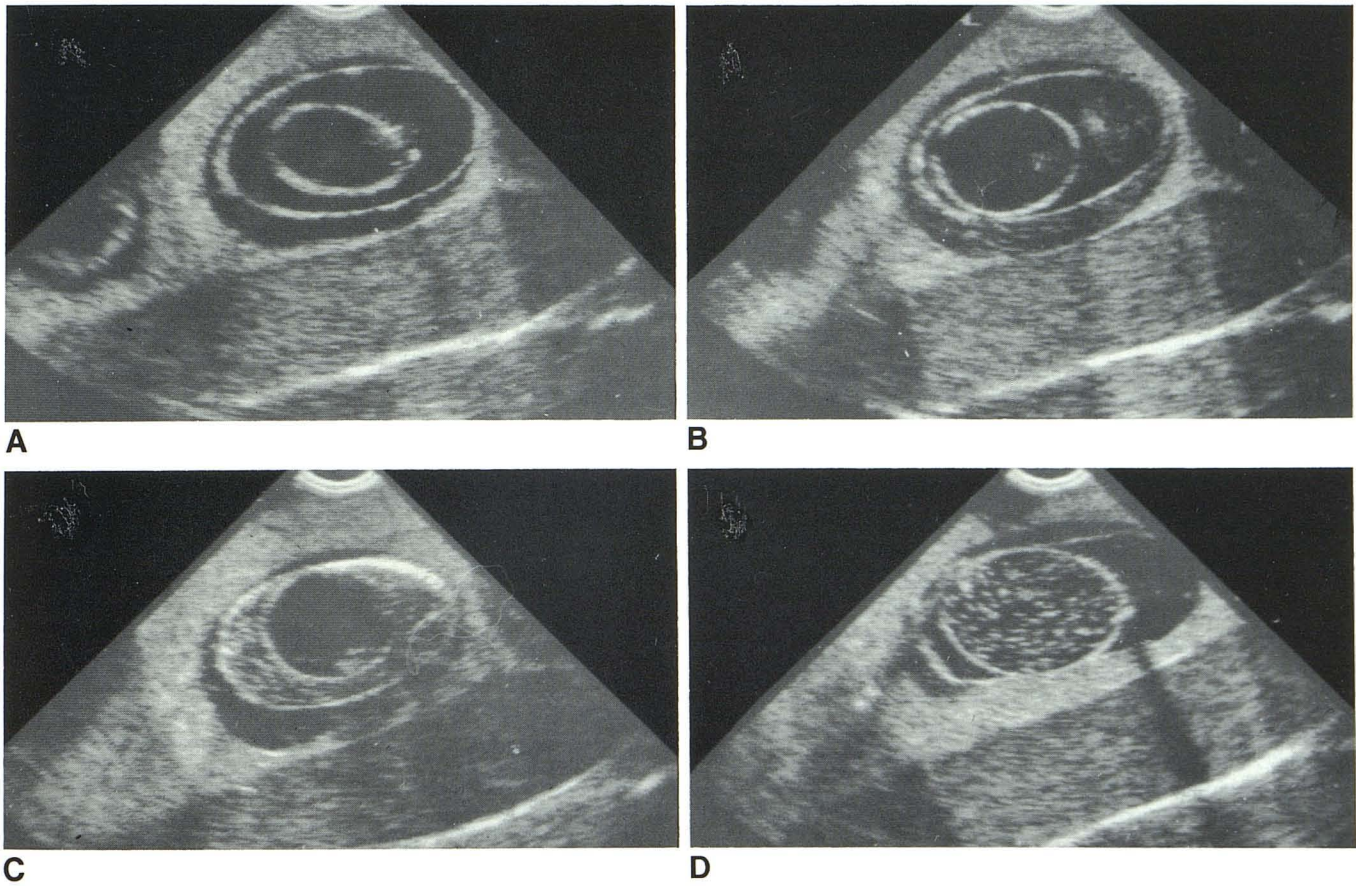


Fig. 9.—A, Phantom composed of three concentric noncommunicating fluid-filled spaces. A 22-gauge needle was advanced into each cyst. Location of needle tip was not well seen directly by ultrasound. Hand injection of saline

defines location of needle in each cystic space and confirms the separation of these spaces (B, C, D).

Discussion

Microbubbles are a well described, clinically useful contrast agent employed in echocardiography [6, 7]. The potential of this agent as a sonographic contrast material for neurosurgical procedures or ultrasound-guided interventional procedures has not previously been described. Microbubbles are

often seen during sonography of vascular structures but are routinely dismissed or misinterpreted as "turbulence" or artifact, or are confused with the low-level echogenicity of mural thrombi. Microbubbles are generated by the cavitation phenomenon, in which pressure changes caused by rapid changes in fluid flow bring solubilized gases transiently out of the solution. The microbubbles create echogenic scatter be-

cause of refractive gas/fluid interfaces that resolve as the bubbles return into solution. Evidence for the existence of microbubbles includes the absence of sonographic echoes and microbubbles when degassed solutions are used. When generated by the force of hand injection, microbubbles measure 10–100 μm as seen by light microscopy and persist for approximately 120 sec. Mechanical ultrasonication creates 5–10 μm microbubbles, which persist longer than those created by hand injection [8].

We believe that microbubbles may prove useful in ultrasound-guided procedures. Microbubbles may define the location of the catheter or needle tip during its placement in small, loculated, or sonographic "complex" structures, including the ventricular system, a syrinx cavity, or a cavitary lesion. Because microbubbles can demonstrate patency of shunt catheters, they may prove helpful in demonstrating optimal catheter position and patency in complicated ventricular shunt placement, such as the nondilated ventricular system (slit ventricles, trapped fourth ventricle) or cases of ventriculitis with intraventricular synechia and loculations. Microbubbles can help to define the location of biopsy needles in fluid-filled structures even if the needle is not visualized. They may be helpful in defining the biopsy site in a sonographically complex or loculated structure so that adequate and representative tissue or fluid samples are obtained. Although microbubbles can define the extraluminal location of a catheter, use of microbubbles in brain parenchyma or solid lesions is not advised because trauma to or transection of neuronal tracts can result. Clinical evaluation of the potential role of microbubbles as a neurosonographic contrast agent is being undertaken.

Two common, important problems in catheter manipulation (whether intravascular, intrabiliary, or intraventricular) are maintaining adequate control of the location of the catheter and demonstrating adequately the position of the catheter. The results of this study confirm the ease of biopsy and catheter positioning with the aid of a biopsy transducer in small deep structures. We were able to make simple maneuvers with the catheter within the phantom, but complicated well-controlled manipulations were not achieved. Guidewires that were strongly echogenic were easily imaged and could be differentiated from the catheter, which is less echogenic. Because they enhance the contrast of the catheter as compared with adjacent structures, wires may be helpful in localizing catheter position. The safety of catheter manipulation with wires has yet to be determined. Our preliminary impression, however, is that tip-deflecting wires are dangerous because of poor control of the direction of deflection and "feel" for the visceral wall with this wire. If further refined, shunt manipulations under ultrasound control may preclude complete shunt revision when shunt obstruction is due to its position (i.e., side holes against the choroid plexus or in the foramen of Monro), rather than to the more common occurrence of side-hole occlusion.

"Tissue-equivalent" solid sonographic materials have only recently become available; they propagate sound at a speed and with scattering characteristics similar to that of parenchymal tissues [9, 10]. The use of these phantoms in conducting

pilot studies for interventional procedures and in developing interventional skills has been minimal. A neurosonographic phantom has not been previously reported. The relatively inexpensive, simple preparation of these phantoms as described above vs the considerable commercial expense of phantoms [11, 12] makes their use in intervention desirable.

Our preliminary findings suggest the potential for an expanding role of ultrasonography in interventional radiologic techniques and the potential use of ultrasound contrast agents such as microbubbles in neurosurgical procedures. This study shows that tissue-equivalent phantoms may be helpful in the development and evaluation of these techniques and in neurosonography training.

ACKNOWLEDGMENTS

We are indebted to Cordis Corporation (Miami, FL) for providing ventricular shunt catheters and technical information and for support of this project. We are also grateful to Drs. John Pile-Spellman, Gerard DeBrun, Daniel Kopans, and Mitchell Goodsitt for their advice and assistance. The technical assistance of Jean S. Lamere, R.T., R.D.M.S., and the aid of Ms. Lynda Bessette in the preparation of this manuscript are appreciated.

REFERENCES

1. Gooding GAW, Boggan JE, Bank WO, Beglin B, Edwards MSB. Sonography of the adult brain through surgical defects. *AJNR* **1981**;2:449–452
2. Rubin JM, Dohrmann GJ. Intraoperative neurosurgical ultrasound in the localization and characterization of intracranial masses. *Radiology* **1983**;148:519–522.
3. Rubin JM, Dohrmann GJ. Use of ultrasonically guided probes and catheters in neurosurgery. *Surg Neurol* **1982**;18:143–148
4. Sekhar LN, Moosy J, Guthkelch AN. Malfunctioning ventriculo-peritoneal shunts. *J Neurosurg* **1982**;56:411–416
5. Debrun G, Lacour P, Caron JP, Hurth M, Comoy J, Keravel Y. Detachable balloon and calibrated-leak balloon techniques in the treatment of cerebral vascular lesions. *J Neurosurg* **1978**;49:635–649
6. Pieroni DR, Varghese PJ, Rowe RD. Echocardiography to detect shunt and valvular incompetence in infants and children (abstr). *Circulation* **1973**;47,48(suppl IV):IV–81
7. Valdez-Cruz LM, Sahn DJ. Seminar on contrast two-dimensional echocardiography: applications and new developments. part II. ultrasonic contrast studies for the detection of cardiac shunts. *JACC* **1984**;3(4):978–985
8. Kort A, Kronzon I. Microbubble formation: in vitro and in vivo observations. *JCU* **1982**;10(3):112–120
9. Madsen EL, Zagzebski JA, Banjavic RA, Burlew MM. Further developments in soft-tissue equivalent, gelatin-based materials. Presented at the annual meeting of the American Institute of Ultrasound in Medicine, San Diego, CA, October **1978**
10. Burlew MM, Madsen EL, Zagzebski JA, Banjavic RA, Sum SW. A new ultrasound tissue equivalent material. *Radiology* **1980**;134:515–520
11. Scherzinger AL, Carson PL, Clayman W, Carter W, Johnson ML, Rashbaum C. A tissue-equivalent upper abdominal phantom. *J Ultrasound Med* **1983**;2:455–462
12. Lerski RA, Duggan TC, Christie J. Technical note: a simple tissue-like ultrasound phantom material. *Br J Radiol* **1982**;55:156–157