AJNR

Diagnosis and evaluation of spondylolisthesis and/or spondylolysis on axial CT.

J G Teplick, P A Laffey, A Berman and M E Haskin

AJNR Am J Neuroradiol 1986, 7 (3) 479-491
http://www.ajnr.org/content/7/3/479

This information is current as of October 12, 2024.

Diagnosis and Evaluation of Spondylolisthesis and/or Spondylolysis on Axial CT

J. George Teplick[1]
Patricia A. Laffey[1]
Arnold Berman[2]
Marvin E. Haskin[1]

A critical review was made of the CT findings in 300 patients who underwent axial CT of the lumbar spine in which spondylolysis and/or spondylolisthesis had been diagnosed. Findings indicate that axial CT is superior to conventional radiographs in several areas: (1) for consistent and accurate demonstration of spondylolysis, (2) for disclosing the various changes in the apophyseal joints associated with degenerative and reverse spondylolisthesis, and (3) for uncovering minimal degrees of spondylolisthesis by the presence of a pseudobulging disk in many cases with equivocal or negative radiographs. Axial CT is a highly accurate method for diagnosing and evaluating spondylolysis and all types of spondylolisthesis.

The axial CT findings of spondylolisthesis and spondylolysis have been given relatively scant attention in journal publications [1–3]; most of the information is to be found in recent texts [4–9]. We are convinced that axial CT is the most sensitive and accurate technique for the recognition of spondylolysis. Axial CT can also accurately assess the type and severity (degree) of spondylolisthesis; often, small degrees of slippage that are not clearly recognized on conventional radiographs are apparent on the CT study. In addition, apophyseal joint changes that occur in both degenerative and reverse spondylolisthesis are clearly detected on axial CT. We discuss these changes seen on axial CT in some detail. Clinical discussion and regular radiographic film findings are omitted; excellent data on these subjects are available in numerous reports and texts [10–17]. In our discussions, *CT* refers to axial CT only.

Materials and Methods

We reveiwed the CT records of 460 patients diagnosed as having spondylolisthesis and/or spondylolysis. All CT studies were performed on a GE 8800 scanner. Our technique was identical to the format used to search for a herniated nucleus pulposus: 5 mm slices at 4 mm intervals with a gantry angle to parallel the interspaces. Frequently, the lumbosacral angle prevented paralleling the L5–S1 interspace because of the limited gantry angle of the scanner.

The CT scans consisted of axial views only, as described above. In the exceptional case, in which reformatted sagittal or coronal views were sought, the patient was rescanned using continuous perpendicular slices. Whenever feasible, the CT findings were compared with spinal radiographs and myelograms.

Results

Statistics

The 460 cases showed the following statistical breakdown: spondylolysis without radiographic evidence of spondylolisthesis, 13.4%; all types of spondylolisthesis, 86.6%; spondylolisthesis with spondylolysis, 46.3%; degenerative spondylolisthesis, 35.5%; reverse spondylolisthesis, 3.3%; and postlaminectomy spondylolisthesis, 0.66%.

Received May 16, 1985; accepted after revision September 19, 1985.

[1] Department of Diagnostic Radiology, Hahnemann University, Broad and Vine Sts., Philadelphia, PA 19102. Address reprint requests to J. G. Teplick.

[2] Department of Orthopedic Surgery, Hahnemann University, Philadelphia, PA 19102.

AJNR 7:479–491, May/June 1986
0195–6108/86/0703–0479
© American Society of Neuroradiology

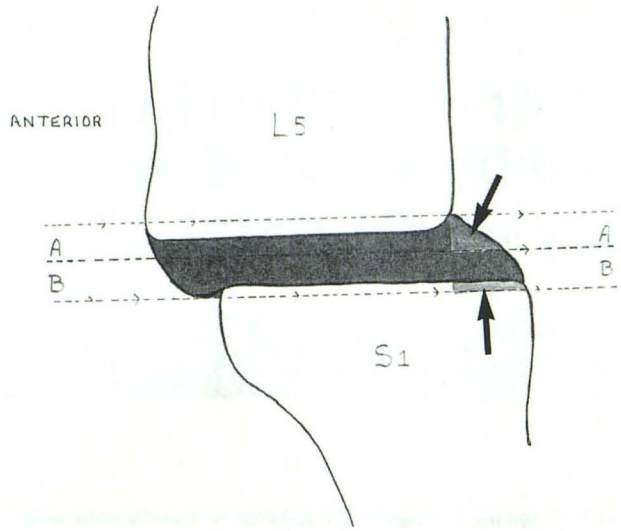

Fig. 1.—Pseudobulging disk and spondolisthesis. Schematic drawing. CT slice A includes inferior edge of L5 and superior portion of anulus. Slice B, next caudal slice, includes inferior portion of anulus and superior margin of S1. Portion of anulus (cartilage) between L5 and S1 (*upper arrow*, *shaded triangle*) will be projected behind L5 cortex; this is pseudobulging disk characteristic of spondylolisthesis. On slice B, cortical bone density of S1 (*lower arrow*, *shaded triangle*) will replace soft-tissue pseudobulging disk.

In toto, the 460 cases represented 3.8% of all our lumbar spine CT studies. These percentages generally agree fairly well with other reported series [8, 12, 13]. However, degenerative spondylolisthesis was considerably more common in our series than in others. Of the 460 cases, 300 were reviewed carefully to determine the spectrum of CT findings in spondylolysis and spondylolisthesis.

Spondylolisthesis

In our series, spondylolisthesis associated with bilateral interarticular defects occurred at L5–S1 in 96%. The rest were at L4–L5, with an occasional rare L3–L4 involvement. This form of spondylolisthesis is found in all adult age groups.

By contrast, 92% of cases of degenerative spondylolisthesis were at L4–L5. The rest were at L5–S1; rarely was L3–L4 the site. In our series, degenerative spondylolisthesis was never seen in individuals younger than 50 years of age.

Spondylolisthesis after bilateral laminectomy and facetectomy without fusion is quite uncommon; slippage may not develop for months or years after the surgery. Without fusion support the partially resected small joints are probably unstable. Only two such cases were encountered from over 1000 postoperative spinal CT scans.

Reverse spondylolisthesis in which the caudad vertebra slips forward is uncommon, but not rare. The facet slippage is usually at L2–L3 or L3–L4. Slippage is rarely greater than 2–3 mm.

The characteristic CT finding of spondylolisthesis is the pseudobulging disk. This term refers to the anulus soft tissue projecting posteriorly into the anterior canal at the level of the anulus. The pseudobulging disk represents the portion of the anulus extending from the posterior edge of the anteriorly displaced vertebral body to the posterior edge of the lower vertebral body. The schematic line drawing of spondylolisthesis at L5–S1 (Fig. 1) clearly shows that on the higher or cephalad cut through the interspace, a portion of the anulus will lie posterior to the superior vertebral body; this soft-tissue projection is the pseudobulging disk. It is also apparent from Figure 1 that on the next caudad slice, the area of the pseudobulging disk will be partially or totally replaced by bone. The actual scans illustrate these points (Fig. 2).

It is also evident that the greater the slippage, the larger the anteroposterior diameter of the pseudobulging disk. With minimal slippage, the pseudobulging disk may be hard to appreciate; however, the presence of a pseudobulging disk on CT indicates some degree of spondylolisthesis, even when slippage is not apparent on radiographs (Fig. 3).

An important characteristic of the pseudobulging disk is its transverse breadth; it virtually always extends into the neural foramina. In addition, its posterior margin is often less regular than an ordinary anulus (Figs. 2 and 4–6).

These CT features should prevent mistaking the pseudobulging disk for an unusually wide herniated disk or for a normal anulus projecting posteriorly on a slice that cannot parallel a steeply angled lumbosacral interspace. In the bulging anulus (often associated with a narrowed interspace), a diffuse bulging throughout its perimeter is apparent, quite different from the pseudobulging disk.

Of course, lateral lumbar radiographs will usually show the spondylolisthesis; however, we have encountered a number of cases with a small pseudobulging disk indicative of first-degree spondylolisthesis that was not clearly evident on the radiographs (Figs. 3 and 4).

The etiology of the characteristic symmetric, wide transverse sweep of the pseudobulging disk invites speculation. In a normal interspace the posterior border of the anulus has a shape that conforms to the shapes of the adjacent posterior vertebral bodies. The sharpness of the posterior rim of the normal anulus on CT is probably related to the posterior longitudinal ligament. When slippage gradually develops, there are no constraints on the more lateral portions of the posterior anulus as it stretches (or grows). Possibly this absence of restraint allows the anulus to grow more laterally, giving the pseudobulging disk its characteristic wide sweep on CT. Irregular fibrocartilaginous growth may explain the less sharp and irregular appearance of some of the pseudobulging disks (Figs. 2 and 4–6). Neither a large herniated nucleus pulposus nor a posterior extending anulus from an angled slice will show this symmetric lateral extension; distinction is not difficult.

Another significant CT finding characteristic of spondylolisthesis is the focal decrease of the anteroposterior diameter of the canal, beginning at the anulus (pseudobulging disk) level and extending caudally for several cuts (Figs. 2 and 5). This focal stenosis has been noted frequently on myelograms and has been considered responsible for symptoms in many patients.

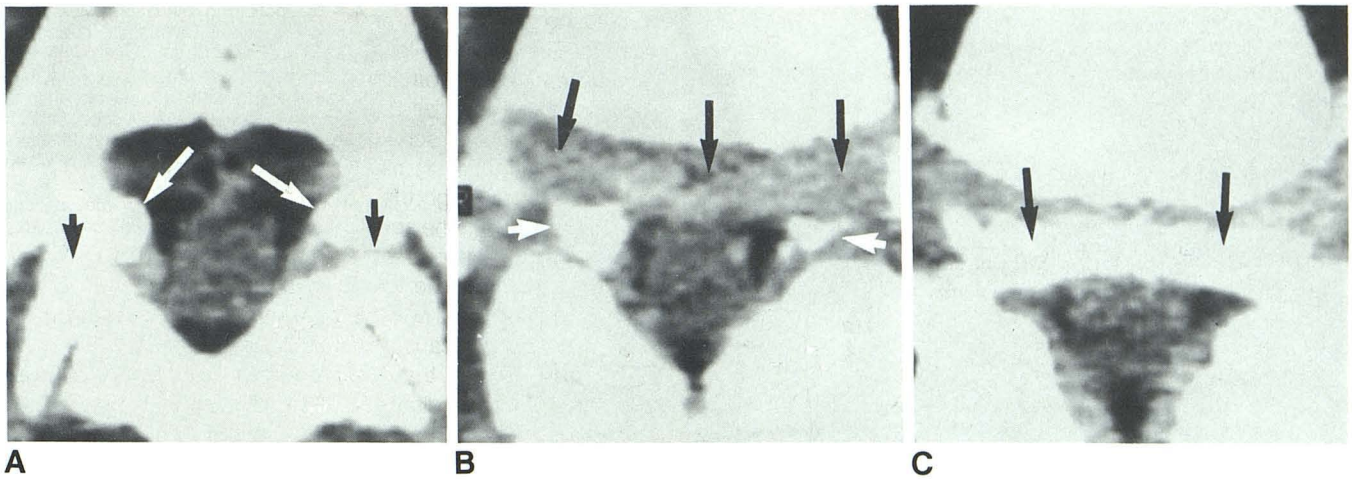

Fig. 2.—Spondylolysis and sponylolisthesis. Successive caudal slices at L5–S1. **A**, AP elongation of canal and thecal sac. Spondylolytic defects (*black arrows*) are barely discernible on these soft-tissue windows. Characteristic medial bone projections (*white arrows*) into canal, anterior to bone defects, are apparent. **B**, Projections appear as "floating" fragments (*white arrows*). Pseudobulging disk (*black arrows*) is characteristically wide and has relatively unsharp posterior margin. **C**, Pseudobulging disk is replaced by bone (*arrows*), which is superior plate of S1.

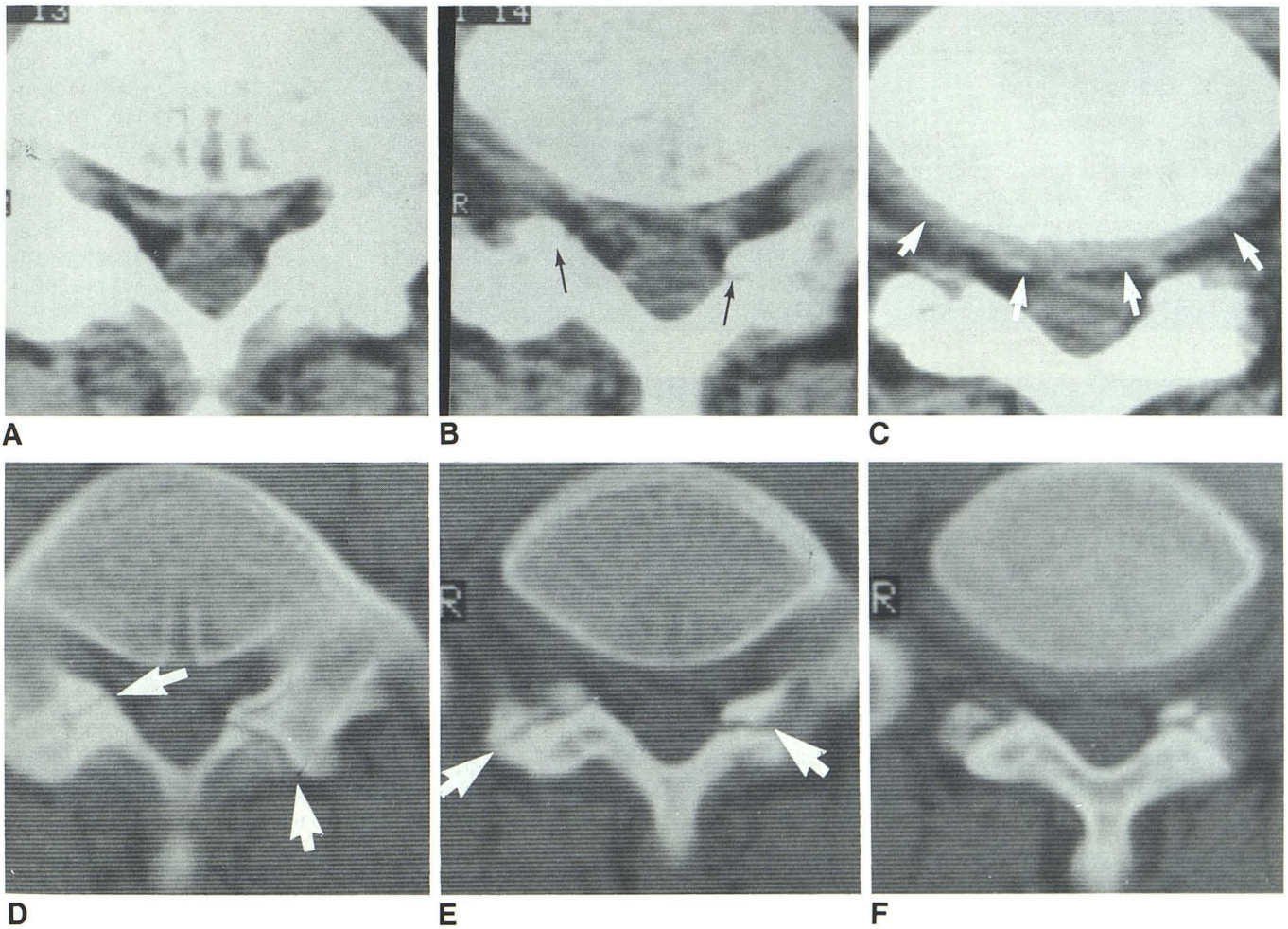

Fig. 3.—Unsuspected spondylolysis and spondylolisthesis in 27-year-old man with recurring low back pain and episodes of radiculopathy and negative radiographic study of lumbar spine. CT was performed to rule out disk herniation. **A–C**, Consecutive soft-tissue windows at L5–S1. Small but characteristic pseudobulging disk (*white arrows*) is indicative of some degree of spondylolisthesis. There was also suspicion of spondylolysis (*black arrows*). **D–F**, Bone windows confirm bilateral spondylolysis (*arrows*). Defects are thin and regular, which may explain difficulty in radiographic detection. CT is superior in detecting spondylolysis and minimal degrees of spondylolisthesis.

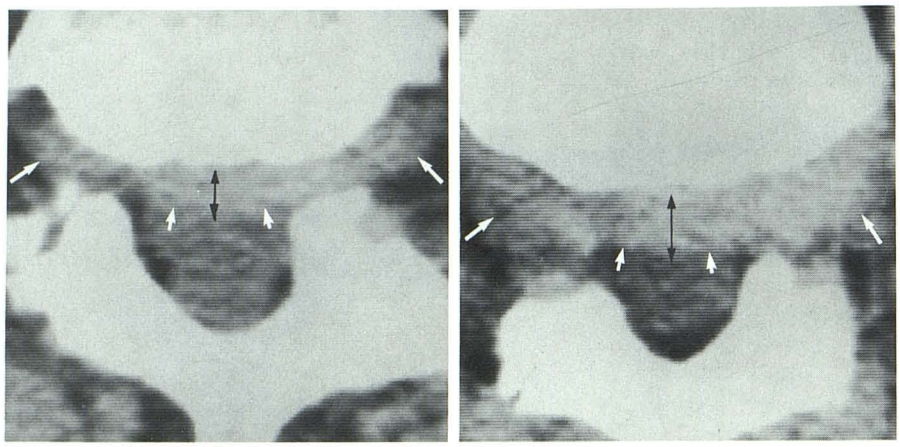

Fig. 4.—Pseudobulging disk in spondylolisthesis in two cases. Magnified views help distinguish pseudobulging disk from bulging anulus: (1) Pseudobulging disk is much broader transversely than ordinary anulus and extends into neural foramina (*long white arrows*). Sometimes pseudobulging disk appears to merge with nerve roots. (2) Posterior margin of pseudobulging disk is often less sharp (*short white arrows*) than ordinary anulus. (3) AP measurement (*black arrows*) is fairly accurate indicator of degree of slippage.

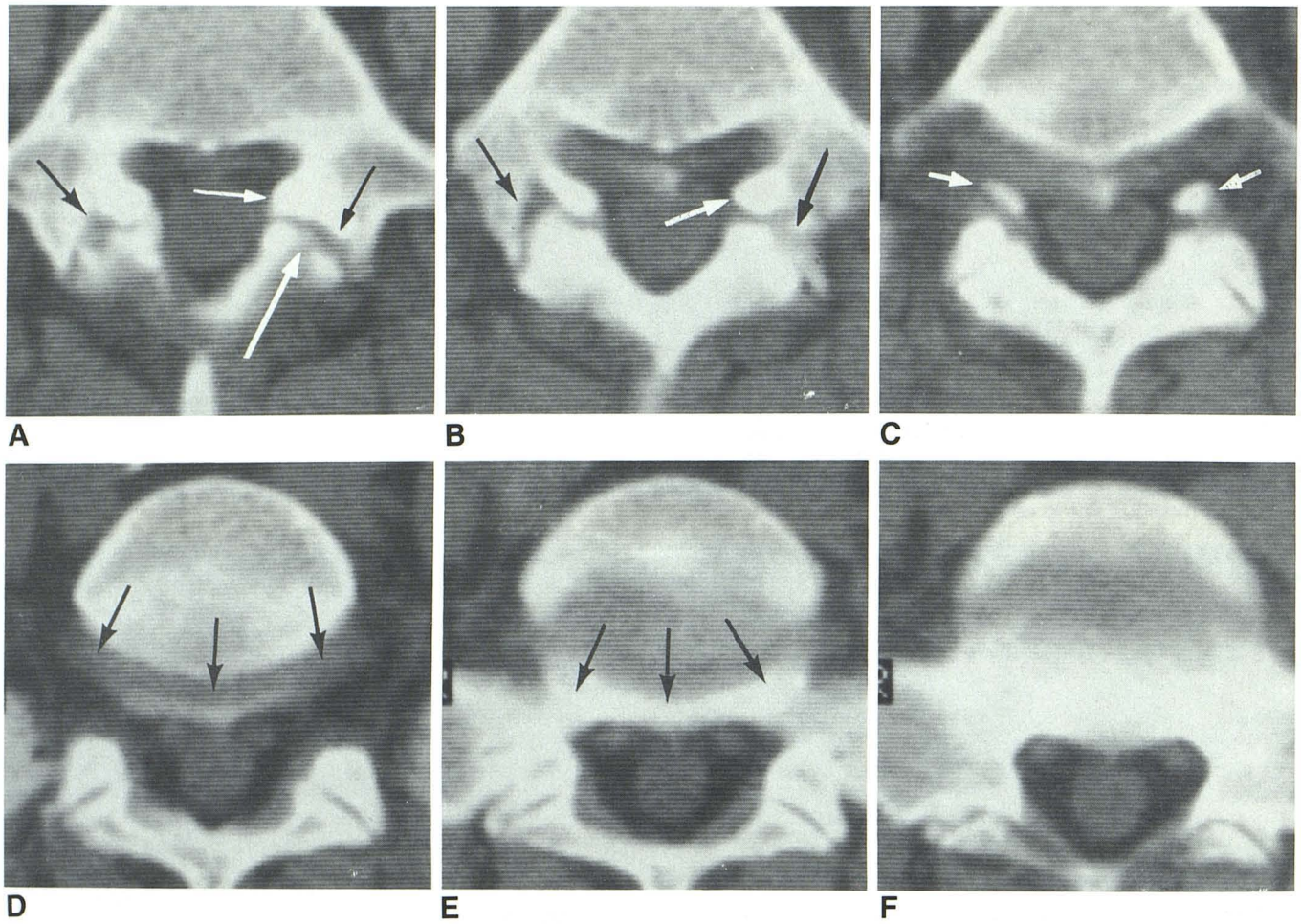

Fig. 5.—CT features of spondylolysis and spondylolisthesis. Six cuts from L5 body to upper S1 body, routine used for study of L5–S1 interspace. Seven significant features are illustrated: (1) Interarticular defects (spondylolysis) (*black arrows*, **A** and **B**) are always seen on slice or two cephalad to slice showing neural foramina (**C**). Most cephalad portions of apophyseal joints are usually also seen in this slice. (2) Spinal canal is usually elongated anteroposteriorly at defect level (**A**). (3) Anterior bone margin of defects often has medial and caudally projecting bony process (*short white arrows*, **A** and **B**). (4) Caudal extension of this process may appear as "floating fragment" on slice showing neural foramina (*arrows*, **C**). (5) Pseudobulging disk (*arrows*, **D**) is replaced on next caudal section by bone (*arrows*, **E**), which is posterior lip of top of S1. (6) Although defect may occasionally closely resemble apophyseal joint, it will have no sharp articular band of sclerosis; low-density marrow may be seen extending into "joint" (defect) (*long white arrow*, **A**). (7) Canal's AP diameter decreases abruptly at level of pseudobulging disk (**D**).

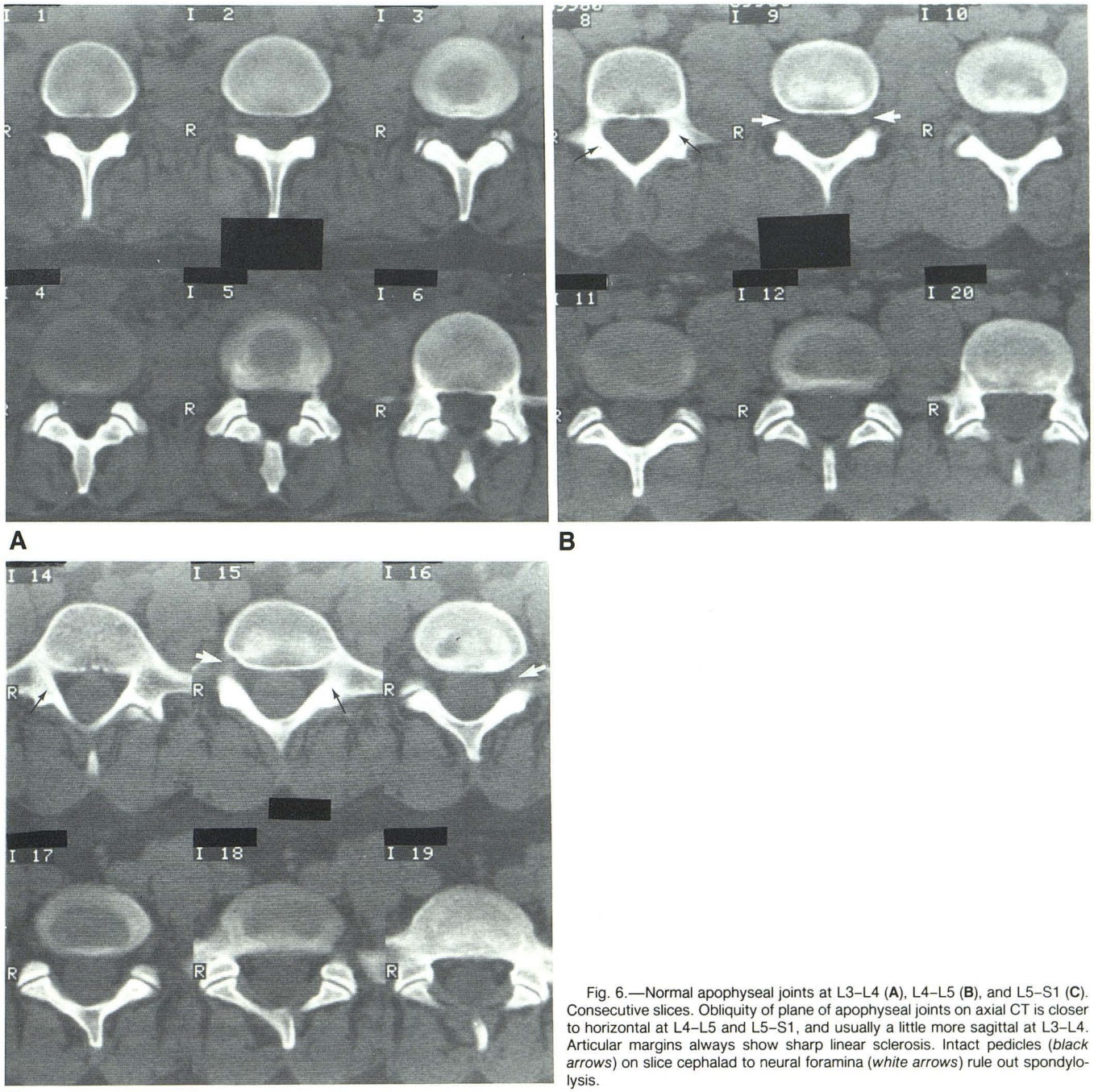

Fig. 6.—Normal apophyseal joints at L3–L4 (**A**), L4–L5 (**B**), and L5–S1 (**C**). Consecutive slices. Obliquity of plane of apophyseal joints on axial CT is closer to horizontal at L4–L5 and L5–S1, and usually a little more sagittal at L3–L4. Articular margins always show sharp linear sclerosis. Intact pedicles (*black arrows*) on slice cephalad to neural foramina (*white arrows*) rule out spondylolysis.

Spondylolysis

Spondylolysis can usually be identified on radiographs, especially on the oblique views. Sometimes tomograms are necessary for a firm diagnosis. If the defects are quite thin, they are often overlooked or not apparent on radiographs.

CT proves to be more sensitive than radiography for detecting spondylolysis. CT also discloses considerably more detail about the defect, including bone fragmentation, extension of fragments of bone or exostosis into the canal or foramina, changes in the shape of the canal, and associated bone anomalies. In our experience, unilateral spondylolysis is extremely rare. We suspect that in many of the reported cases only one of the bilateral defects was clearly apparent on the radiographs. A number of characteristic CT features of spondylolysis permit recognition in virtually every case:

Location of pars defect. In the routine progressive CT slices of a normal interspace, the slice or cut cephalad to the neural foramina is usually at the upper portion or just above the apophyseal joints. Normally this slice will show an intact

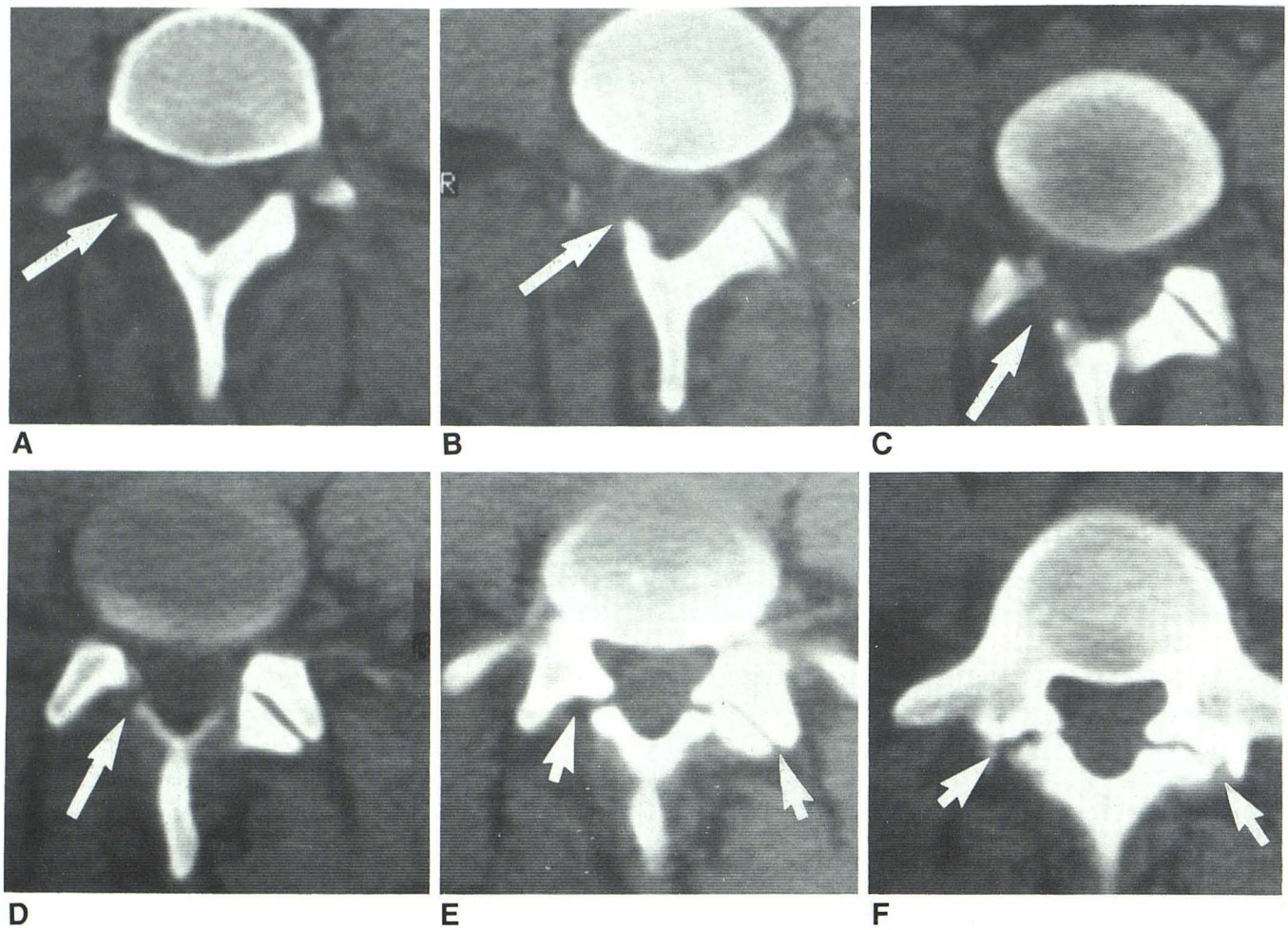

Fig. 7.—Anomaly of lamina and facet associated with spondylolysis. Sequential slices of L4–L5 bone-window study show spondylolytic defects at L5 (*short arrows*). Spondylolisthesis was present at L5–S1. Right lamina and posterior facet of L4 are hypoplastic; facet is virtually absent. Spina bifida and hypoplastic lamina are more common anomalies associated with spondylolysis.

pedicle and little or *no* apophyseal joint (Fig. 6). This appearance virtually rules out spondylolysis at this interspace. In all cases of spondylolysis, the defect will be clearly visible on the slice above the neural foramina (Figs. 2, 3, and 5). Even if the defect strikingly simulates an apophyseal joint (Figs. 3 and 5), its location cephalad to the foramina should allow confident identification.

Plane of defect. In most cases the plane of the defect is more horizontal than the usual apophyseal joints (Figs. 2 and 3).

CT appearance of the defect. Usually the defect is quite irregular, and appears as a "break" in the bone (Figs. 2, 5, and 7). Infrequently, the defect is quite regular and will superficially resemble an apophyseal joint. The location of this slice above the neural foramina will avoid erroneous interpretation. An unusually thin, regular defect may be difficult to identify on the radiograph (Fig. 3). Occasionally, multiple small bone fragments are seen at the defect; some of these may extend into the canal or foramen.

Bone edges of the defect. The normal apophyseal joint always shows rather thick and dense sclerotic articular margins (Fig. 6). Even if a pars defect resembles a joint, a normal sclerotic "articular" margin will usually be absent. The low-density medullary cavity can often be seen extending clear to the edge of the bone (Fig. 5), which does not occur in a true articular margin with its normal sclerosis.

Shape of bone margins. Frequently, the medial aspect of the bone just anterior to the defect has a small rounded dense protuberance that extends medially and caudally (Figs. 3, 5, and 8). Its appearance is quite characteristic. The caudad extension of the protuberance may appear on a lower slice as a "floating bone fragment" just anterior to the joint (Figs. 2, 5, and 8). This latter appearance is virtually diagnostic of spondylolysis, even if the next cephalad cut showing the actual defect is not available.

Anomalies. It is not unusual to find some minor associated bone anomalies. Spina bifida and hypoplastic (unilateral) laminae are the most common (Figs. 7 and 9). These may occur

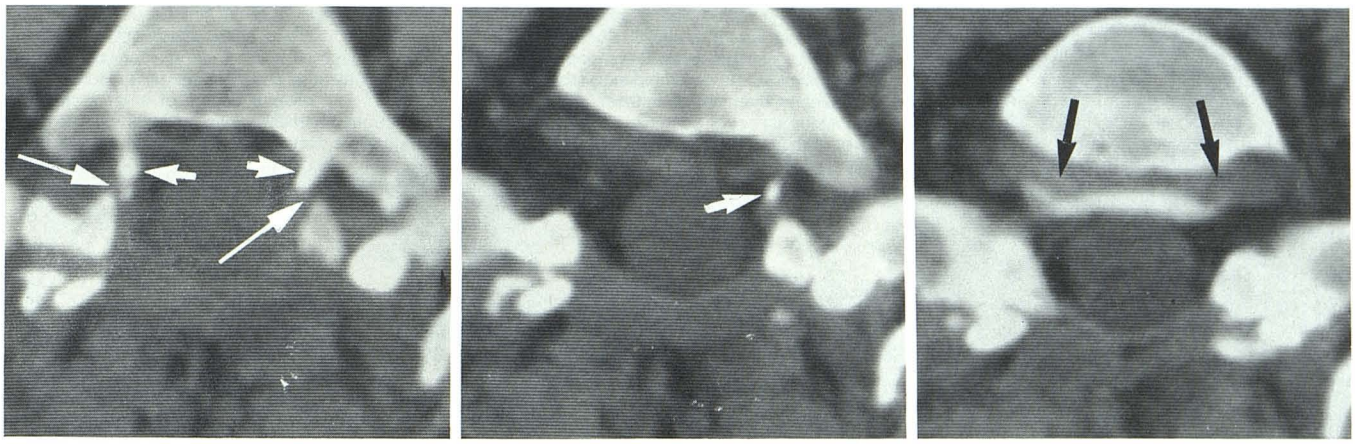

A B C

Fig. 8.—Surgery for spondylolisthesis: CT findings. **A**, After wide bilateral laminectomy and facetectomy (performed to alleviate symptoms of spondylolisthesis), characteristic sclerotic bone protuberances (*short arrows*) are still readily apparent. Lytic defect (*long arrows*). **B**, "Floating" fragment (caudal extension of protuberance) (*arrow*) lies anterior to facet. **C**, Characteristic pseudobulging disk (*arrows*) has been partly "replaced" by posterior lip of S1.

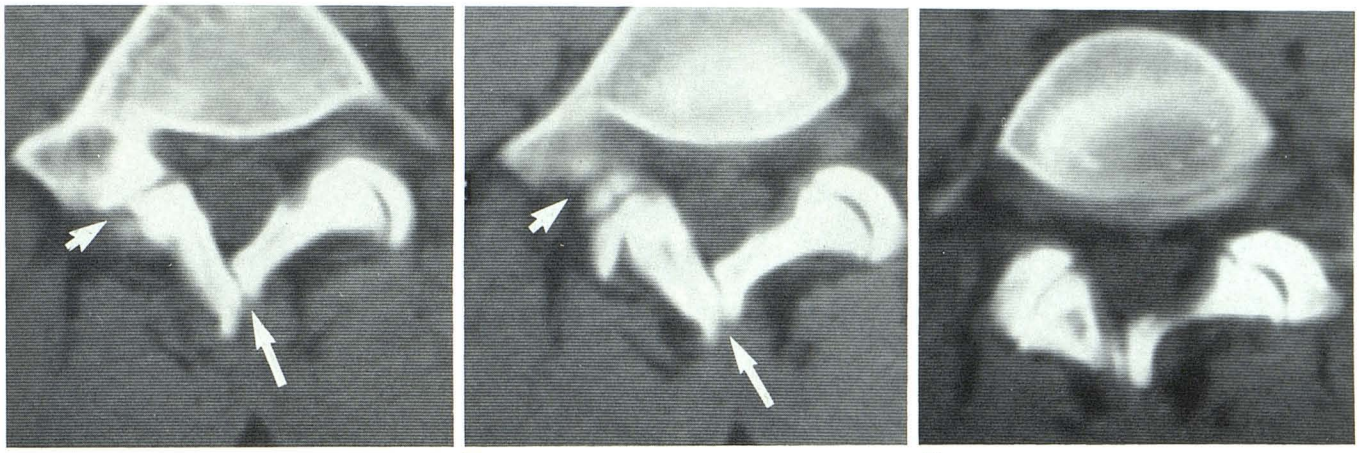

A B C

Fig. 9.—Unilateral spondylolysis; associated spina bifida. Sequential slices. Right-sided unilateral spondylolysis (*short arrows*) is associated with spina bifida occulta (*long arrows*). Unilateral spondylolysis is quite uncommon in our experience and, of course, is not associated with spondylolisthesis.

at the spondylolisthesis interspace (usually L5–S1) or at the interspace just above.

Shape of canal and sac. An anteroposterior elongation of the canal with slight medial indentation from the medial bone protuberance mentioned above will usually give an unusual and characteristic appearance. Often the sac assumes an elongated anteroposterior shape as if to accommodate to the canal shape (Figs. 2 and 5).

From these characteristic findings, spondylolysis will always be recognized on appropriate CT studies. The superiority of CT recognition became apparent in 25 of our cases of spondylolysis. In all these cases the radiographs were considered negative, showing neither spondylolysis or spondylolisthesis. Our findings came as a complete surprise to the clinicians. In several of these, even careful scrutiny of oblique radiographs failed to demonstrate an unequivocal defect.

In the statistical breakdown of our cases, 13.4% were listed as spondylolysis without spondylolisthesis on the *radiographs*. However, CT findings in over half of these showed a definite small pseudobulging disk, indicating some degree of slippage. Our findings suggest that bilateral spondylolysis without slippage is infrequent, despite the apparent absence of spondylolisthesis on the *radiographs*.

Since thin spondylolytic defects are often difficult or impossible to recognize on conventional radiographs, and since such defects are *almost always* associated with some degree of slippage recognizable on CT, a CT study to rule out spondylolysis and mild degrees of spondylolisthesis might be indicated in some patients with persistent backache but without obvious radiographic abnormalities.

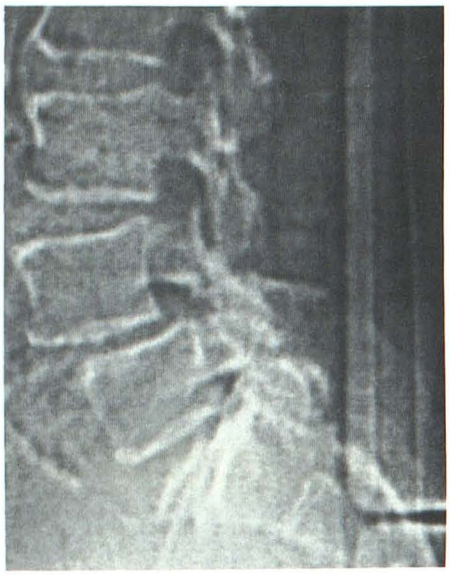

A

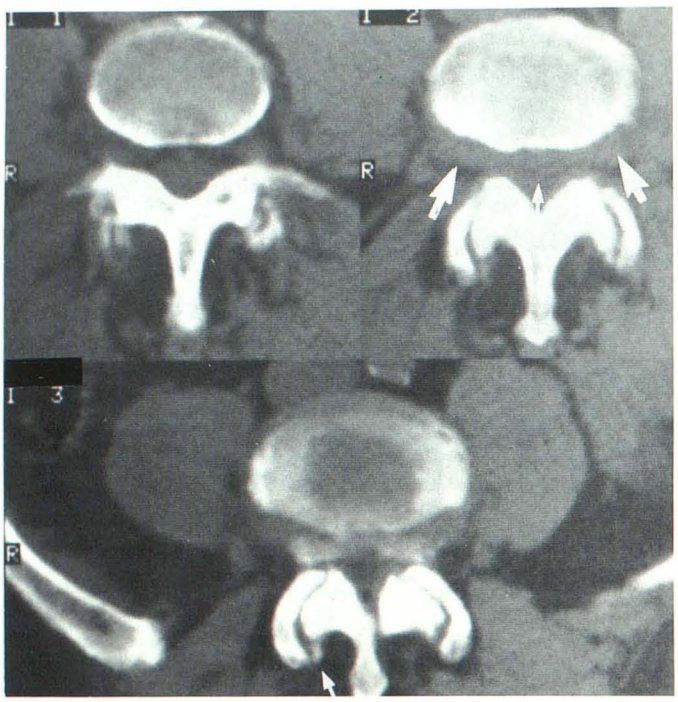

B

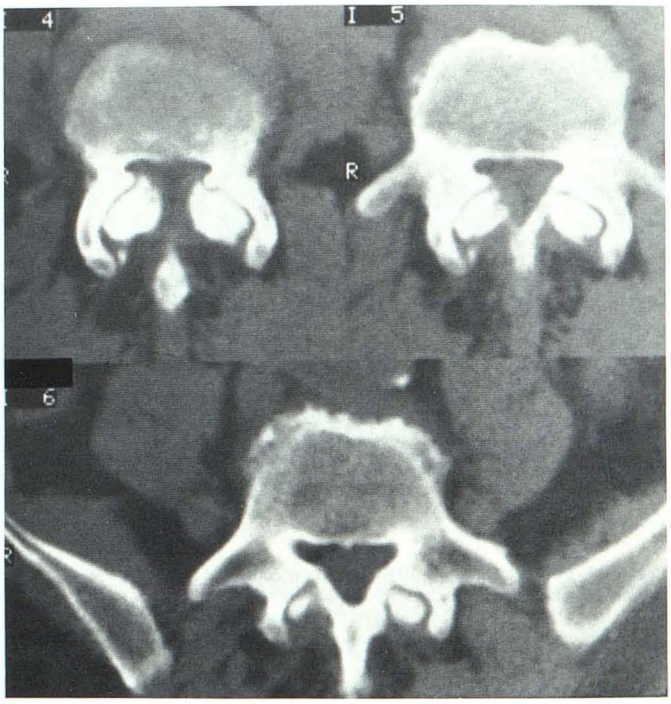

C

Fig. 10.—Typical facet changes of degenerative spondylolisthesis. **A**, Scout film. Grade I spondylolisthesis of L4 on L5. **B** and **C**, Consecutive bone-window scans at L4–L5 show characteristic facet and joint changes of degenerative spondylolisthesis: (1) Plane of these joints is much more sagitally oriented than usual. (2) Anterior (superior) facet is clearly displaced posteriorly and on many cuts extends more posteriorly than posterior facet. (3) Osteophyte extends from posterior aspect of anterior facet to posterior aspect of posterior facet (*small arrow*). (4) Moderate degenerate joint changes are apparent, e.g., pseudobulging disk (*large arrows*) and compromising AP diameter of canal, even on this bone window.

Degenerative Spondylolisthesis and the Apophyseal Joints

In most cases of degenerative spondylolisthesis, characteristic changes were seen in the corresponding apophyseal joints:

The plane of these joints is oriented sagittally (Figs. 10 and 11) instead of horizontally (Fig. 6). This sagittal joint orientation is a developmental variation and may be seen in some patients without spondylolisthesis.

The anterior facet (superior facet of caudad vertebra) will be laterally and posteriorly "displaced" with reference to the posterior facet (Figs. 10 and 11). This change is consistent with the posterior position of the lower vertebra in the spondylolisthesis.

Often a bony spur or outgrowth of the posterior portion of this anterior facet will extend medially and actually be behind the posterior facet. Whether this represents an "effort" toward stabilization of the slippage is conjectural.

In some cases of degenerative spondylolisthesis, there appears to be anterior facet displacement on one side and minimal or absent displacement on the other. Such asymmetric changes strongly suggest that there has been vertebral

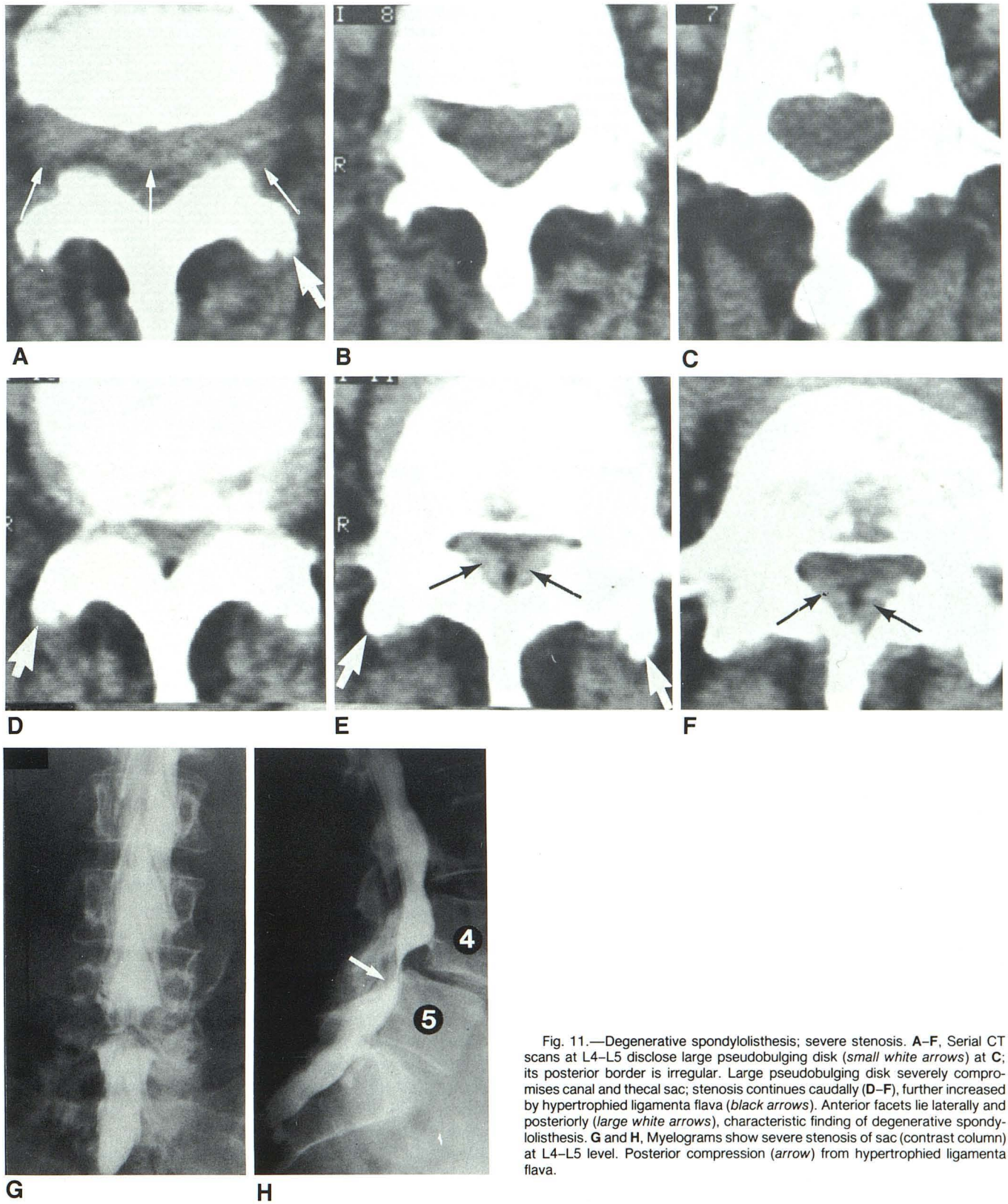

Fig. 11.—Degenerative spondylolisthesis; severe stenosis. **A–F**, Serial CT scans at L4–L5 disclose large pseudobulging disk (*small white arrows*) at **C**; its posterior border is irregular. Large pseudobulging disk severely compromises canal and thecal sac; stenosis continues caudally (**D–F**), further increased by hypertrophied ligamenta flava (*black arrows*). Anterior facets lie laterally and posteriorly (*large white arrows*), characteristic finding of degenerative spondylolisthesis. **G** and **H**, Myelograms show severe stenosis of sac (contrast column) at L4–L5 level. Posterior compression (*arrow*) from hypertrophied ligamenta flava.

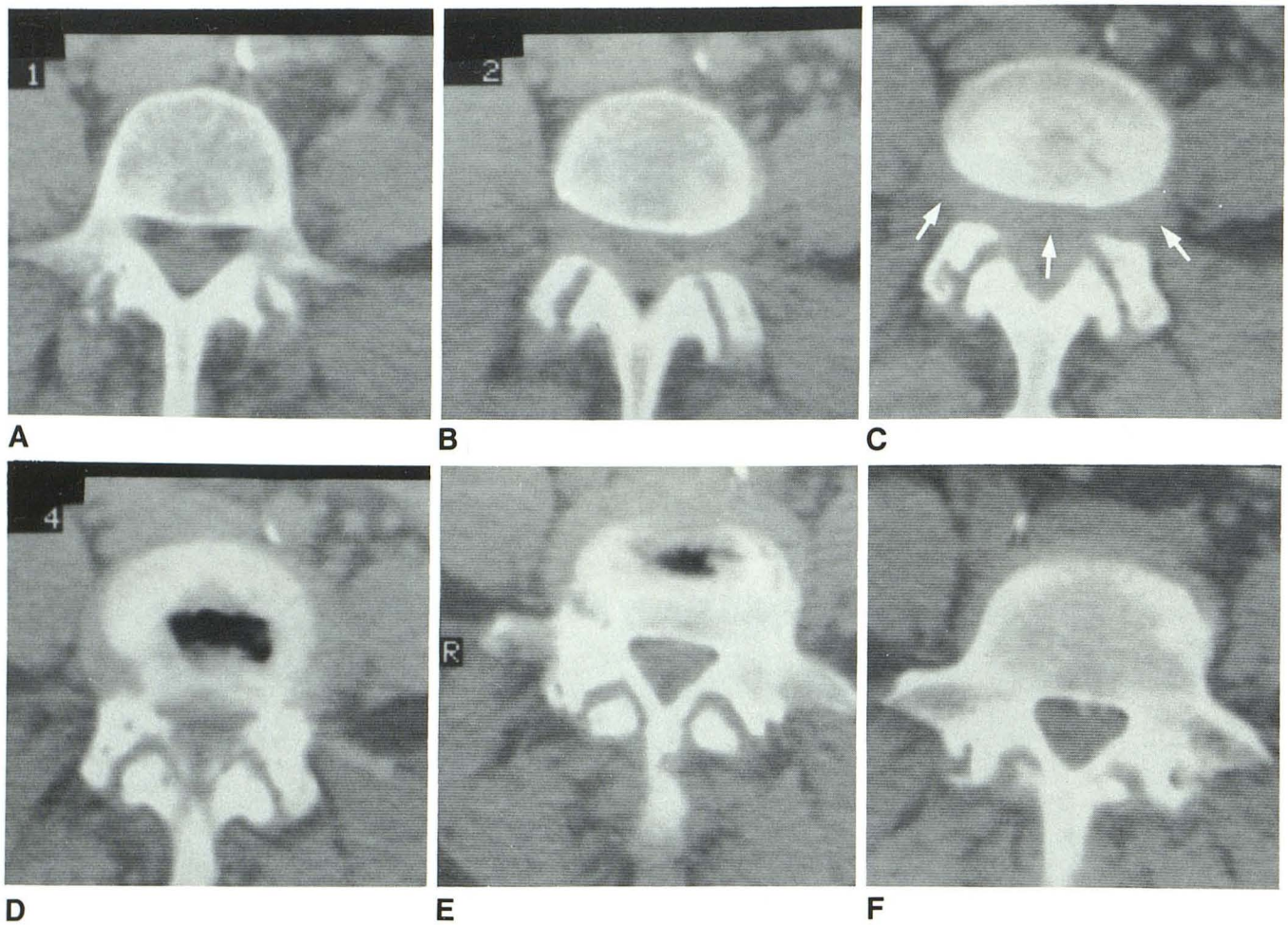

Fig. 12.—Degenerative spondylolisthesis; atypical joint changes. Consecutive scans at L4–L5 show large pseudobulging disk (*arrows*) indicative of sizeable spondylolisthesis. However, no spondylolysis is seen. Apophyseal joints have sagittal-plane orientation, but anterior facets are not displaced posteriorly—the usual finding in degenerative spondylolisthesis. Instead, joint spaces are widened considerably, probably another manifestation of subluxation associated with slippage.

rotation in addition to spondylolisthesis [8]. The clinical significance of this is unclear.

In cases of degenerative spondylolisthesis with more horizontally oriented joints, the slippage may be manifested by irregular widening of the joint spaces without recognizable alteration of position (Fig. 12). Vacuum apophyseal joints are common (Fig. 13). Although the development of spondylolisthesis in horizontally oriented joints is probably associated with some posterior rotation of the anterior facet, this cannot be identified on CT. Only the abnormal joint widening reflects the luxation.

The joints at the involved level show some degree of degenerative disease in almost every case. It has been commonly believed that the degenerative joint disease, accompanied by ligament laxity, is the principal predisposing factor of the slippage. Because frequently the other apophyseal joints (above and below the slippage interspace) are free of degenerative changes, perhaps the degenerative joint disease of the joints involved in the spondylolisthesis is the *result* of the slippage and not the cause. The sagittally oriented joints might be the major predisposing mechanical factor.

Reverse Spondylolisthesis

Reverse spondylolisthesis refers to posterior displacement of a vertebral body with reference to the next inferior (caudal) body. No spondylolysis is involved in the slippage. Reverse spondylolisthesis usually occurs at L2–L3 or L3–L4 and less often at L4–L5. The slippage is rarely greater than a few millimeters (Fig. 14). As in degenerative spondylolisthesis, the joints usually are oriented sagittally. The anterior facet will appear displaced anteriorly, but only slightly (Fig. 14). Sometimes even this minimal facet displacement may encroach on the neural foramina. Of interest is the usual absence of degenerative joint disease, in contrast to the severe degenerative joint disease in degenerative spondylolisthesis. In reverse spondylolisthesis the pseudobulging disk is usually difficult to identify on CT, perhaps because fibrocartilage

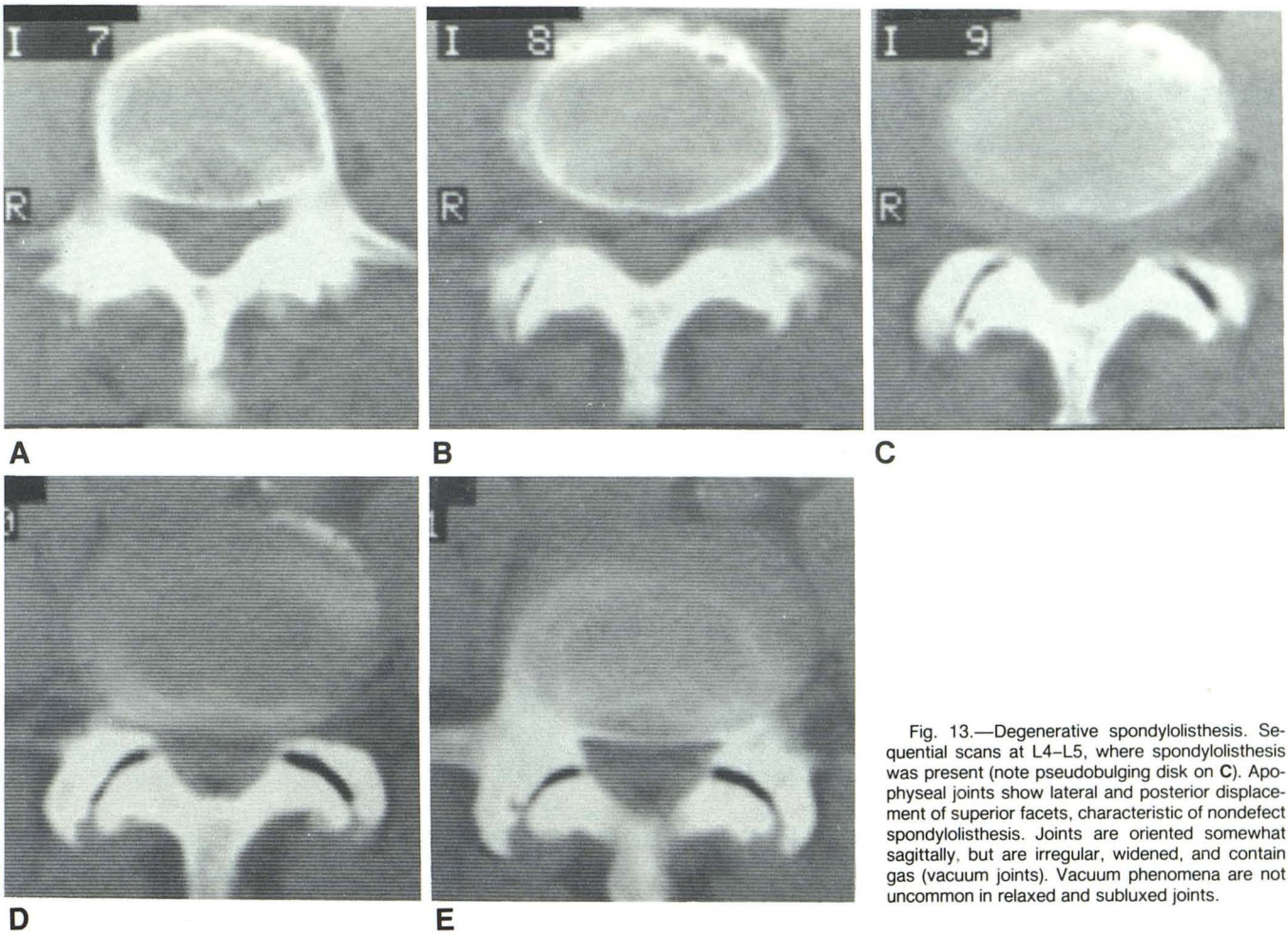

Fig. 13.—Degenerative spondylolisthesis. Sequential scans at L4–L5, where spondylolisthesis was present (note pseudobulging disk on **C**). Apophyseal joints show lateral and posterior displacement of superior facets, characteristic of nondefect spondylolisthesis. Joints are oriented somewhat sagittally, but are irregular, widened, and contain gas (vacuum joints). Vacuum phenomena are not uncommon in relaxed and subluxed joints.

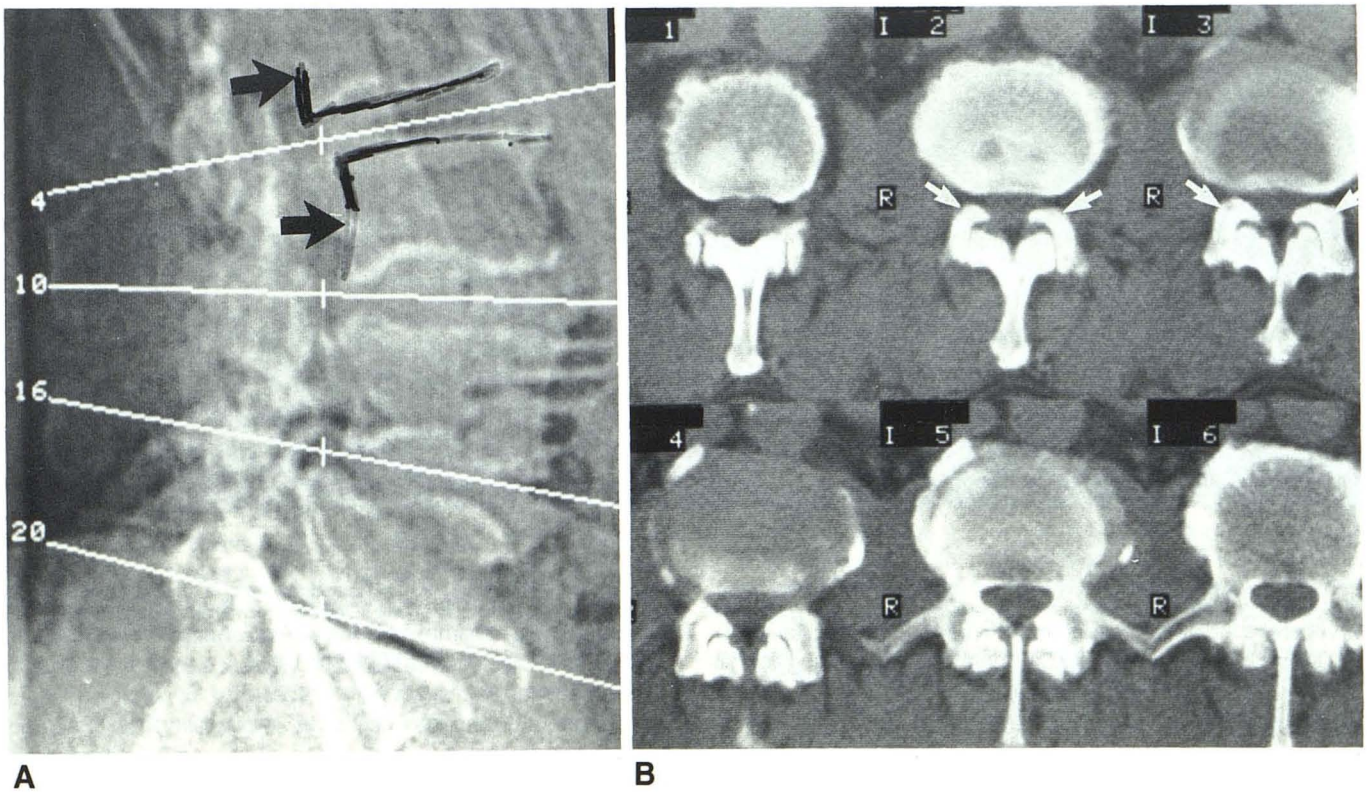

Fig. 14.—Reverse spondylolisthesis at L2–L3. Scout view (retouched) shows anterior displacement of L3 relevant to L2 (*black arrows*). Incidentally, degenerative spondylolisthesis is also present at L4–L5. **B**, Consecutive slices at L2–L3 show characteristic forward displacement of anterior (inferior) facets (*arrows*), which encroach on neural foramina and lead to widening of anterior portion of joint spaces. Note completely vertical plane of posterior two-thirds of apophyseal joints. Degenerative changes in apophyseal joints are minimal in contrast to joints in degenerative spondylolisthesis.

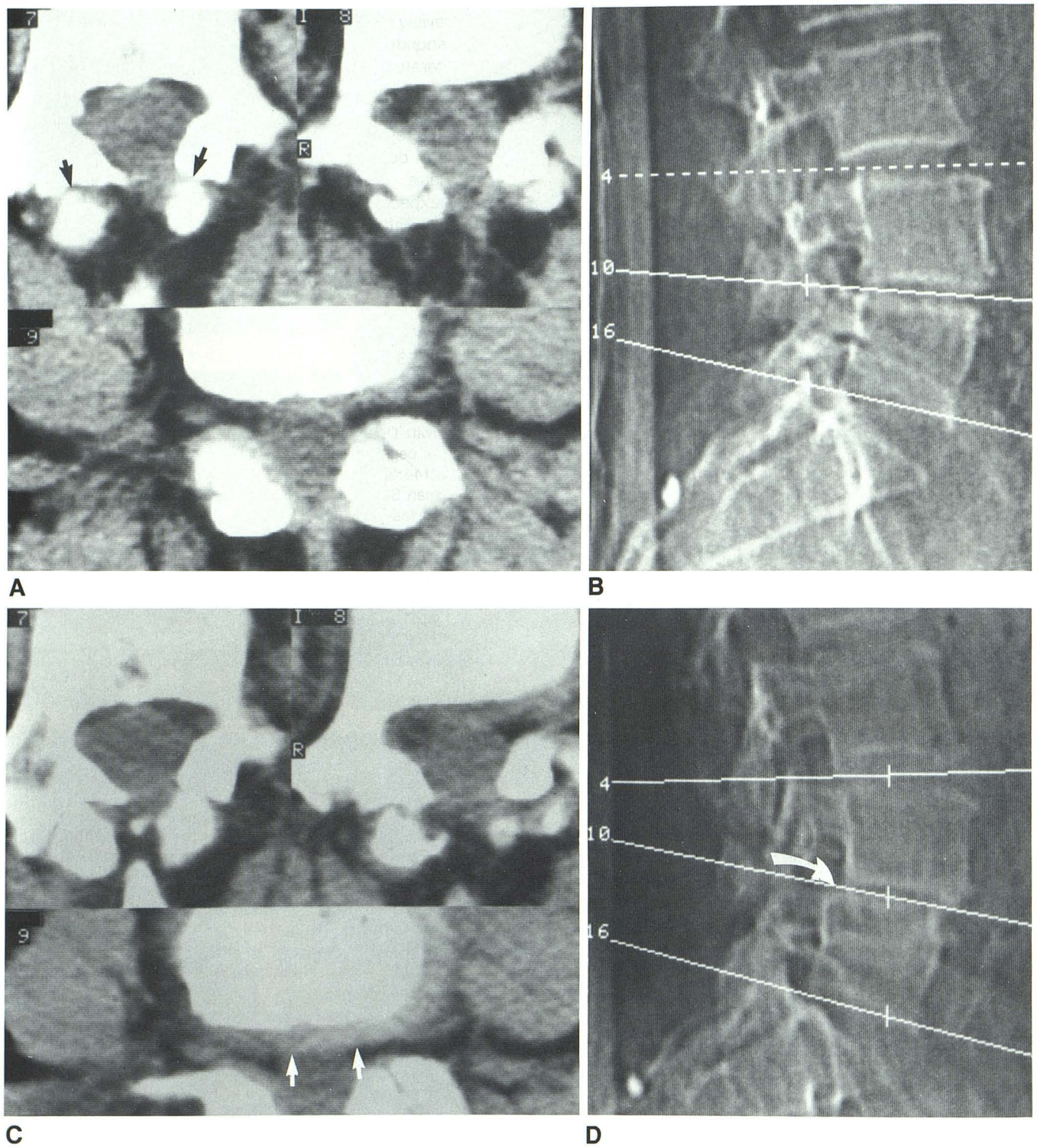

Fig. 15.—Spondylolisthesis: complication of laminectomy. **A**, Consecutive slices at L4–L5 3 years after laminectomy show evidence of surgery, but canal was otherwise normal. Bilateral spondylolysis (*arrows*). **B**, Scout film shows narrowed L4–L5 interspace; no evidence of spondylolisthesis. **C**, Consecutive slices at L4–L5 15 months later. Soft-tissue density (*arrows*) posterior to L4 suggests pseudobulging disk of spondylolisthesis. **D**, Scout film confirms spondylolisthesis (*arrow*) of L4 on L5. Although increased slippage of preexisting spondylolisthesis after laminectomy is not uncommon, de novo slippage is rare complication of laminectomy and facetectomy.

overgrowth is minimal or absent. It is usually the anterior facet displacement that calls attention to reverse spondylolisthesis on the scan.

Postoperative Spondylolisthesis

In postlaminectomy and postfacetectomy spondylolisthesis (Fig. 15), usually there is extensive resection of facets and joints without fusion that probably allows slippage. Fortunately, this surgical complication is rare.

Discussion

In contrast to other reports [6, 7], we have found that in almost every case axial views alone can furnish the necessary information on spondylolysis and spondylolisthesis. In the exceptional case in which some uncertainty results from the axial and angled slices, the patient can return for the consecutive perpendicular slices needed for coronal and sagittal reconstructions. Our prime reliance on axial views is shared by some others [1, 5].

Our CT incidence of the various types of spondylolisthesis was fairly consistent with other reports [8, 12, 13]. However, we encountered degenerative spondylolisthesis (pseudospondylolisthesis or articular spondylolisthesis) [9, 12, 15, 16] more often (35.5%) than other authors did. Spondylolisthesis either from facet dysplasia, after trauma or from neoplastic destruction [8, 12, 17] is rare and was not encountered in our CT studies.

The high incidence (96%) of L5–S1 spondylolysis and spondylolisthesis and the L4–L5 incidence (92%) of degenerative spondylolisthesis are consistent with other published reports [9, 11, 12, 15].

The pseudobulging disk is clearly the major CT finding in spondylolisthesis, as illustrated in Figure 1. The hypertrophy and irregularity of this bulging soft tissue has been observed by others [1, 4, 5, 8, 9] and is considered to be caused by a fibrocartilaginous buildup and overgrowth [3, 7, 8]. The characteristic lateral extension of the pseudobulge into the neural foramina has not been emphasized previously, but this appears to be a distinctive CT feature. It does not have the appearance of a diffusely bulging anulus, which can be clearly seen uniformly surrounding the adjacent vertebral end-plate.

The focal stenosis of the canal below the pseudobulging disk has been a known feature in most cases of spondylolisthesis [12], and it is clearly appreciated on CT [8, 9].

The CT appearance of spondylolysis and of the associated elongated canal and thecal sac have been described [1, 3, 5, 8].

The radiographic findings of degenerative spondylolisthesis have been described [4, 8, 12, 15], and the alteration of the plane of the facets and their osteoarthritic changes [2, 8, 9, 11, 12, 16] are well known. Our data suggest that this type of spondylolisthesis is more common than had been believed.

CT changes in retrolisthesis (reverse spondylolisthesis), including facet alterations, have been described briefly [8, 9] in recent literature.

Our review of the CT findings in the cases of spondylolysis and/or spondylolisthesis in our file, abetted by a few reports in the literature, convinces us that axial CT is the superior method for uncovering spondylolysis. Axial CT also can disclose unsuspected small degrees of spondylolisthesis and is a superior method for evaluation of facet and apophyseal joint changes in degenerative spondylolisthesis or reverse spondylolisthesis.

An unexpected finding was CT evidence of a small degree of spondylolisthesis in many cases of spondylolysis in which radiographs showed no apparent spondylolisthesis. Unilateral spondylolysis is extremely rare on CT, unlike pre-CT reports in the literature.

REFERENCES

1. Grogan JP, Hemminghytt S, Williams AL, Carrera GF, Haughton VM. Spondylolysis studied by CT. *Radiology* **1982**;145:737–742
2. Lefkowitz DM, Quencer RM. Vacuum facet phenomenon: a CT sign of degenerative spondylolisthesis (case report). *Radiology* **1982**;144:562
3. Rothman SLG, Glenn WV Jr. CT multiplanar reconstruction in 253 cases of lumbar spondylolisthesis (case report). *AJNR* **1984**;5:81–90
4. Genant HK, Chafetz N, Helms CA. *CT of lumbar spine*. Berkeley, CA: University of California Press, **1982**:157–181
5. Haughton VM, Williams AT. *CT of the spine*. St. Louis: Mosby, **1982**:141
6. Heithoff KB. CT and stenosis. In: Post JD, ed. *CT of the lumbar spine*. Baltimore: Williams & Wilkins, **1984**:506–545
7. Rothman SLG, Glenn WV Jr. Spondylolysis and spondylolisthesis. In: Post JD, ed. *CT of the lumbar spine*. Baltimore: Williams & Wilkins, **1984**:591–615
8. Rothman SLG, Glenn WV Jr. Spondylolysis and spondylolisthesis. Newton TH, Dotts DG, eds. *CT of the spine and spinal canal*. San Anselmo, CA: Clavadel, **1983**:267–280
9. Sheldon JJ, Lebargne JM. Degenerative spondylolisthesis. In: Post JD, ed. *CT of the lumbar spine*. Baltimore: Williams & Wilkins, **1984**:577–579
10. Bradford DS. Management of spondylolysis and spondylolisthesis. In: Evarts CM, ed. *Instructional course lectures*, vol 32. American Association of Orthopedic Surgeons. St. Louis: Mosby, **1983**:151–162
11. Brown MD, Lockwood JM. Degenerative spondylolisthesis. In: Evarts CM, ed. *Instructional course lectures*, vol 32. American Association of Orthopaedic Surgeons. St. Louis: Mosby, **1983**:162–166
12. Epstein BS. Lumbar spondylolisthesis. In: *The spine*. Philadelphia: Lea & Febiger, **1969**:504–525
13. Hensinger RN. Spondylolysis and Spondylolisthesis. *Instructional course lectures*, vol 32. American Association of Orthopaedic Surgeons. St. Louis: Mosby, **1983**:132–152
14. Leger JL, Bouchard R, Maltais R. Radiologic study of 305 cases of spondylolysis with or without spondylolisthesis. *J Can Assoc Radiol* **1979**;30:86–90
15. Macnab I. Spondylolisthesis. In: *Backache*. Baltimore: Williams & Wilkins, **1979**:44–63
16. Resnick D, Viwayama G. Spondylolisthesis. In: *Diagnosis of bone and joint disorders*. Philadelphia: Saunders, **1981**:1393–1396
17. Shapiro R. Spondylolisthesis. In: *Myelography*. Chicago: Yearbook Medical, **1984**:520–525