

Are your **MRI contrast agents** cost-effective?

Learn more about generic **Gadolinium-Based Contrast Agents**.



FRESENIUS
KABI

caring for life

AJNR

CT and MR of angiomatous malformations of the choroid plexus in patients with Sturge-Weber disease.

G K Stimac, M A Solomon and T H Newton

AJNR Am J Neuroradiol 1986, 7 (4) 623-627

<http://www.ajnr.org/content/7/4/623>

This information is current as of June 5, 2024.

CT and MR of Angiomatous Malformations of the Choroid Plexus in Patients with Sturge-Weber Disease

Gary K. Stimac¹
Murray A. Solomon²
T. H. Newton³

Eight patients with Sturge-Weber disease were evaluated by CT (six patients), MR (one patient), or both (one patient). CT scans of five of seven patients showed enlargement and increased enhancement of the choroid plexus on the same side as the facial and intracranial lesions. MRI showed similar findings in both patients examined. This enlargement, seen in six of eight cases of Sturge-Weber disease, is compatible with the presence of angiomatous malformations of the choroid plexus. It appears to be a common finding in this disease.

Sturge-Weber disease is a neurocutaneous syndrome characterized by port-wine stain (nevus flammeus) of the face, and leptomeningeal angiomatosis. The disease has been extensively reviewed in the literature [1-11]. The primary lesions of Sturge-Weber disease are venous angiomas, located mainly in the leptomeninges. These angiomas have been seen in the lung, gastrointestinal tract, ovaries, pancreas, adrenal glands, pituitary, globe, and choroid plexus. The choroid plexus angiomas have been noted in the neuropathology literature [12], and, in a report of two cases, in the radiology literature [13]. Of the eight Sturge-Weber patients that we studied, six showed enlargement and increased enhancement of the choroid plexus on the side affected by the facial nevus and leptomeningeal angioma. We believe the choroid plexus is commonly involved in this disease.

Subjects and Methods

We reviewed eight cases of Sturge-Weber disease to evaluate the appearance of the glomus of the choroid plexus of the lateral ventricles. CT scans of four patients without and with contrast material were performed using a GE 8800 system. A fifth patient was scanned on an Ohio Nuclear Delta CT scanner. A slice thickness of 1 cm was used on all scans. In two patients, MRI using spin-echo multislice technique on a Diationsics (MT/S) 0.35-T imager was performed with TR-2 sec, TE-28 and 56 msec, and four data acquisitions. A slice thickness of 7 mm with a 3-mm interslice gap was used on MR scans. All scans were evaluated by at least two independent observers.

To determine whether the enhancement and extent of calcification of the choroid plexus in our patients was unusual, we examined CT scans of 107 patients who had no evidence of Sturge-Weber disease (most had experienced trauma or had metabolic disease). The transverse diameter of the calcification (on noncontrast scans) and the enhancement (on contrast scans) of the glomus of the choroid plexus was measured with Vernier calipers and was corrected for magnification. Because CT slices were contiguous and the object of measurement (calcification or enhancement) was dense, partial volume errors were not encountered in these measurements. The size of the glomus of the choroid plexus as identified by its intensity and by the anatomical borders at the trigone of the lateral ventricles was similarly measured on MR. Partial volume errors could occur in the measurement of the choroid plexus on MR scans due to the interslice gap of 3 mm, but in both our cases, the difference in size was obvious.

Received September 7, 1984; accepted after revision January 14, 1986.

¹ Department of Radiology, University of Washington, Seattle, WA 98195. Address reprint requests to G. K. Stimac.

² Department of Radiology, San Jose MRI Center, San Jose, CA 95128.

³ Department of Radiology, University of California, San Francisco, CA 94143.

AJNR 7:623-627, July/August 1986
0195-6108/86/0704-0623
© American Society of Neuroradiology

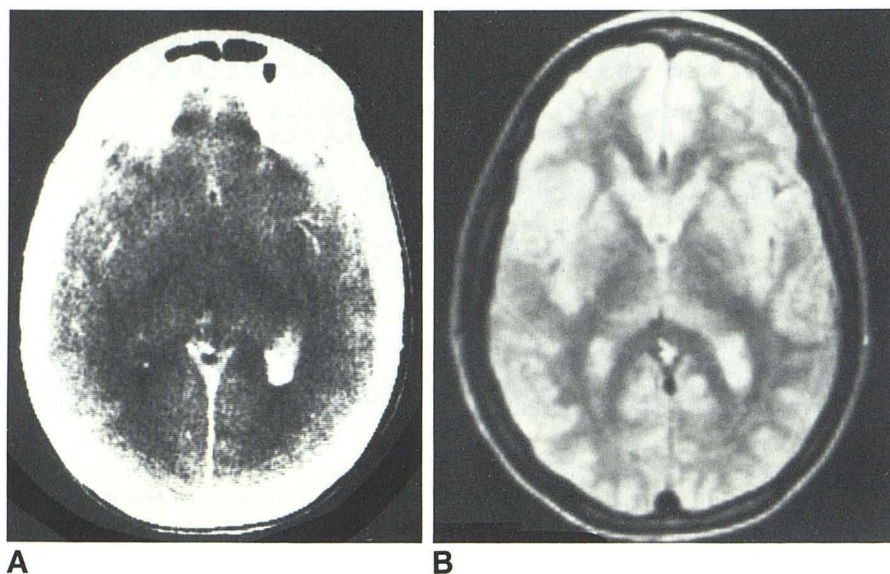


Fig. 1.—Case 1. **A**, Contrast CT shows increased enhancement of glomus of choroid plexus on left (the side of the facial port-wine stain). **B**, MR scan using T2-weighted spin-echo technique (TR-2000, TE-56 msec) shows increased intensity in same location.



Fig. 2.—Case 2. **A**, Noncontrast CT shows calcification of glomus of choroid plexus on left, the side of the facial nevus. **B**, Contrast CT at same level shows gyral enhancement in left occipital lobe, characteristic of Sturge-Weber disease. In addition, choroid plexus on same side shows increased enhancement.

Case Reports

Case 1

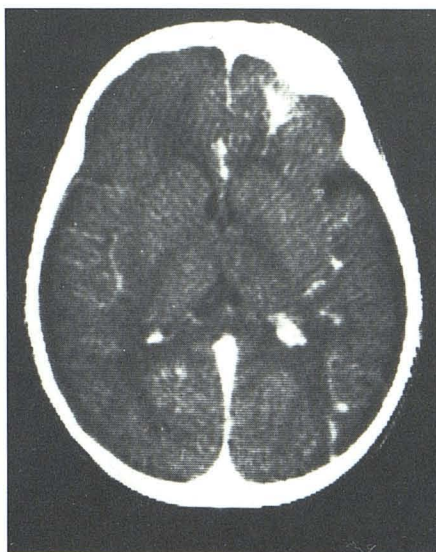
A 19-year-old woman had a large nevus flammeus in the first and second divisions of the fifth cranial nerve on the left side of her face since birth. She had also been blind in the left eye throughout most of her life after developing glaucoma. Optic atrophy on the left and papilledema on the right were noted. The patient was of above-average intelligence, had no weakness, and had never had a seizure. Her primary complaint was severe headaches that were unresponsive to medications. CT scans with and without contrast material showed enlargement, calcification, and increased enhancement of the left glomus of the choroid plexus (Fig. 1A). None of the typical intracranial findings of the Sturge-Weber syndrome were seen in this patient.

Carotid angiography was normal. There was no evidence of increased arterial flow or venous stasis in the region of the choroid plexus. The sagittal sinus was patent. MR showed an area of prolonged T2 relaxation time in the region of the left choroid plexus (Fig. 1B).

Case 2

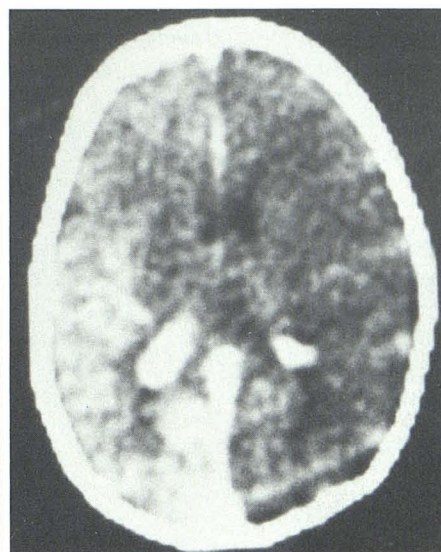
A 22-year-old woman with a left facial nevus flammeus had a history of blackout spells. Noncontrast CT scan showed increased calcification of the left choroid plexus as compared with the right side (Fig. 2A). The contrast-enhanced scan showed serpiginous enhancement in the occipital lobe (Fig. 2B). Increased enhancement was seen around the calcified choroid plexus on the left side. At least one of these enhancing structures appears to represent a draining vein.

Fig. 3.—Case 3. Contrast-enhanced CT shows left frontal lobe enhancement of leptomeningeal angioma and more prominent enhancement of choroid plexus on left. Noncontrast scan showed calcification in left frontal lobe but not in choroid plexus.



3

Fig. 4.—Case 4. Contrast CT shows gyral enhancement of leptomeningeal angioma and increased enhancement of right glomus of choroid plexus.



4

Case 3

A 1-year-old girl with left facial nevus flammeus had right hemiparesis and intermittent seizures. CT scan without contrast showed a large area of calcification in the left frontal lobe, but no calcification of the choroid plexus. After the administration of intravenous contrast, high density in the frontal lobe indicated enhancement of the leptomeningeal angioma. In addition, the enhancement of the left choroid plexus was more prominent than that on the right side (Fig. 3).

Case 4

A 3-month-old boy was diagnosed at birth as having Sturge-Weber syndrome by the presence of a predominantly right-sided facial nevus flammeus. He had intermittent seizures and had recently developed glaucoma in the right eye. The nevus also involved the right trunk, right arm and hip, and a portion of the left side of the face. CT scan without contrast showed slight hemiatrophy of the right side of the brain. After the administration of intravenous contrast, a large parietooccipital area of enhancement, predominantly along the gyri, was seen on the right. In addition, the enhanced choroid plexus was larger on the right side than on the left (Fig. 4).

Case 5

A 28-year-old man, born after prolonged labor and requiring low forceps, was noted at birth to have a facial nevus of the right forehead. He experienced his first seizure at the age of 4 months. As a child, he had seizures consisting of generalized convulsions, right-sided focal seizures, and frequent "petit mal" spells characterized by brief losses of consciousness that ended shortly after he fell to the ground. At age 15, he had attained a school level of grade 3. The patient had weakness of the right side with the right extremities being smaller and shorter than those on the left.

An MR scan of the head showed hemiatrophy of the left side of the brain, linear and punctate regions of signal dropout in the left temporoparietooccipital region suspected of having calcifications, and enlargement of the glomus in the left atrial region (Fig. 5). In addition,

high signal intensity was noted in this region on first and second echoes of long TR sequences, compatible with flow-related enhancement [14, 15] and even-echo rephasing [14, 15]. (CT has never been performed in this patient.)

Discussion

The findings of Sturge-Weber syndrome are well known. Clinically, the diagnosis is easily made by the characteristic appearance of the facial port-wine stain (nevus flammeus). Venous angioma of the choroid plexus on the affected side has been noted in case reports [12, 13]; increased enhancement of the choroid plexus as a common finding in patients with Sturge-Weber disease has not been suggested. In seven cases for which we have CT scans, five showed increased choroid calcification and/or enhancement. MR, performed in two of our patients, showed an area of prolonged T2 relaxation time in the area of contrast enhancement. In all, six of our eight patients showed choroid plexus enlargement on the affected side.

Histopathologic abnormalities in the choroid plexus consist of replacement of normal choroid tufts by thin-walled capillaries and small veins, and the formation of angiomatous cavernomas. The lesions are proliferative, resulting in enlargement of the choroid plexus [12]. Calcification appears to follow atrophy of normal tissue, as is found elsewhere in the body, particularly the brain.

The appearance of the choroid plexus on CT and MR scans is consistent with the pathologic changes in the choroid plexus described previously [3, 12, 13]. Calcification, enlargement, and contrast enhancement are well demonstrated in our cases. The angiomatous malformations are not expected to be seen by angiography because of the slow flow associated with these lesions. The high intensity seen on T2-weighted MR images can be explained either as increased

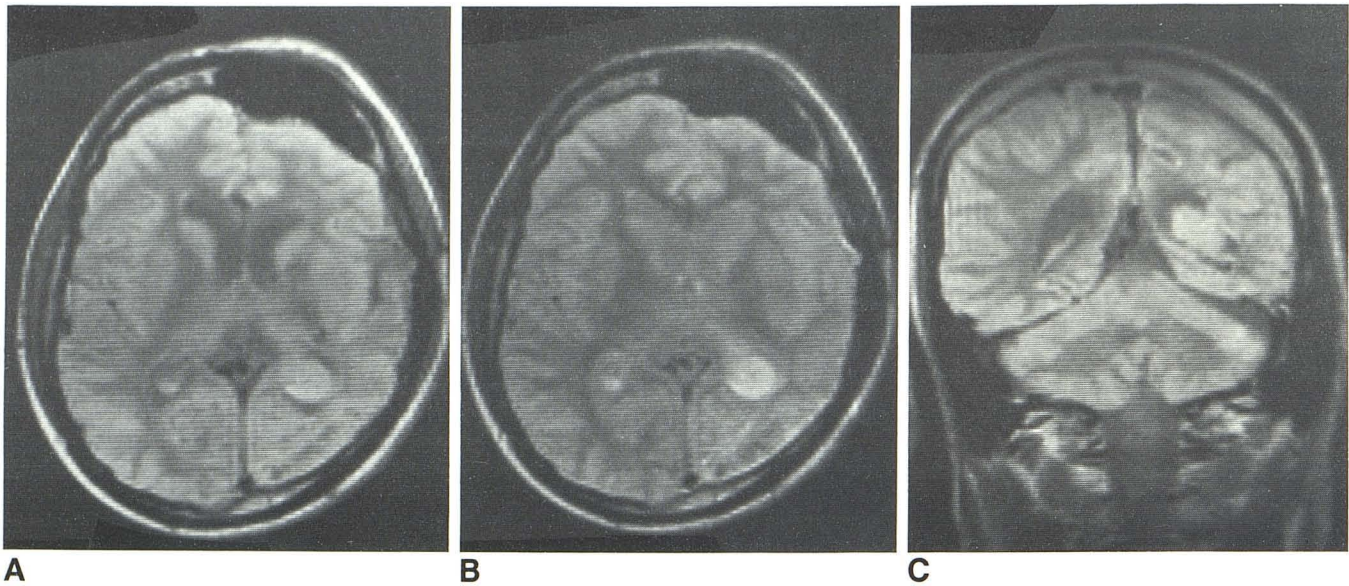


Fig. 5.—Case 5. **A**, MR scan (TR-2000 and TE-28 msec) shows left-brain hemiatrophy with enlargement of ipsilateral frontal sinus. Low signal in occipital lobe suggests presence of calcification. Glomus of choroid plexus on left is

much larger than that on right and, in **B**, appears as high intensity on second echo (TR-2000, TE-56 msec). **C**, Coronal view (TR-2000, TE-28 msec) further demonstrates enlarged left glomus of choroid plexus.

TABLE 1: Size^a of Choroid Plexus in Normal Subjects (*n* = 107)

Age Group	No. of Patients	Average Size		Average Difference ^b
		Ca ⁺⁺	Enhanced	
0–5	10	0.0	—	0.0
6–10	14	0.5	2.5	0.0
11–15	9	0.8	3.5	0.8
16–20	30	3.0	5.2	0.5
21–25	23	3.7	5.3	1.2
26–30	21	5.0	4.5	0.8

^a Size is the diameter of the glomus of the choroid plexus. The width of calcification (Ca⁺⁺) was measured on noncontrast scans, the area of enhancement was measured on contrast scans. Measurements are in mm.

^b The difference in size between the left and right glomera.

fluid (blood or edema) content of the lesion or as increased intensity related to the slow flow of venous blood [14, 15].

Comparing the size of the choroid plexus in normal subjects and in patients with Sturge-Weber disease (as indicated by the size of the calcifications, the amount of enhancement, and the high intensity on MR scans) shows that the average size of the choroid plexus in our controls (Table 1) was much smaller than that of the Sturge-Weber patients (Table 2). The average difference in the sizes of the right and left glomera of the choroid plexus was small in the controls, less than 1 mm, but very large in six of eight patients with Sturge-Weber disease, ranging from 4.0 to 15 mm.

Of the eight cases of Sturge-Weber syndrome for which we have CT or MR scans, six showed involvement of the choroid plexus. Both cases reported by Welch, et al. [13] showed such abnormality. It appears that venous angioma of the choroid plexus is a relatively common finding in patients who have Sturge-Weber syndrome. This lesion can be well seen on CT and MR.

TABLE 2: Size^a of Choroid Plexus in Patients with Sturge-Weber Disease

Case No.	Age	Average Size			Difference ^b	
		Ca ⁺⁺	Enhanced	MR	CT	MR
1	19	—	7.5	7.5	15	15
2	21	1.5	3	—	6	—
3	1	0	4	—	4	—
4	3 mo.	—	13	—	7.5	—
5	28	—	—	8	—	8
6	25	2	6	—	8	—
7	6	0	—	—	0	—
8	10	—	1.5	—	0	—

^a Size is the diameter of the glomus of the choroid plexus. The width of calcification (Ca⁺⁺) was measured on noncontrast scans, the area of enhancement was measured on contrast scans. Measurements are in mm.

^b The difference in size between the left and right glomera.

Conclusions

The presence on CT scans of enlargement and increased enhancement of the choroid plexus on the affected side may be the only identifiable intracranial abnormality in a patient with Sturge-Weber disease. This abnormality represents angiomatous involvement of the choroid plexus and is probably present in many patients with Sturge-Weber disease. The abnormality can also be demonstrated by MR.

REFERENCES

1. Sturge WA. A case of partial epilepsy, apparently due to a lesion of one of the vaso-motor centers of the brain. *Trans Clin Soc London* 1879;12:162–167
2. Weber FP. Right-sided hemi-hypertrophy resulting from right-sided congenital spastic hemiplegia, with a morbid condition of

- the left side of the brain, revealed by radiograms. *J Neurol Psychopathol* **1922**;3:134-139
3. Coulam CM, Brown LR, Reese DF. Sturge-Weber syndrome. *Semin Roentgenol* **1976**;1:55-60
 4. Alexander GL, Norman RM. The Sturge-Weber syndrome. Bristol: John Wright & Sons, **1960**
 5. Poser CM, Taveras JM. Cerebral angiography in encephalotrigeminal angiomas. *Radiology* **1957**;68:327-336
 6. Di Chiro G, Lindren E. Radiographic findings in 14 cases of the Sturge-Weber syndrome. *Acta Radiol [Diagn]* (Stockh) **1951**;35:387-399
 7. Enzmann DR, Hayward RW, Norman D, Dunn RP. Cranial computed tomographic scan appearance of Sturge-Weber disease: unusual presentation. *Radiology* **1977**;122:721-724
 8. Osonoff MB, Burrows EH. Pathologic intracranial calcification. In: Newton TH, Potts DG, eds. *Radiology of the skull and brain: the skull*, Vol 1, Book 2, St. Louis: Mosby, **1971**:832-833
 9. Bentson JR, Wilson GH, Newton TH. Cerebral venous drainage pattern of the Sturge-Weber syndrome. *Radiology* **1971**;101:111-118
 10. Kuhl DE, Bevilacqua JR, Mishkin MM, Sanders TP. The brain scan in Sturge-Weber syndrome. *Radiology* **1971**;103:621-626
 11. Kalischer S. Demonstration des Gehirnes eines Kindes mit Teleangiectasie der linksseitigen Gesichtskopfhaut und Hirnoberfläche. *Berl Klin Wochenschr* **1897**;1059
 12. Wohlwill FJ, Yakovlev PI. Histopathology of meningo-facial angiomas (Sturge-Weber disease): report of four cases. *J Neuropathol Exp Neurol* **1957**;16:341-364
 13. Welch K, Naheedy MH, Abrams IF, Strand RD. Computed tomography of Sturge-Weber syndrome in infants. *J Comput Asst Tomogr* **1980**;4(1):33-36
 14. Mills CM, Brandt-Zawadzki M, Crooks LE. Nuclear magnetic resonance: principals of blood flow imaging. *AJNR* **1983**;4:1161-1166
 15. Bradley WG, Waluch V. Blood flow: magnetic resonance imaging. *Radiology* **1985**;154:443-450