

Are your **MRI contrast agents** cost-effective?

Learn more about generic **Gadolinium-Based Contrast Agents**.



FRESENIUS
KABI

caring for life

AJNR

Anterior cervical meningoceles in neurofibromatosis.

M C Kaiser, R G De Slegte, F C Crezée and J Valk

AJNR Am J Neuroradiol 1986, 7 (6) 1105

<http://www.ajnr.org/content/7/6/1105.citation>

This information is current as
of April 17, 2024.

Abbreviated Report

Anterior Cervical Meningoceles in Neurofibromatosis

A 40-year-old man with Von Recklinghausen's disease presented with sudden onset of right-sided cervical pain combined with swallowing disturbances. The pain irradiated into the shoulder and was exacerbated by coughing. Clinical examination showed an anterior soft-tissue swelling in the neck and a weakness of the right arm as compared with the left. An initial diagnosis of a prevertebral neurofibroma was raised. Cervical myelography by the lumbar route was done, complemented by secondary CT myelography. Relatively poor opacification of the cervical canal due to contrast accumulation within prevertebral CSF-filled pouches was obtained (Fig. 1). Subsequent high-resolution CT scans showed severe dysplasia of several vertebrae. Large diverticular outpouchings widened the vertebral canal and, at the level C3, an extensive meningocele protruded through a vertebral defect. This mass was responsible for the swelling on the right side, and compromise of the upper airways was apparent (Fig. 2). The meningocele extended along the anterior aspect of C1 to C3; further outpouchings protruding through eroded, enlarged foramina were also present at other levels.

Thoracic and lumbosacral meningoceles in association with neurofibromatosis have been described [1-5, 6, 7]. In the cervical region prevertebral neurofibromas are frequent in this disease and they may be large enough to compromise the upper airways and to require tracheostomy [8]. To the best of our knowledge multiple anterior cervical meningoceles have not yet been described in neurofibromatosis. The pathogenesis of this unusual finding remains uncertain: it is probably associated with the dural ectasia found in this disease. Various factors, such as trauma, cystic degeneration of a neurofibroma, and dural and bony dysplasias have been incriminated [2]. Meningoceles may be asymptomatic, and, if one exists, does not necessarily mean that it should be treated. The probability of its gradual enlargement with time and the possibility that it may cause

pain and dyspnea should be weighed against the risks of anesthesia and surgery. In our opinion the indication for surgery in cervical meningoceles should be related to the degree of existing discomfort in swallowing and breathing.

M. C. Kaiser
R. G. M. De Slegte
F. C. Crezée
J. Valk

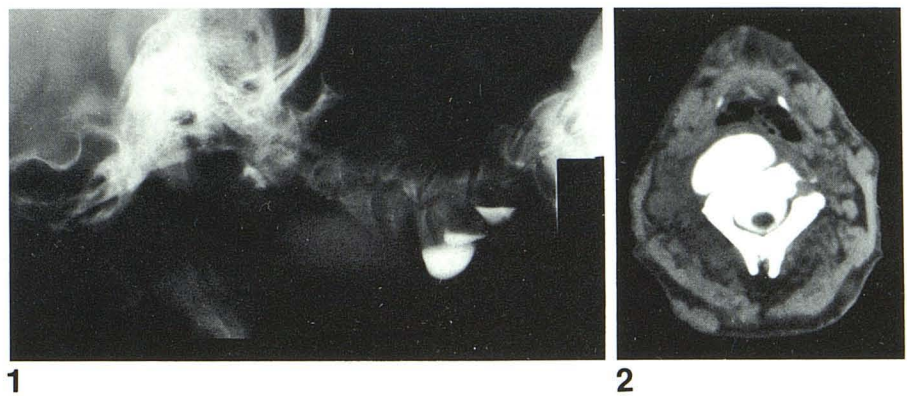
Hospital Free University of Amsterdam
1007 MB Amsterdam
The Netherlands

REFERENCES

1. Bunner R. Lateral intrathoracic meningocele. *Acta Radiol* 1959;51:1-9
2. Erkulvratr S, El Gammal T, Hawkins J, Green JB, Strinivasan G. Intrathoracic meningoceles and neurofibromatosis. *Arch Neurol* 1979;36:557-559
3. Leech RW, Olafson RA, Gilbertson RL, Shook DR. Intrathoracic meningocele and vertebral anomalies in a case of neurofibromatosis. *Surg Neurol* 1978;9:55-57
4. Naidich TP. Arachnoid cysts. Paravertebral meningoceles and perineural cysts. In: Newton TH, Potts DG, eds. *Computed tomography of the spine and spinal cord*. San Anselmo: Clavadel Press, 1983:383-397
5. Naidich TP, McLone DG, Harwood-Nash DC. Systemic malformations. In: Newton TH, Potts DG, eds. *Computed tomography of the spine and spinal cord*. San Anselmo: Clavadel Press, 1983:367-383
6. Weinreb JC, Arger PH, Grossman R, Samuel L. CT metrizamide myelography in multiple bilateral intrathoracic meningoceles. *J Comput Assist Tomogr* 1984;8:324-326
7. Wolkins RH, Odon GL. Anterior and lateral spinal meningoceles. In: Vincken PJ, Bruyn GW, eds. *Handbook of clinical neurology*. Amsterdam: Elsevier, 1978:222-224
8. Steichen FM, Einhorn AM, Fellini A, Feind CR. Congenital retropharyngeal neurofibroma causing laryngeal obstruction in a newborn. *J Pediatr Surg* 1971;6:480-481

Fig. 1.—Cervical myelography by lumbar route shows contrast accumulation in prevertebral dural outpouchings while there was only faint opacification of vertebral canal. Notice that most of contrast material collects within lower meningoceles.

Fig. 2.—Secondary CT myelography, axial cut at level of C3. Dysplastic vertebra with large bone defect seen on right. Extensive meningocele protrudes out of canal into prevertebral space and compresses upper airways.



1

2