

Are your **MRI contrast agents** cost-effective?

Learn more about generic **Gadolinium-Based Contrast Agents**.



FRESENIUS
KABI

caring for life

AJNR

The optic neurogram: evaluation of CSF "block" caused by compressive lesions at the optic canal.

J R Jenkins

AJNR Am J Neuroradiol 1987, 8 (1) 135-139

<http://www.ajnr.org/content/8/1/135>

This information is current as
of April 20, 2024.

The Optic Neurogram: Evaluation of CSF "Block" Caused by Compressive Lesions at the Optic Canal

John R. Jinkins¹

Patients with progressive blindness resulting from bony proliferative diseases such as osteopetrosis may benefit from optic canal decompression. A radiologic technique is described whereby the practicality of surgical optic canal widening is evaluated preoperatively using the intrathecal water-soluble contrast agent Iopamidol. Conceptually, if a patient who is losing vision demonstrates a block on the optic neurogram, then likely there is still sufficient neural tissue within the optic canal and sheath to cause obstruction, and therefore decompression may be indicated. However, if preoperatively there is no block to Iopamidol, then surgical intervention is not indicated, as the nerve has already undergone severe atrophy to the point of "autodecompression." Cases of differing etiologies, with and without blocks, illustrate the utility of the method and point out the importance of early surgical management to prevent irreversible damage to the optic nerve.

Contrast radiography of the subarachnoid space surrounding the intrathecal optic nerve has been accomplished either intentionally or inadvertently by a number of authors using various positive and negative contrast agents [1-8]. Virtually any developmental or acquired disease process can potentially interrupt the free flow of CSF along the optic nerve sheath due to compressive or adhesive mechanisms. In the Arabian peninsula, adverse genetic combinations resulting from consanguineous unions produce a significant number of patients with syndromes causing encroachment upon the neural foramina at the base of the skull, leading to multiple cranial neuropathies. Two such genetic syndromes encountered in high frequency are classical Albers-Schönberg osteopetrosis and osteopetrosis secondary to carbonic anhydrase II deficiency, an inborn error of metabolism [9-19]. In an effort to determine prospectively the efficacy and need in such patients for surgical decompression of the optic nerve at the optic canal, a study using water-soluble contrast cisternography was undertaken to evaluate the possibility of a block to the flow of contrast material along the subarachnoid spaces of the optic nerve sheath.

Subjects and Methods

All patients were placed prone on a fluoroscopic tilt-table, and a routine lumbar puncture was performed with a 22-gauge spinal needle. Subsequently, 2-3 ml of 300 mg/ml iodine Iopamidol was instilled, the needle removed, and the patient placed in Trendelenburg position, face down to table, at 45° negative table angle. After 2 min, the table was returned to horizontal and the patient was immediately transferred to the GE 9800 CT scanner on a stretcher, prone, with head extended. The intention was to pool the contrast material in the suprasellar cistern and hold it at this location through the first portion of the CT examination. With the patient prone on the CT couch and with the head extended, 3-mm contiguous coronal sections were obtained perpendicular to the hard palate extending from the sella to the globe. Then, the patient was immediately placed supine, and 3-mm contiguous sections were obtained at an angle bisecting the orbital apex and traversing a distance including the orbit and suprasellar cistern.

Received March 24, 1986; accepted after revision June 10, 1986.

Presented at the annual meeting of the American Society of Neuroradiology, San Diego, CA, January 1986.

¹ Department of Radiology, King Faisal Specialist Hospital and Research Centre, P.O. Box 3354, Riyadh 11211, Kingdom of Saudi Arabia.

AJNR 8:135-139, January/February 1987

0195-6108/87/0801-0135

© American Society of Neuroradiology

The patient population included three subjects with classical osteopetrosis and four with osteopetrosis secondary to carbonic anhydrase II deficiency. They ranged in age from 2 months to 19 years (Table 1). The very young patients required general anesthesia. All patients tolerated the procedure well and no complications were encountered.

Results and Discussion

Compressive lesions of the optic nerve are not uncommon and lead to blindness in the affected eye secondary to various mechanisms, but chiefly to ischemia [20, 21]. Whether surgical alleviation of the compression can restore the function of the optic nerve or at least halt the progressive visual loss is difficult to predict. Certainly each case must be evaluated separately.

Patients with a rather "benign" cause of optic nerve compression such as osteopetrosis (Fig. 1) would seem to be ideal candidates for surgical decompression [12]. However, how to determine potential surgical efficacy preoperatively is seemingly difficult. Three clinicoradiologic parameters were used to overcome this dilemma: (1) visual acuity—normal vs depressed; (2) findings on the optic neurogram—block vs no block; and (3) findings on the optic cisternogram—atrophy vs little or no obvious atrophy. Fundusoscopic evidence of optic atrophy was available only in the older patients in whom adequate examination was possible. Unfortunately, the younger children could not undergo this evaluation and, therefore, fundusoscopic findings, while valuable, could not be accurately ascertained nor included in these parameters.

In normal patients without optic nerve compression, two possible conditions exist: (1) wide communication of the subarachnoid space of the suprasellar cistern with the spaces along the optic nerve (Fig. 2A), which is commonly encountered during cisternography (Fig. 3), or (2) a theoretical condition whereby the arachnoid is in a state of collapse around the optic nerve, which, while not causing compression, will still not admit the flow of contrast material [22]. This latter state may be developmental or possibly acquired in nature,

and its occurrence in otherwise normal individuals has not been determined. Nevertheless, the visual acuity should not depend upon this nonrealized state of the subarachnoid space, and the optic nerves should not be atrophic unless injured by some other process.

Patients with early compression (Fig. 2B) present with decreased visual acuity, block on the optic neurogram, and no obvious atrophy on cisternography (Fig. 4). These are the ideal candidates for surgical decompression of the optic canal. Ideally, surgical alleviation of pressure on the nerve will stop the process of vision loss, prevent continued irreversible optic atrophy, and even enable some return of vision. The duration and progression of visual loss in this series before presentation was inaccurate and based on unconfirmed history. No meaningful follow-up is available on this small group of patients, as one refused surgery and two have not been followed for a sufficiently long period to allow a realistic assessment.

Finally, patients with long-standing optic nerve compression

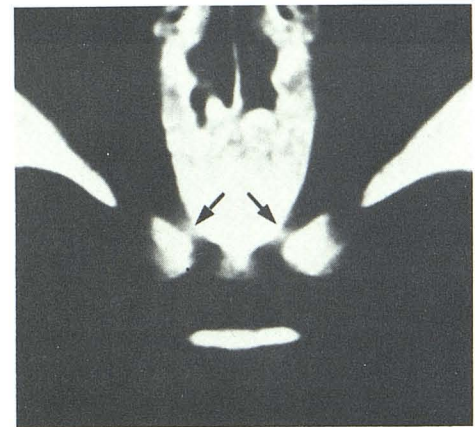


Fig. 1.—Thin-section axial CT scan at level of orbital apex demonstrating dense, thickened bony structures and suggesting evidence of encroachment on optic canals (arrows).

TABLE 1: Osteopetrosis: Patient Summary

Diagnosis: Case No.	Age	Gender	Visual Acuity	Optic Neurogram	Optic Cisternogram	Conclusion
Classical osteopetrosis:						
1	2 mo	M	Unknown	Bilateral block	R ON atrophy	Bilateral compression
2	7 mo	M	"Normal"	No block	No ON atrophy	No compression
3	7 yr	M	OD: CF 1 ft OS: 20/70	No block: OD Block: OS	R ON atrophy	Autodecompression: OD Compression: OS
Carbonic anhydrase II deficiency:						
4	9 yr	M	OD: CF 1 ft OS: CF 6 ft	Bilateral block	No ON atrophy	Bilateral compression
5	11 yr	F	OD: 20/300 OS: 20/200	No block	Bilateral atrophy	Bilateral autodecompression
6	15 yr	F	OD: 20/40 OS: 20/40	No block	No ON atrophy	No compression
7	19 yr	F	OD: 20/200 OS: 20/100	No block	Bilateral ON atrophy	Bilateral autodecompression


Note.—OD = right eye; OS = left eye; CF = counts fingers; ft = foot; ON = optic nerve.

Fig. 2.—Cross section at level of optic canal.

Top: normal. Optic nerve (N) and patent subarachnoid space (A).

Middle: early compression. Bony thickening at optic canal obliterating subarachnoid space and encroaching on nerve.

Bottom: late compression. Extreme optic atrophy with resultant re-manifestation of subarachnoid space leading to “autodecompression.”



may demonstrate blindness and extreme optic nerve atrophy on cisternography, but no block on the optic neurogram (Fig. 5). This seems paradoxical, but is easily explained by the hypothesis that the optic nerve, because of long-term severe compression, has undergone atrophy that has outpaced the degree of canal constriction. Therefore, the shrinkage of the optic nerve has led to a decompression of the subarachnoid space surrounding the nerve and represents a phenomenon of “autodecompression” (Fig. 2C). Obviously, surgery would not be effective in these cases and should be avoided unless rapid clinical deterioration dictates otherwise.

Attempts were made in each case to electronically enhance the various structures as well as the subarachnoid contrast media. Large variations in all parameters including structure size, contrast density, and patient size made standardization of window levels and widths impossible. This led to an inability to accurately quantify measurements of the involved optic structures. This understandably resulted in somewhat subjective judgments regarding the division of “normal” from “atrophy,” and therefore only the obvious extremes were referred to as such in this communication.

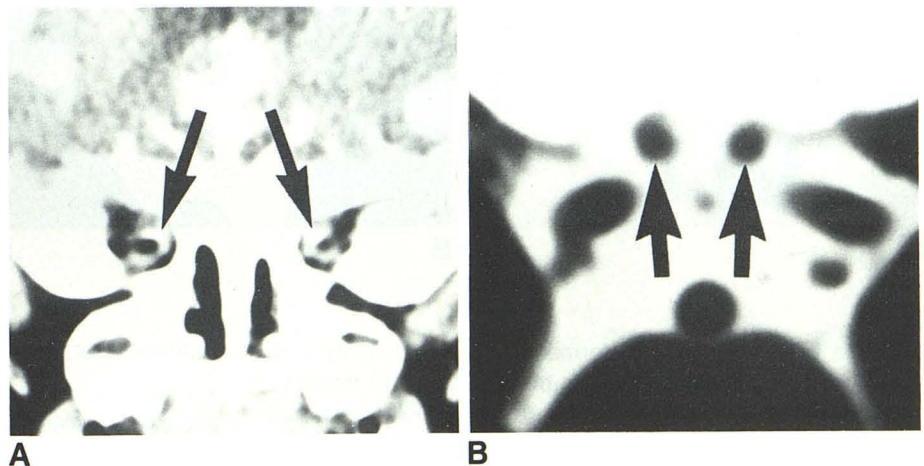
Of interest, this group of patients demonstrated a wide range of findings varying randomly with age, gender, and even from one eye to the other in individual patients (Fig. 6). In each case the combination of the clinical examination, optic neurogram, and optic cisternogram yielded conclusive results allowing a seemingly accurate clinicoradiologic impression (Table 1).

To summarize, in patients having no block, no surgical procedure is indicated as there is no organic lesion to decompress. This is true whether the patient is a “normal” subject or has undergone autodecompression. On the other hand, patients demonstrating a block on the optic neurogram may or may not require surgery. If visual acuity is normal, then simple clinical follow-up may be sufficient. Detection of early visual depression with progression of the disease process may warrant reevaluation for surgical intervention at a later date. However, patients presenting with a block and with decreased visual acuity but without severe optic atrophy mandate surgical decompression as soon as possible to halt the ongoing optic nerve insult (Fig. 7).

Fig. 3.—Case 2. No compression.

A, Optic neurogram illustrating good opacification of subarachnoid space surrounding optic nerves indicating no evidence of block (arrows).

B, Optic cisternogram showing normal-appearing, plump optic nerves in suprasellar cistern (arrows).



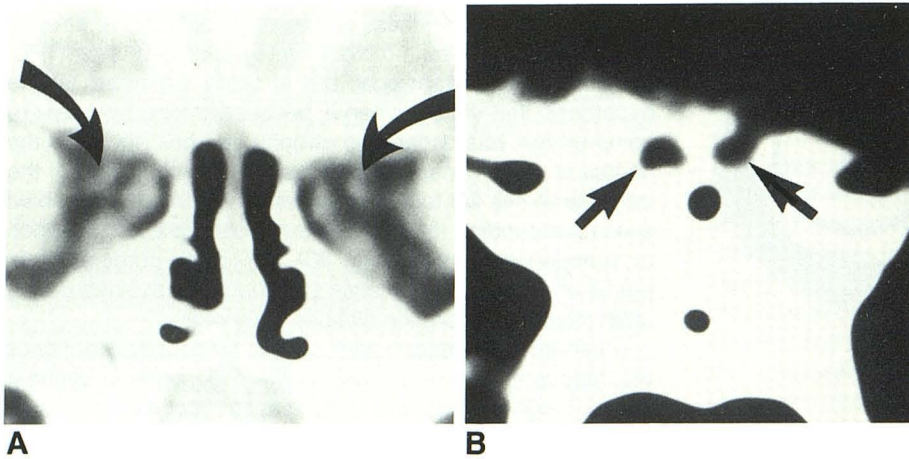


Fig. 4.—Case 1. Bilateral compression.
A, Optic neurogram demonstrating complete bilateral block and diminutive optic nerve/sheath complexes (*arrows*).
B, Optic cisternogram showing typical normal appearance of optic nerves within supra-sellar cistern (*arrows*).

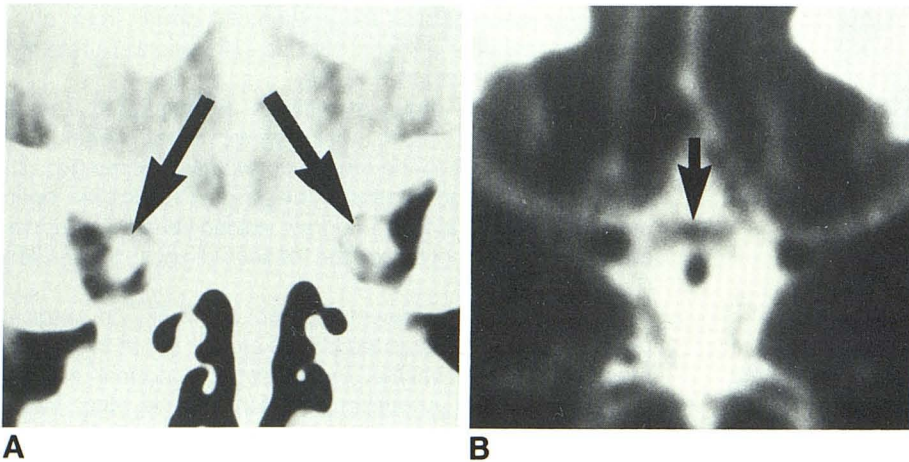


Fig. 5.—Case 7. Bilateral autodecompression.
A, Optic neurogram illustrating good opacification of optic subarachnoid space surrounding shrunken optic nerves (*arrows*).
B, Optic cisternogram showing shrunken optic chiasm (*arrow*).

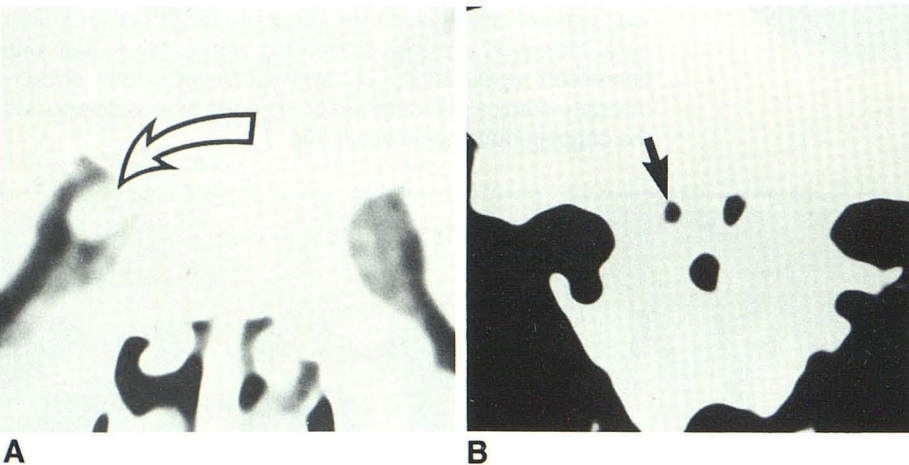


Fig. 6.—Case 3. Left-eye compression; right-eye autodecompression.
A, Optic neurogram demonstrating complete block on left with no block on right. No recognizable right optic nerve sheath on any window setting (*arrow*).
B, Axial optic cisternogram showing plump left optic nerve and atrophic right optic nerve (*arrow*).

While this study was performed solely on patients with osteopetrosis, it would seem that the application of the technique to compressive optic lesions of other etiologies would be helpful, depending on the disease process and the clinical setting.

ACKNOWLEDGMENTS

I thank A. Radford for manuscript preparation, C. Jinkins for manuscript research, and the radiology and photo-graphics departments of King Faisal Specialist Hospital for technical assistance with the illustrations.

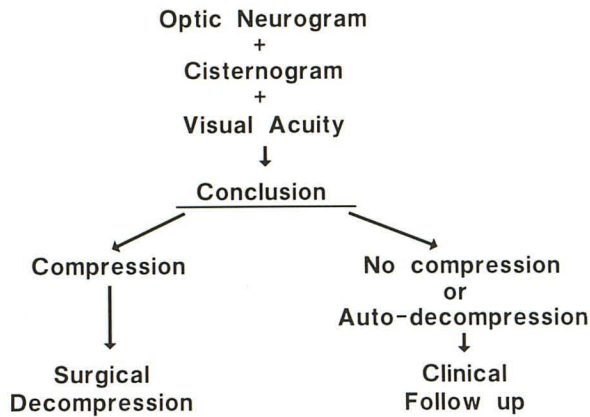


Fig. 7.—Algorithm of integrated approach to compressive lesions at optic canal (see text).

REFERENCES

- Chambers EF, Manelfe C, Cellier P. Metrizamide CT cisternography and perioptic subarachnoid space imaging. *J Comput Assist Tomogr* **1981**;5:875-880
- Fox AJ, Debrun G, Vinuela F, Assis L, Coates R. Intrathecal metrizamide enhancement of the optic nerve sheath. *J Comput Assist Tomogr* **1979**;3:653-656
- Manelfe C, Pasquini U, Bank WO. Metrizamide demonstration of the subarachnoid space surrounding the optic nerves. *J Comput Assist Tomogr* **1978**;2:545-547
- Haughton VM, Davis JP, Eldevik OP, Gager WE. Optic nerve sheath imaging with metrizamide. *Invest Radiol* **1978**;13:544-546
- Haughton VM, Davis JP, Harris GJ, Ho KC. Metrizamide optic nerve sheath opacification. *Invest Radiol* **1980**;15(4):343-345
- Shimojyo S, Gargano F, Ellerman N, David NJ. Contrast radiography of the optic nerve sheath. *Neurology* **1966**;16:621-622
- Tabaddor K. Unusual complications of iophendylate injection myelography. Report of a case and review. *Arch Neurol* **1973**;29:435-436
- Tenner MS, Trokel SL. Demonstration of the intraorbital portion of optic nerves by pneumoencephalography. *Arch Ophthalmol* **1968**;79:572-573
- Amacher AL. Neurological complications of osteopetrosis. *Childs Brain* **1977**;3:257-264
- Beighton P, Horan F, Hamersma H. A review of the osteopetroses. *Postgrad Med J* **1977**;53:507-515
- Cumming WA, Ohlsson A. Intracranial calcification in children with osteopetrosis caused by carbonic anhydrase II deficiency. *Radiology* **1985**;157:325-327
- Ellis PP, Jackson WE. Osteopetrosis. A clinical study of optic-nerve involvement. *Am J Ophthalmol* **1962**;53:943-958
- Loria-Cortes R, Quesada-Calvo E, Cordero-Chaverri C. Osteopetrosis in children. A report of 26 cases. *J Pediatr* **1977**;91(1):43-47
- Miyamoto RT, House WF, Brackmann DE. Neurotologic manifestations of the osteopetroses. *Arch Otolaryngol* **1980**;106:210-214
- Ohlsson A, Stark G, Sakati N. Marble brain disease: recessive osteopetrosis, renal tubular acidosis and cerebral calcification in three Saudi Arabian families. *Devel Med Child Neurol* **1980**;22:72-96
- Puliafito CA, Wray SH, Murray JE, Boger WP III. Optic atrophy and visual loss in craniometaphyseal dysplasia. *Am J Ophthalmol* **1981**;92:696-701
- Riser RO. Marble bones and optic atrophy. *Am J Ophthalmol* **1941**;24:874-878
- Whyte MP, Murphy WA, Fallon MD, et al. Osteopetrosis, renal tubular acidosis and basal ganglia calcification in three sisters. *Am J Med* **1980**;69:64-74
- Wong ML, Balkany TJ, Reeves J, Jafek BW. Head and neck manifestations of malignant osteopetrosis. *Otolaryngol Head Neck Surg* **1978**;86:585-594
- Kennderdell JS, Rosenbaum AE, El-Hoshy MH. Apical optic nerve compression of dysthyroid optic neuropathy on computed tomography. *Arch Ophthalmol* **1981**;99:807-809
- Waybright EA, Selhorst JB, Young HF, Harbison JW. Tumors compressing the optic nerve: diagnosis and surgical results. *Va Med* **1983**;110:230-234
- Lipton HL, Michelson PE. Pseudotumor cerebri syndrome without papilledema. *JAMA* **1972**;220(12):1591-1592