AJNR

Head-hanging CT: an alternative method for evaluating traumatic CSF rhinorrhea.

W E Rothfus, Z L Deeb, R H Daffner and E R Prostko

AJNR Am J Neuroradiol 1987, 8 (1) 155-156
http://www.ajnr.org/content/8/1/155.citation

Head-Hanging CT: An Alternative Method for Evaluating Traumatic CSF Rhinorrhea

William E. Rothfus,[1] Ziad L. Deeb,[1] Richard H. Daffner,[1] and E. Richard Prostko[2]

A number of methods have evolved to examine the patient with posttraumatic CSF rhinorrhea. Until the advent of metrizamide CT cisternography, radioisotope cisternography was the predominant method of investigation. Metrizamide cisternography has preempted the use of isotopes because of its more precise ability to localize the site of CSF leakage [1–5]. However, this method, which requires lumbar or cervical instillation of contrast medium (usually with fluoroscopic guidance) and careful tilting of the patient to guide the contrast into the head, can be cumbersome in severely traumatized patients. We have found a simpler method—CT in the head-hanging position—using intracranial air already present from CSF leak, which demonstrates the site of dural tear in some patients. This technique may be used as an adjunct to, or replacement for, metrizamide cisternography (Fig. 1). Such a method has not been emphasized in the CT literature.

Discussion

In the context of traumatic CSF rhinorrhea, the role of cisternography is to define the site and extent of dural disruption. Metrizamide cisternography combined with high-resolution CT scanning usually provides this definition. Not only can the bony and dural defect be delineated, but metrizamide can be detected passing through the defect and seen in a sinus or nasal cavity [1–5]. However, the actual demonstration of these features is not invariable. In as many as 44% of the patients, metrizamide in the bony defect or air space may not be adequately shown [2]. Even with provocative maneuvers, such as coughing, decubitus positioning, or saline infusion [2–4], slow or intermittent leaks may not be demonstrable.

Recently traumatized patients may be particularly difficult to evaluate with cisternography. Orthopedic devices, respiratory assistance, and other apparatus can make instillation of metrizamide and its placement into the cisterns difficult. The presence of pneumocephalus, especially in large amounts, can preclude adequate dispersion and (CT) visualization of the contrast materials.

We have found head-hanging CT, especially in the coronal position, to be quite useful when pneumocephalus is fairly extensive or when pneumatocele [6, 7] is present. The intra-

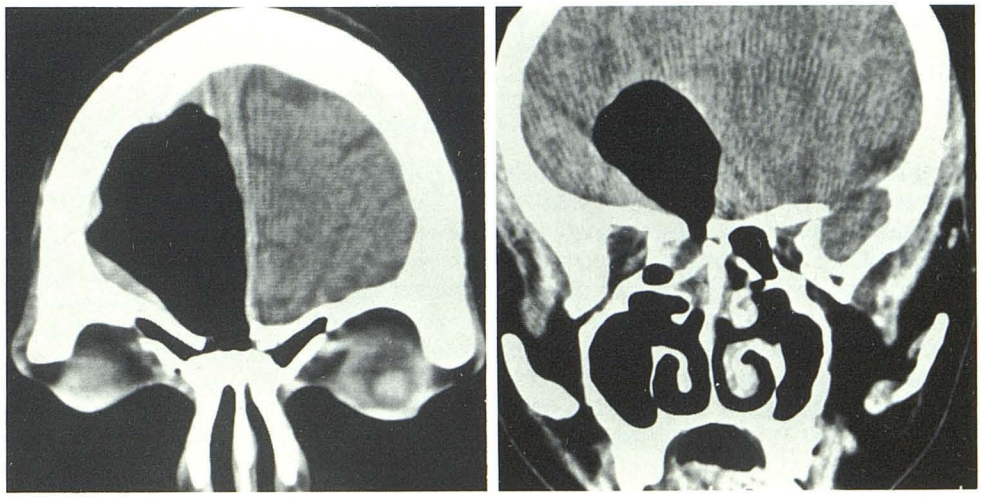

Fig. 1—*A* and *B*, A 27-year-old man sustained multiple facial and skull fractures during a motor vehicle accident. Ten days after the accident, he developed CSF rhinorrhea accompanied by severe headache, confusion, and lethargy. Head-hanging coronal projections (reoriented for easier viewing) illustrate direct communication of a large frontal pneumatocele with the frontal and ethmoid sinuses through a diastatic fracture of the posterior frontal sinus, planum sphenoidale, and tuberculum sellae. Craniotomy confirmed fracture and dural laceration, which were successfully repaired.

Received February 5, 1986; accepted after revision June 10, 1986.
[1] Department of Diagnostic Radiology, Allegheny General Hospital, 320 East North Avenue, Pittsburgh, PA 15212. Address reprint requests to W. E. Rothfus.
[2] Department of Neurosurgery, Allegheny General Hospital, Pittsburgh, PA 15212.

 0195–6108/87/0801–0155

cranial air can then be positioned so as to outline the site of dural tear. Air on both sides of the bony defect without intervening thin dural density indicates an area of free communication between the subarachnoid space and airway.

There has been only one reported case in which intracranial air was used to localize a traumatic (postsurgical) CSF fistula [8]. In this case, the air only indicated the general location of leak and was not manipulated to precisely show the dural tear.

As expected, the head-hanging method does not work in all instances of traumatic CSF fistula. It has been most useful in delineating defects of the cribriform plate, planum sphenoidale, or tuberculum sellae, areas in which the air may be trapped against a broad bony surface. As with metrizamide cisternography, patients with active CSF leakage and prominent bone defects are more apt to have positive studies. Hence, in selected cases, the more invasive metrizamide cisternogram may be obviated.

REFERENCES

1. Drayer BP, Wilkins RH, Boehnke M, Horton JA, Rosenbaum AE. Cerebrospinal fluid rhinorrhea demonstrated by metrizamide CT cisternography. *AJR* **1977**;129:149–151
2. Manelfe C, Cellerier P, Sobel D, Prevost C, Bonafe A. Cerebrospinal fluid rhinorrhea: evaluation with metrizamide cisternography. *AJNR* **1982**;3:25–30
3. Naidich T, Moran CJ. Precise anatomic localization of atraumatic sphenoethmoidal cerebrospinal fluid rhinorrhea by metrizamide CT cisternography. *J Neurosurg* **1980**;53:222–228
4. Ghoshohajra K. Metrizamide CT cisternography in the diagnosis and localization of cerebrospinal fluid rhinorrhea. *JCAT* **1980**;4:306–310
5. Ahmadi J, Weiss MH, Segall HD, Schultz DH, Zee C, Giannotta SL. Evaluation of cerebrospinal fluid rhinorrhea by metrizamide computed tomographic cisternography. *Neurosurgery* **1985**;16:54–60
6. Bhimani S, Virapongse C, Sabshin JK, Sarwar M, Paterson RH. Intracerebral pneumatocele: CT findings. *Radiology* **1985**;154:111–114
7. Mendelsohn DB, Hertzanu Y. Intracerebral pneumatoceles following facial trauma: CT findings. *Radiology* **1985**;154:115–118
8. Fox JL, Schiebel FG. Intracranial air bubbles localizing cerebrospinal fluid fistula. *J Comput Asst Tomogr* **1979**;3:832–833