

Are your **MRI contrast agents** cost-effective?

Learn more about generic **Gadolinium-Based Contrast Agents**.



FRESENIUS  
KABI

caring for life

**AJNR**

**Gas CT cisternography of trigeminal neuralgia caused by AVM of the cerebellopontine angle.**

H Kawano, M Hayashi, H Kobayashi, T Tsuji, M Kabuto and T Kubota

*AJNR Am J Neuroradiol* 1987, 8 (1) 161-162

<http://www.ajnr.org/content/8/1/161.citation>

This information is current as of April 23, 2024.

## Gas CT Cisternography of Trigeminal Neuralgia Caused by AVM of the Cerebellopontine Angle

Hirokazu Kawano,<sup>1</sup> Minoru Hayashi,<sup>1</sup> Hidenori Kobayashi,<sup>1</sup> Tetsuro Tsuji,<sup>1</sup> Masanori Kabuto,<sup>1</sup> and Toshihiko Kubota<sup>2</sup>

Recently, percutaneous thermocoagulation [1–3] or retrogasserian glycerol rhizotomy [4, 5] has been used in the treatment of tic douloureux. In a few unsuccessful cases, lesions such as multiple sclerosis, tumors of the cerebellopontine angle, arteriovenous malformation (AVM), or aneurysm of the vertebrobasilar artery system have been reported as the causative factors [5]. Among these, AVM is rare. This report describes the usefulness of gas-contrast CT (gas CT) cisternography in a case of failure of retrogasserian glycerol rhizotomy.

### Case Report

During 1980 and 1982, a 48-year-old man had severe right facial pain for a month, with intermittent pain-free periods. Pain was alleviated by medication. In 1984, right facial neuralgia recurred.

The patient had right second- and third-division neuralgia on admission, with no other neurologic abnormality. On CT scan, a small enhancing lesion was noticed at the right superior petrosal sinus (Fig. 1).

The patient received percutaneous retrogasserian glycerol rhizotomy twice, with an intervening interval of 1 week, but the pain was not relieved. Gas CT cisternography using 10 ml O<sub>2</sub> was performed to determine the relation between the fifth nerve and the surrounding structures. This disclosed a network-like structure in the cerebellopontine angle; however, the fifth nerve and petrosal vein were not seen (Fig. 2). Vertebral angiography revealed an AVM in the cerebellopontine angle, supplied by the anterior inferior cerebellar artery, the enlarged internal auditory artery, and the superior cerebellar artery. The AVM drained into the superior petrosal sinus through the petrosal vein (Fig. 3).

At surgery, either the nidus of the AVM or the enlarged petrosal vein were observed compressing and coiling the fifth nerve root. The

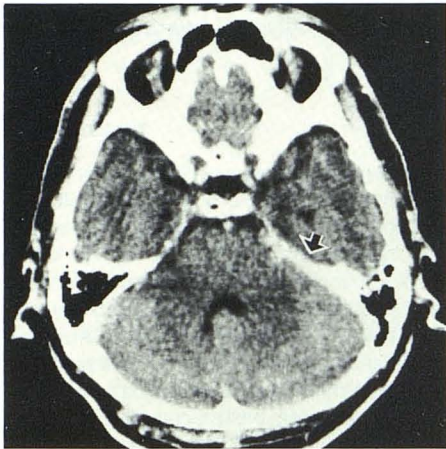


Fig. 1.—CT scan with contrast infusion showing slightly enhanced lesion (arrow) at right superior petrosal sinus.

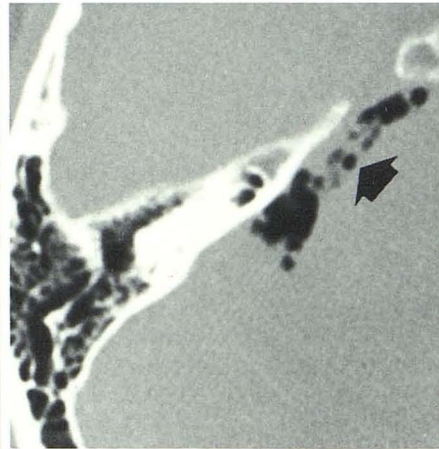


Fig. 2.—Gas CT cisternography showing network-like structure (arrow) in right cerebellopontine angle.

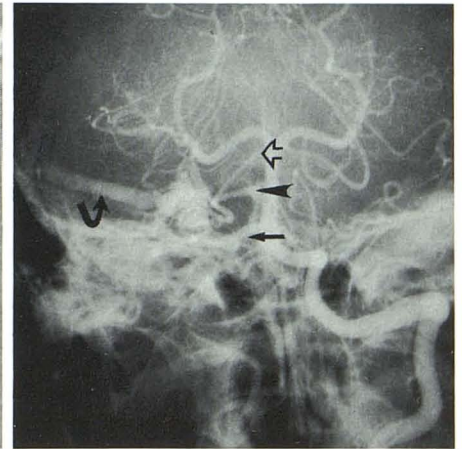


Fig. 3.—Left vertebral angiography showing arteriovenous malformation supplied by superior cerebellar artery (open arrow), internal auditory artery (arrowhead), and anterior inferior cerebellar artery (straight arrow) that drained into superior petrosal sinus (curved arrow).

Received December 19, 1984; accepted after revision April 9, 1985.

<sup>1</sup> Department of Neurosurgery, Fukui Medical School, Matsuoka, Yoshida-gun, Fukui 910-11, Japan. Address reprint requests to H. Kawano.

<sup>2</sup> Department of Neurosurgery, School of Medicine, Kanazawa University, Kanazawa, Japan.

patient was completely relieved of neuralgia after resection of the AVM.

### Discussion

The underlying mechanism responsible for trigeminal neuralgia is obscure, although several causative factors are suspected [6]. Recently, Jannetta [7] reported that trigeminal neuralgia may be an entrapment syndrome (i.e., a consequence of arteriosclerotic elongation, or rarely, of congenital abnormalities of branches of the superior cerebellar artery, with compression and distortion of the trigeminal rootlets in the vicinity of their entrance into the pons. On the basis of these observations, Jannetta suggested that microvascular surgery with decompression is of therapeutic value in treating the neuralgia.

On the other hand, percutaneous trigeminal nerve rhizotomies, such as thermocoagulation [1–3] and retrogasserian glycerol injection [4], have been reported as effective methods in the treatment of trigeminal neuralgia. Lunsford and Bennett [5] reported cases in which glycerol rhizotomy was not effective in patients with multiple sclerosis, aneurysms, AVMs, and tumors of the cerebellopontine angle and middle temporal fossa. Among these, AVM is a rare cause of the trigeminal neuralgia. Jannetta [7] reported only one example in his series of 414 cases, and Lunsford and Bennett [5] reported two AVMs in their 112 cases.

We suggest that trigeminal neuralgia caused by AVM should be treated by resection, not only for the prevention of hemorrhage but also for pain relief.

It may be difficult to rule out preoperatively symptomatic neuralgia due to a small AVM without mass effect by conventional CT scan. Kricheff et al. [8] and Clark et al. [9] recommended the use of CO<sub>2</sub> contrast CT cisternography to detect

small and intracanalicular acoustic tumors. We used the same technique with O<sub>2</sub> in the present case of trigeminal neuralgia, which was not alleviated by glycerol rhizotomy. We suggest that gas CT cisternography is a safe and convenient method for detecting trigeminal neuralgia caused by AVM and other vascular abnormalities.

### REFERENCES

1. Siegfried J. 500 percutaneous thermocoagulations of the gasserian ganglion for trigeminal pain. *Surg Neurol* **1984**;8:126–131
2. Sweet WH, Wepsic JG. Controlled thermocoagulation of trigeminal ganglion and rootlets for differential destruction of pain fibers. Part 1. Trigeminal neuralgia. *J Neurosurg* **1974**;39:143–156
3. Tew JM Jr. Treatment of trigeminal neuralgia by percutaneous rhizotomy. In: Youmans JR, ed. *Neurological surgery*. Philadelphia: Saunders, **1982**:3564–3579
4. Hakanson S. Trigeminal neuralgia treated by the injection of glycerol into the trigeminal cistern. *Neurosurgery* **1981**;9:638–645
5. Lunsford LC, Bennett MH. Percutaneous retrogasserian glycerol rhizotomy for tic douloureux. Part 1. Technique and result in 112 patients. *Neurosurgery* **1984**;14:424–435
6. Bayer DB, Stenger TG. Trigeminal neuralgia: an overview. *Oral Surg* **1979**;48:393–399
7. Jannetta PJ. Vascular decompression in trigeminal neuralgia. In: Saito M, Jannetta PJ, eds. *The cranial nerves*. Berlin: Springer-Verlag, **1981**:331–340
8. Kricheff II, Pinto RS, Bergeron RT, Cohen N. Air-CT cisternography and canalography for small acoustic neuromas. *AJNR* **1980**;1:57–63
9. Clark WC, Acker JD, Robertson JH, Gardner G, Dusseau JJ, Moretz W. Neuroradiological detection of small and intracanalicular acoustic tumors: an emphasis on CO<sub>2</sub> contrast enhanced computed tomographic cisternography. *Neurosurgery* **1982**;6:733–736