

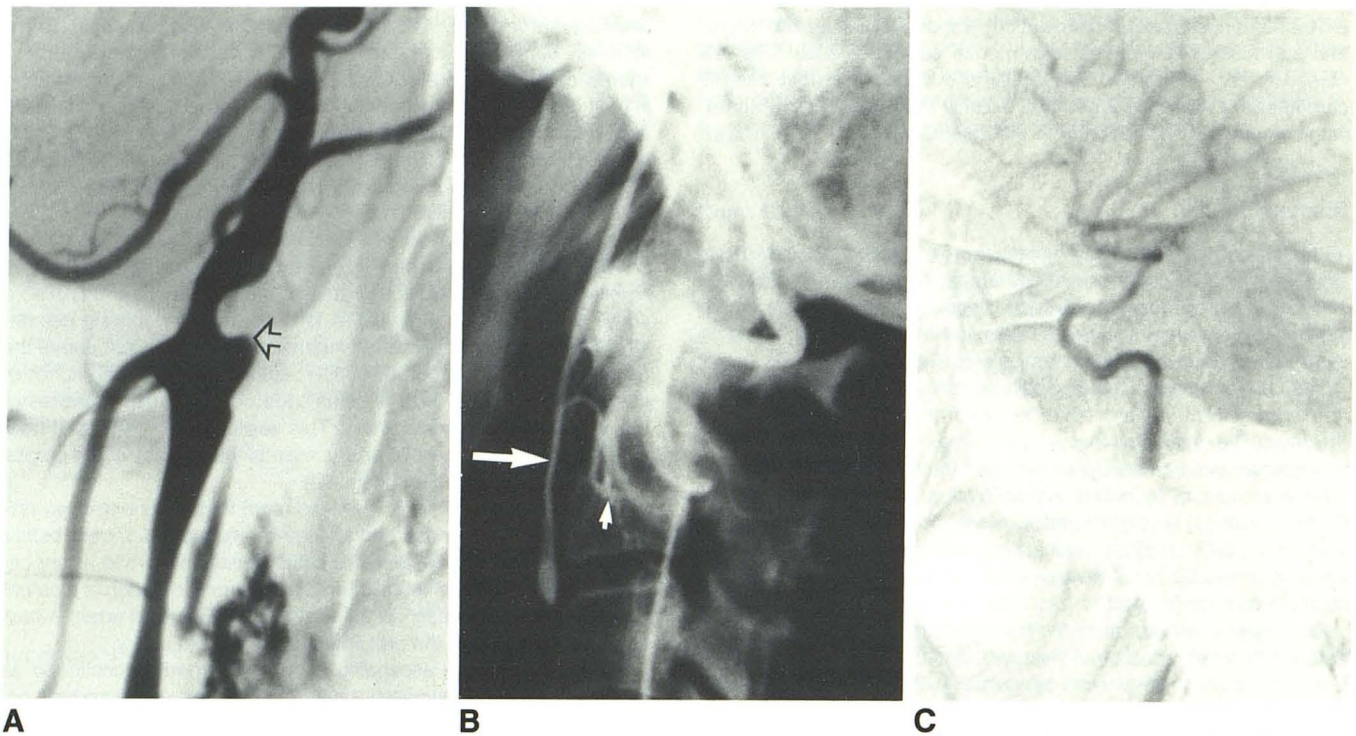Fig. 1.—A, Case 1. Lateral left common carotid arteriogram shows complete occlusion of left internal carotid artery at its origin (arrow). B, Lateral left vertebral arteriogram. Muscular collaterals from vertebral artery anastomose with muscular branches of ascending pharyngeal artery (small arrow). There is reconstitution of left internal carotid artery (large arrow) via ascending pharyngeal artery. C, A late film in the series shows patency of intracranial portion of left internal carotid artery.

and brain. Vol 2. St. Louis: Mosby, 1974:1254–1258

2. Djindjian R, Merland JJ. Normal super-selective arteriography of the external carotid artery. In: *Super-selective arteriography of the external carotid artery*, 1st ed. Heidelberg: Springer-Verlag, 1978:14–17
3. Lasjaunias P, Moret J. The ascending pharyngeal artery: normal and pathological radioanatomy. *Neuroradiology* 1976;11:77–82
4. Lasjaunias P. The pharyngo-occipital collateral pattern. In: *Craniofacial and upper cervical arteries. Collateral circulation and angiographic protocols*. Baltimore: Williams & Wilkins, 1983: 55–64

MR Imaging of Moyamoya in Neurofibromatosis

Intracranial arterial occlusions in patients with neurofibromatosis have been well described in the literature [1–4]. We describe the MR imaging appearance of moyamoya changes in a patient with carotid occlusive disease due to neurofibromatosis.

Case Report

A 4-year-old black girl was admitted to the hospital in 1981 with a history of dragging of the left arm and leg since the morning of admission. Neurologic examination confirmed a moderate left hemiparesis. The child and her mother both had multiple large cafe-au-lait spots. CT showed an area of decreased attenuation in the right basal ganglia with abnormal enhancement. Cerebral angiography was performed during this hospital admission. Gradual improvement of the patient's left hemiparesis occurred. The patient was readmitted at

age 5, again with a 2-day history of gradually progressing left-sided weakness. CT scan showed multiple focal infarcts in both cerebral hemispheres. One month later, gradually increasing right-sided weakness and an expressive aphasia developed. An MR study was obtained 4 years after her last stroke.

Discussion

Primary cerebral arterial stenotic and occlusive disease is a well-known but relatively infrequent manifestation of neurofibromatosis. The typical angiographic findings consist of smooth constricting lesions and/or occlusions involving the supraclinoid internal carotid arteries and proximal arterial segments of the circle of Willis. The collateral circulation, which consequently develops, is provided by corticocortical-end artery anastomotic pathways, transdural external-internal carotid communications, and proliferation and hypertrophy of deep perforating vessels in the basal ganglia and thalami. These latter vessels produce a telangiectatic collection of small capillary and arterial vessels at the base of the brain, which has been described as having a moyamoya or misty or hazy appearance [5, 6]. This constellation of angiographic findings was originally described as moyamoya disease in children and young adults of Japanese origin. A moyamoya pattern of vascular changes has since become recognized, however, in a wide variety of patients with cerebral arterial occlusions at a young age, including patients with meningitis, sickle-cell disease, neurofibromatosis, and other neurocutaneous syndromes.

In the present case, carotid angiography revealed smooth stenosis of the supraclinoid segment of the right internal carotid and high-

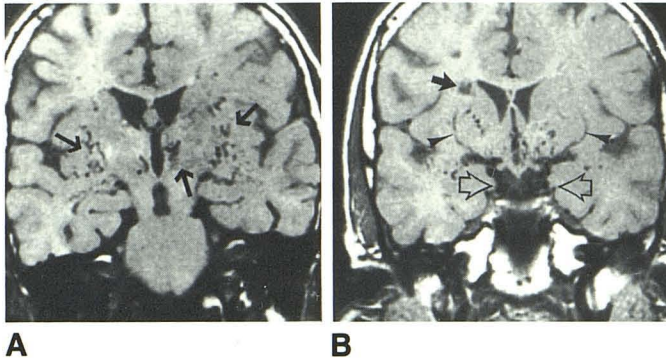


Fig. 1.—Coronal MR in neurofibromatosis with cerebral arterial occlusive disease. (1.5 T, partial saturation pulse sequence, TR = 800 msec, TE = 25 msec.)

A, Coronal section at level of foramen of Monro. There are enlarged serpiginous moyamoya vessels within basal ganglia and thalamus (arrows).

B, Coronal section at level of optic chiasm and origin of optic tracts. There is infarct adjacent to right frontal horn (solid arrow). Multiple coiled collateral vessels are seen adjacent to medial surfaces of temporal lobes (open arrows) and in basal ganglia. Note lenticulostriate arteries (arrowheads).

grade stenosis of the proximal segment of the right middle cerebral artery. There was also near occlusion of the proximal portion of the left middle cerebral artery and a mild stenosis of the proximal segment of the left anterior cerebral artery. Development of collateral circulation produced a moyamoya appearance at the base of the brain.

MR performed on the patient demonstrated these markedly hypertrophied thalamo-perforating arteries forming large coiled channels

in the basal ganglia and thalamus. With T1-weighted images (Fig. 1), these vessels were seen as tortuous hypointense signals (flow-void sign) in the same location that was shown angiographically.

This case demonstrates the usefulness of MR in the evaluation of patients with an onset of neurologic symptoms suggesting cerebrovascular compromise and as an aid in the assessment of the need for more invasive neuroradiologic procedures.

Betty Sue Brooks
 Taher El Gammal
 Robert J. Adams
 Patricia L. Hartlage
 W. Barry Smith
 Medical College of Georgia
 Augusta, GA 30912

REFERENCES

1. Hilal Sk, Solomon GE, Gold AP, Carter S. Primary cerebral arterial occlusive disease in children II. Neurocutaneous syndromes. *Radiology* 1971;99:87-94
2. Klatte EC, Franken EA, Smith JA. The radiographic spectrum in neurofibromatosis. *Semin Roentgenol* 1976;11:17-33
3. Tomsick TA, Lukin RP, Chambers AA, Benton C. Neurofibromatosis and intracranial arterial occlusive disease. *Neuroradiology* 1976;11:229-234
4. Leone RG, Schatzki SC, Wolpov ER. Neurofibromatosis with extensive intracranial arterial occlusive disease. *AJNR* 1982;3:572-576
5. Taveras JM. Multiple progressive intracranial arterial occlusions: a syndrome of children and young adults; Caldwell lecture, 1968. *AJR* 1969;106:235-268
6. Suzuki J, Takaku A. Cerebrovascular "moyamoya" disease. Disease showing abnormal net-like vessels in base of brain. *Arch Neurol* 1969;20:288-299