

Are your MRI contrast agents cost-effective?

Learn more about generic Gadolinium-Based Contrast Agents.



**FRESENIUS
KABI**

caring for life

AJNR

**Evaluation of traumatic atlantooccipital
dislocations.**

C Lee, J H Woodring, S J Goldstein, T L Daniel, A B Young and
P A Tibbs

AJNR Am J Neuroradiol 1987, 8 (1) 19-26

<http://www.ajnr.org/content/8/1/19>

This information is current as
of April 19, 2024.

Evaluation of Traumatic Atlantooccipital Dislocations

Charles Lee¹
 John H. Woodring¹
 Steven J. Goldstein¹
 Terri L. Daniel¹
 A. Byron Young²
 Philip A. Tibbs²

The diagnosis of traumatic atlantooccipital dislocation (AOD) from the cross-table lateral radiograph is difficult because of problems in demonstrating the complex anatomy of this area and the intricate radiographic methods used to diagnose AOD. Although CT or polytomography seem to be the most accurate diagnostic methods, it is often the lateral radiograph from which the diagnosis and further decisions are made. To determine both the best radiographic method for diagnosing AOD from the lateral radiograph and the role of CT and tomography in the diagnosis of AOD, the literature was reviewed concerning how the diagnosis of AOD has been obtained. In addition, the Wholey dens-basion line, the Powers ratio, the Dublin method of diagnosing AOD, and measurement of the atlantooccipital joint width were applied to 12 cases of traumatic AOD; and the Wholey dens-basion line and the Powers ratio were determined in 100 normal adults and 50 normal children. An alternative plain radiographic method for diagnosing AOD was developed, called the X-line method. This was the most accurate of the methods tested, correctly diagnosing AOD in 75% of cases. The Wholey dens-basion line and direct measurement of the atlantooccipital joint width were each correct in 50% of cases, the Powers ratio in 33% of cases, and the Dublin method in only 25% of cases. Ultimately, either CT or polytomography should provide the definitive diagnosis. In this regard high-resolution CT with reformatted coronal and sagittal images generated from 2-mm thin axial slices appeared to have the most promise as the first study of choice.

Traumatic atlantooccipital dislocation (AOD) is a difficult radiographic diagnosis to make because the current diagnostic methods are complex and tedious [1-3], and the overall experience with AOD is quite limited [2-17]. Because survival has been reported, even with complete neurologic recovery, it is important to be able to establish an early diagnosis of AOD. It is often the cross-table lateral radiograph from which the initial diagnosis must be made.

Our primary purpose was to determine a reliable method for diagnosing AOD from the lateral radiograph; our secondary purpose was to determine the role of CT and polytomography in the diagnosis of AOD. The radiographic descriptions of traumatic AOD [2-17] were reviewed, and the diagnostic methods of others [1-4] were applied to 12 cases of traumatic AOD. A new radiographic method, the X- or occipital-axial lines method, was introduced.

Materials and Methods

We reviewed 12 examples of traumatic AOD applying five radiographic methods: the Wholey dens-basion line [1], the Powers et al. ratio [2], the Dublin et al. method [3], our X-line method, and direct measurement of the width of the atlantooccipital joint [4]. Wholey et al. considered 5 mm to be average and 10 mm to be the upper limit of normal for the dens-basion line. Since they did not provide a range of normal values, we measured the dens-basion line in 100 adults and 50 children radiographed in the emergency room. All measurements were performed on cross-table lateral radiographs with their inherent problem of magnification, flexion and extension, and rotation of the spine. This way a range of normal values for the dens-basion line could be established that reflected similar conditions under

Received April 11, 1986; accepted after revision July 15, 1986.

Presented at the annual meeting of the American Roentgen Ray Society, Boston, April 1985, and in part at the annual meeting of the American Society of Neuroradiology, San Diego, January 1986.

¹Department of Diagnostic Radiology, A. B. Chandler Medical Center, University of Kentucky, Lexington, KY 40536-0084. Address reprint requests to C. Lee.

²Department of Neurosurgery, A. B. Chandler Medical Center, University of Kentucky, Lexington, KY 40536-0084.

AJNR 8:19-26, January/February 1987

0195-6108/87/0801-0019

© American Society of Neuroradiology

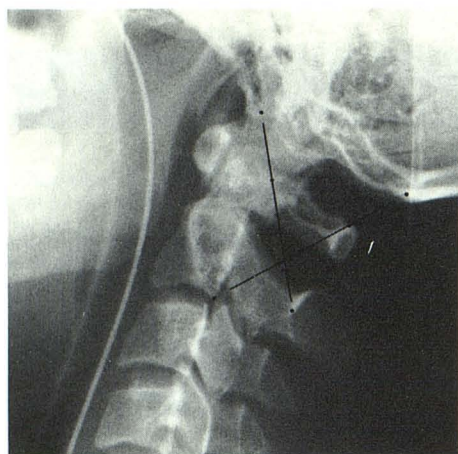


Fig. 1.—Normal lateral cervical radiograph with X lines applied. BC2SI line is drawn from tip of basion (B) to midpoint of C2 spinolaminar line (SI). This line just intersects with posterosuperior margin of dens. The C2O line is drawn from posteroinferior corner of body of C2 to tip of opisthion (O). This line just intersects with highest point of C1 spinolaminar line.

which the 12 cases of AOD had been radiographed.

Similarly, normal ranges for the Powers ratio were obtained for the normal adults and children. Because many of the radiographs in the normal population were obtained at less than 72 inches (183 cm) the Dublin et al. method was not applied to the normals, since radiographic magnification affects this measurement.

We developed a new method for diagnosing AOD that we referred to as the X-line or occipital-axial lines method (Fig. 1). A pair of lines, the BC2SI and the C2O lines, were constructed on the cross-table lateral radiograph. The first line was drawn from the tip of the basion to a point midway on the C2 spinolaminar line. This line should just intersect tangentially with the posterosuperior aspect of the dens. The second line was drawn from the posteroinferior corner of the body of C2 to the tip of the opisthion. This line should just intersect tangentially with the highest point on the C1 spinolaminar line. These lines were also applied to the normal population.

A direct measurement of the atlantooccipital joint width from the lateral radiographs was made in the 12 cases of AOD. There was no correction for radiographic magnification. Prevertebral soft-tissue swelling was measured in the 12 cases of AOD at the antero-inferior corner of C2. We defined 15 mm as the upper limit of normal, 16–20 mm as soft-tissue swelling, and 20 mm or more as marked swelling.

Results

There were five examples of the posterior form of AOD, four examples of the longitudinal form, two of the anterior form, and one of the rotatory form. Adult ages ranged from 18–38 years and children from 1–12 years. Eight patients died within 48 hr after admission and four survived, of whom one completely recovered neurologically, one had residual bilateral sixth-nerve palsies, one had a residual left hemiparesis, and one remained quadriparetic and respirator-dependent (Tables 1 and 2).

The measurements obtained from each method are sum-

marized in Tables 1 and 2. The abilities of each method to diagnose AOD correctly are compared in Table 3.

Wholey Dens-Basion Line Method

The dens-basion line measured 2–15 mm in adults (average, 7.5 mm) and 2–11 mm in children (average, 5 mm) uncorrected for magnification. On the basis of our normal population, measurements greater than 15 mm in adults and 12 mm in children were considered abnormal and highly suggestive of AOD (Figs. 2–4).

With these criteria we found three of the six adults and three of the six children to have abnormal measurements (Table 3) and thus likely to have AOD. In two of the children the initial measurements were normal so we considered them to be negative for AOD, even though after cervical traction was applied the dens-basion lines became abnormal. Most of the cases that were abnormal using the Wholey method were of the longitudinal form of AOD.

We did not find the dens-basion-line method to be reliable because of the overlap between normal and abnormal values. This reflects the views of others [2, 3, 11]. However, if the Powers et al. criterion of 9 mm as the upper limit of normal were used, 10 of 12 cases would have been considered abnormal. If this value were used, however, 31 of our normal 100 adults would have been diagnosed as having AOD.

Powers Ratio

The ratio in the normal adult population was 0.65–0.90 (average, 0.74) (Fig. 2), agreeing with the values observed by Powers et al. of 0.50–0.98 (average, 0.77). Values exceeding 1.0 were abnormal and diagnostic of the anterior form of AOD [2]. The ratio was not calculated in the normal children because it was difficult to identify the opisthion reliably.

The Powers ratio was less successful in diagnosing AOD, being abnormal in four of the six adults, but unable to diagnose AOD in all six children. Kaufman et al. [4] also pointed out the limitation of the Powers ratio among children.

The Powers ratio was abnormal in two cases of anterior AOD (Fig. 3), in one case of posterior AOD (Table 1), and in one case of longitudinal AOD (Fig. 4). In one of the two cases of anterior AOD and in both of the latter cases, there was a component of longitudinal distraction with the respective dens-basion lines measuring 26, 15, and 29 mm.

Although it would appear that the Powers ratio can diagnose the longitudinal form of AOD, in two children with longitudinal AOD and respective dens-basion lines measuring 23 and 25 mm, the Powers ratio failed, giving a false-negative diagnosis. Therefore, we did not find the Powers ratio to be useful in children, but it was reliable in diagnosing the anterior form of AOD in adults.

Dublin Method

Because of the stringent requirements under which the radiographs must be taken, the Dublin method was the least

TABLE 1: Results of Measurements by Various Methods in Evaluating Atlantooccipital Dislocation

Case No.	Type of AOD	Dens-Basion [1]	Powers Ratio [2]	Dublin [3]	AO Joint Width
1	Posterior	6 mm 12 mm 15 mm	45/52 (0.81) 40/63 (0.64) 50/57 (1.06)	A, -2; B, -3	NA
2	Posterior	10 mm	36/52 (0.69)	A, -5; B, -4	6 mm
3	Anterior and longitudinal	26 mm	63/44 (1.43)	A, 15; B, 22	13 mm
4	Longitudinal	29 mm 28 mm 24 mm	51/39 (1.31) 47/44 (1.07) 52/42 (1.23)	A, 5; B, 9	12 mm
5	Anterior	19 mm 12 mm	48/36 (1.33) 37/39 (0.95)	A, 14; B, 24	NA
6	Rotatory	8 mm	37/52 (0.71)	NA	NA
7	Posterior	25 mm	48/56 (0.86)	A, -6; B, 8	8 mm
8	Posterior	9 mm	42/51 (0.82)	A, 7; B, 15	NA
9	Longitudinal	23 mm	42/43 (0.98)	A, 4; B, 11	12 mm
10	Posterior	12 mm 17 mm	36/52 (0.69) 37/40 (0.93)	A, 2; B, 9	7 mm
11	Longitudinal	11 mm 15 mm	36/44 (0.82) 35/37 (0.95)	A, 4; B, 8	4 mm
12	Longitudinal	15 mm	40/52 (0.95)	A, 15; B, 22	6 mm

Note.—AOD = atlantooccipital dislocation; NA = not able to measure joint width because it was obscured by mastoids. AOD in cases 7–12 was in children 12 years old or younger.

TABLE 2: Results of X-Line Method, Prevertebral Soft-Tissue Swelling, and Clinical Correlation in Atlantooccipital Dislocation

Case No.	BC2SI Line	C2O	PV Swelling	Clinical Findings
1	2 mm behind dens 12 mm behind dens	Perfect 5 mm behind C1 spinolaminar line	12 mm	Unresponsive, flaccid, no respiration, skull fracture, cardiac tamponade, death
2	Perfect 5 mm behind dens	Perfect 5 mm behind C1 spinolaminar line	6 mm	Unresponsive, flaccid, no respiration, death
3	2 mm in front of dens	15 mm in front of C1 spinolaminar line	19 mm	Unresponsive, flaccid, no respiration, death
4	1 mm behind dens	5 mm in front of C1 spinolaminar line	20 mm	Unresponsive, flaccid, no respiration, death
5	3 mm in front of dens	3 mm in front of C1 spinolaminar line	30 mm	Initially intact, then central cord quadriplegia; respirator-dependent
6	Perfect NA	Perfect NA	6 mm	Transitory quadriplegia and LOC; neurologically intact
7	5 mm behind dens	3 mm behind C1 spinolaminar line	5 mm	Unresponsive, flaccid, no respiration, death
8	3 mm behind dens	4 mm behind C1 spinolaminar line	9 mm	Unresponsive, flaccid, no respiration, death
9	3 mm behind dens	3 mm in front of C1 spinolaminar line	11 mm	Unresponsive, flaccid, no respiration, death
10	4 mm behind dens Perfect	3 mm in front of C1 spinolaminar line 1 mm in front of C1 spinolaminar line	5 mm	Unresponsive, flaccid, no respiration, death
11	4 mm behind dens 7 mm behind dens	Perfect Perfect	7 mm	Fixed, dilated pupils, unresponsive, but survived with residual left hemiparesis
12	4 mm behind dens	Perfect	16 mm	Transient flaccid quadriplegia; nearly complete recovery with residual bilateral sixth nerve palsies

Note.—The BC2SI line is from the tip of the basion to a point midway to the spinolaminar line. The C2O line is from the posteroinferior corner of the body of C2 to the very tip of the opisthion. PV = prevertebral; LOC = loss of consciousness. The patients in cases 7–12 were younger than 12 years of age. "Perfect" refers to lines aligning perfectly with their respective anatomic reference points.

TABLE 3: Comparison of Each of the Radiographic Methods in Correctly Diagnosing Traumatic Atlantooccipital Dislocation

Case No.	Dens-Basion [1]	Powers [2]	Dublin [3]	AO Joint	X Lines
1	—	+	—	+	+
2	—	—	—	+	+
3	+	+	+	+	+
4	+	+	—	+	+
5	+	+	+	NA	+
6	—	—	—	NA	NA ^a
7	+	—	—	—	+
8	—	—	—	NA	+
9	+	—	—	+	+
10	—	—	—	+	+
11	—	—	—	—	—
12	+	—	+	—	—
Total no. of correct diagnoses	6	4	3	6	9

Note.—AO = atlantooccipital; NA = unable to measure atlantooccipital joint; + = positive for diagnosis of atlantooccipital dislocation; — = negative for diagnosis of atlantooccipital dislocation.

^a Rotatory dislocation at the C1/C2 level as well as the atlantooccipital dislocation makes this method invalid.

successful, indicating a correct diagnosis in only three of the 12 cases (Tables 1 and 3). Five of the 12 cases were radiographed at less than a 72-inch (183-cm) tube-to-film distance. Rotation of the spine and mandible and radiographic magnification no doubt contributed to the poor performance of this method. We did not find the Dublin method to be helpful, but it may be so if the stringent requirements for radiography are met.

X-Line Method

In the normal adults the ideal X-line pattern occurred when both lines, BC2SI and C2O, just intersected with their respective anatomic reference points. This occurred in 28% of the normals. The more common pattern, occurring in 58%, was when the BC2SI line fell behind or (less often) in front of the posterosuperior cortex of the dens (but never more than 5 mm uncorrected) while the C2O line was perfectly aligned with the highest point of the C1 spinolaminar line. The least common pattern, occurring in 14%, was when the BC2SI line was perfectly aligned while the C2O line was not.

In the normal adults the C2O line was a more reliable landmark, since in 84% of the normals it was properly aligned with its reference point (Fig. 5A). In contrast, the BC2SI line was properly aligned in only 42% of the normals (Fig. 5B). More important, one or both of the lines should be properly aligned with their reference points. If *both* lines are displaced then the diagnosis of AOD should be considered strongly. However, in three of the normals both lines were posteriorly displaced suggesting the posterior form of AOD. Thin-slice reformatted sagittal and coronal CT demonstrated normal atlantooccipital joints in all three cases. In all three cases the head was hyperextended on the lateral radiograph, which may have caused the lines to be displaced.

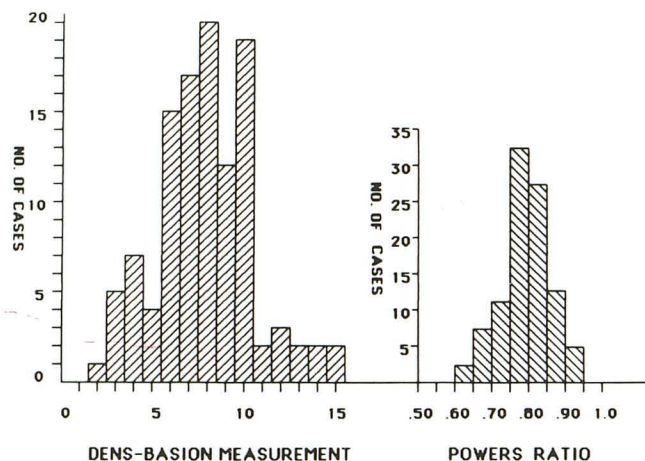


Fig. 2.—Results of dens-basion line and Powers ratio calculations in 100 normal adults.

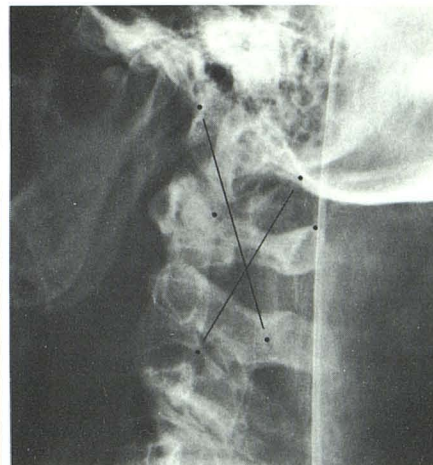
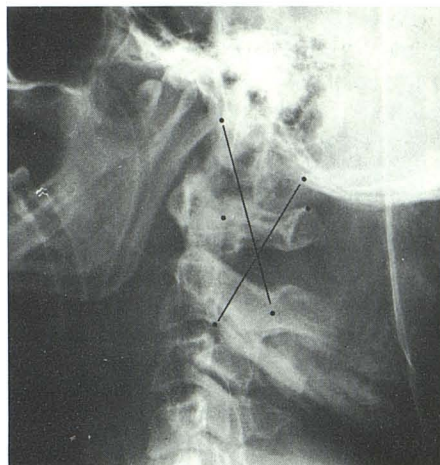
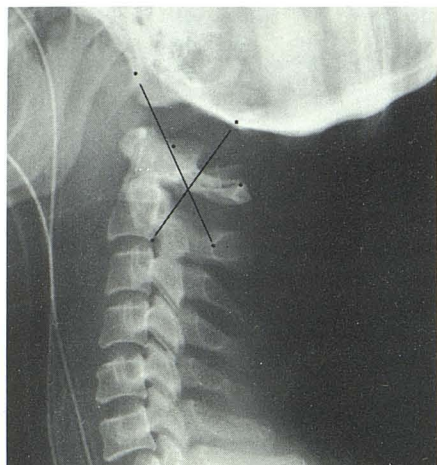
There were three patterns of displacement of the X lines in AOD: anterior, posterior, and longitudinal. With anterior AOD both limbs of the X were displaced anteriorly away from their reference points (Figs. 3 and 6A). In posterior dislocation both limbs of the X were displaced posteriorly (Figs. 6A and 7), and in the longitudinal form the X limbs were displaced paradoxically (Figs. 3, 4, and 8). The BC2SI line was displaced posteriorly, and the C2O line was displaced anteriorly. Alternatively, the X lines could be considered to be displaced superiorly away from their reference points.

The X-line method was the most successful in our review, correctly diagnosing five of six adults and four of six children as having AOD, as well as differentiating among the three forms of AOD. In the false-negative adult case, rotatory dislocation was present at both the atlantooccipital and atlantoaxial level, making the X-line method invalid. The X lines were based on a normal C1/C2 alignment, because a dens fracture or rheumatoid C1/C2 subluxation could mimic AOD. In the two children with false-negative results, one was 1 year old and the other was 5 years old. We found that in normal children 5 years old or younger, the X lines did not work and we did not expect it to work with the abnormal cases. However, in one 5-year-old child the X lines were clearly abnormal, indicating the longitudinal form of dislocation (Fig. 9). No doubt the marked degree of distraction (dens-basion line = 23 mm) contributed to the abnormal X lines. Therefore, we did not find the X-line method to be reliable in children 5 years old or younger.

Construction of the X lines did not present a problem as long as the radiographic technique was optimal. The opisthion was the most difficult landmark to identify consistently. Marked degrees of flexion and extension produced false positives, but the X lines appeared to work with lesser degrees of flexion and extension.

Measurement of the Atlantooccipital Joint

The maximum width of the atlantooccipital joint can be measured directly from the lateral radiograph. Kaufman et al.



A

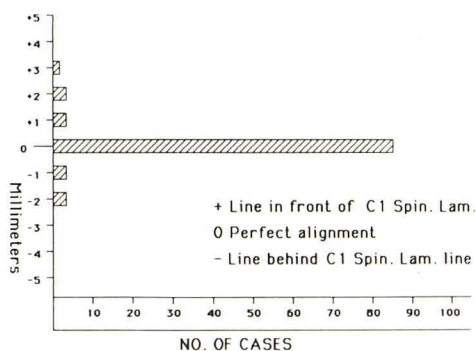
B

Fig. 3.—Case 3, 24-year-old man with anterior form of atlantooccipital dislocation with considerable longitudinal component as a result of motor vehicle accident. Tip of clivus points to anterior arch of C1 rather than to dens. Both limbs of X are displaced anteriorly. Because of longitudinal component, occipital condyles and condylar fossae have a “bare” or “naked” appearance. Marked degree of prevertebral soft-tissue swelling.


Fig. 4.—Case 4, 25-year-old woman who had been in motor vehicle accident. A, X lines are paradoxically displaced indicating longitudinal form of atlantooccipital dislocation. B, After application of cervical traction. Not only was dens-basion line increased from 24 to 29 mm, but X lines were further displaced upward.

Fig. 5.—A, Graph depicting location of C2O line (C2-opisthion) relative to highest point of C1 spinolaminar line. In 86% of 100 normal adults, the C2O line was perfectly aligned with its reference point, making it a more reliable indicator of a normal joint than the BC2SI line (basion-C2 spinolaminar).

B, Graph depicting location of BC2SI line relative to dens in 100 normal adults.



A



B

Fig. 6.—A, Pattern of displacement of X lines in anterior form of atlantooccipital dislocation. Both limbs of X are displaced forward away from their reference points.

B, Posterior form of atlantooccipital dislocation. Both limbs of X are displaced posteriorly.



A



B

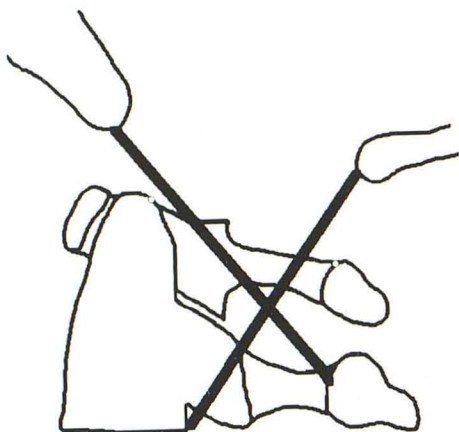
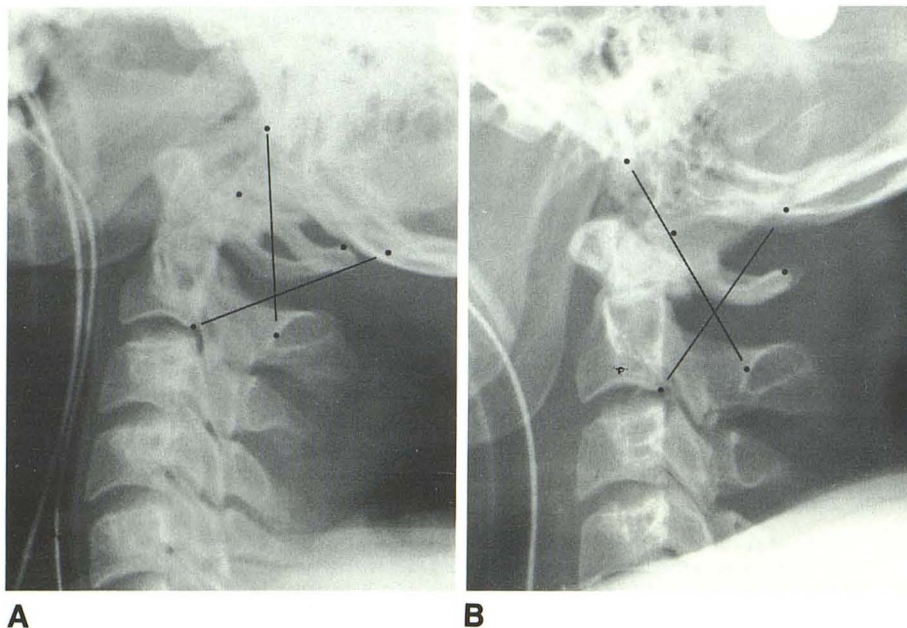


Fig. 8.—Longitudinal form of atlantooccipital dislocation. There is paradoxical displacement of X lines. BC2SI line (basion–C2 spinolaminar line) is displaced posteriorly, and C2O line (C2–opisthion) is displaced anteriorly.

[4] believed that 5 mm was the average value in children, with the upper limit of normal being 10 mm. Due to superimposition of the mastoid tips over the atlantooccipital joints, demonstration of the joint was possible in only nine of our 12 cases. Using 10 mm as the upper limit of normal, we found five of the nine joints that we could measure to be abnormal (Tables 1 and 3). However, if 5 mm were used as the cutoff value, then eight of nine cases would have been considered abnormal.

Direct demonstration of the atlantooccipital joint was obtained by thin-section (2-mm) axial CT scans with reformatted coronal and sagittal images in two cases and by polytomography in another case. Abnormal widening of the joint was clearly seen on CT and tomography.

We found two cases with marked prevertebral soft-tissue

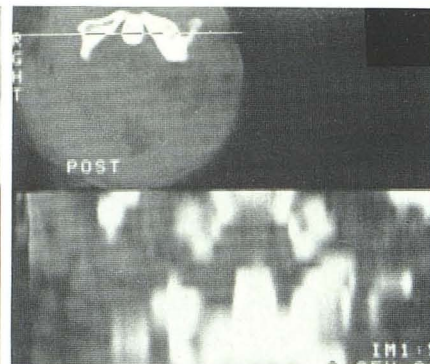


Fig. 7.—Case 1, 28-year-old man who had been in motor vehicle accident.

A, Tip of clivus (dotted) points well behind tip of dens, indicating posterior form of atlantooccipital dislocation. There is a congenital, bifid C1 posterior arch and therefore no spinolaminar line. The highest point of the expected spinolaminar line was approximated. Both limbs of X are displaced posteriorly. No significant prevertebral soft-tissue swelling.

B, After application of mild cervical traction. Dislocation appears to be reduced using X-line method.

C, Reformatted coronal CT scan immediately after B. Persistent widening of right atlantooccipital joint.

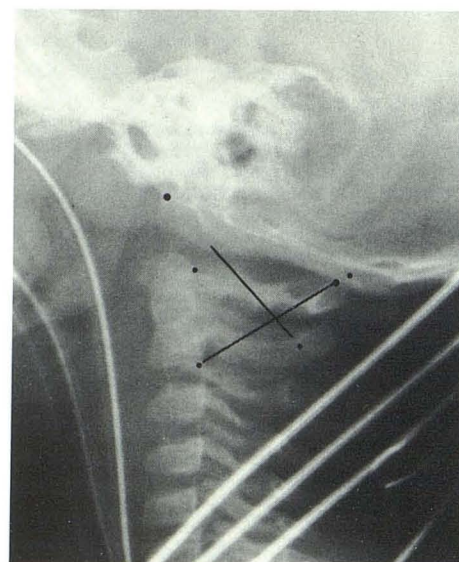


Fig. 9.—Case 11, 1-year-old boy who had been struck by a car. Although atlantooccipital joint appears widened on radiograph, joint width measured 4 mm, within normal limits. However, the dens-basion line was 15 mm, suggesting atlantooccipital dislocation. In this case, X lines gave a false-negative diagnosis. Diagnosis of dislocation was based more on clinical presentation than on radiographs.

swelling (Fig. 3), two cases with lesser degrees of swelling, and eight with no swelling. Therefore, the absence of prevertebral swelling does not rule out the presence of traumatic AOD.

Discussion

In our review of the literature and in our cases we found several radiographic findings that were helpful in establishing the diagnosis of AOD. One finding was the presence of a marked degree of prevertebral soft-tissue swelling (Fig. 3). Five cases have been reported with marked swelling, nine cases with less but still abnormal swelling, and two with no swelling [4–10]. Marked prevertebral soft-tissue swelling is highly suggestive of traumatic AOD. Another finding was a “bare” or “naked” appearance of the occipital condyles and condylar fossa (Fig. 3) [3–9, 11]. This appearance was caused by longitudinal distraction pulling the skull away from the cervical spine and exposing the condyles and fossae. It was most dramatic when considerable distraction was present. Another radiographic finding was perching of the occipital condyles on the anterosuperior margin of the C1 anterior arch [2, 3, 11, 18]. This occurred with the anterior form of AOD and was analogous to a bilateral facet lock.

Most of the diagnoses of AOD reported in the literature were based on the lateral radiograph of the cervical spine, with a few reports of CT and tomographic findings. From our review of the literature we found several approaches to obtaining the diagnosis of AOD from the lateral radiograph.

In the first approach, a normal atlantooccipital joint was determined on the lateral cervical radiograph by the relationships of certain anatomic structures to one another. Wholey et al. [1] stated that the “middle half of the upper end of the odontoid process normally lies directly beneath the basion, and on an average of 5 mm from it. In infants and young children, owing to incomplete bone growth, this distance may measure up to 1 cm.” Evarts [10] stated that the “tip of the odontoid process should point to the anterior lip of the foramen magnum in the mid-sagittal plane and should be just anterior (sic) to the anterior arch of the atlas. This relationship is constant in the cervical spine *during all movements*. With the head in neutral position, the odontoid process is directly beneath the basion and five millimeters from it on an average.” Christenson [19] provided a similar view: “Correct alignment of the cervical spine and the skull is confirmed when the extended line of the surface of the clivus intersects the odontoid process somewhere in its posterior third, and the curved spinolaminar line of C1 extended posteriorly and superiorly meets the region of the posterior margin of the foramen magnum (opisthion).”

If the tip of the clivus points in front of or behind the dens, then either the anterior or posterior form of AOD may be present. A similar analogy may be drawn with the constructed C1 spinolaminar line, although it may be difficult to construct the curved line.

Another approach was direct demonstration of the atlantooccipital joint by CT, tomography, and (less successfully) plain radiography. Here the experience was quite limited, mainly to tomography. Abnormal widening of the joint or dislocation of the condyle out of the fossa provided the definitive diagnosis of AOD. In one of our cases, reformatted sagittal and coronal CT views demonstrated AOD when plain radiographic methods showed no evidence of dislocation (Fig. 7C). With thin-section CT (2–3 mm) very good demonstration of the atlantooccipital joint can be obtained on reformatted

images. Also, since CT does not require manipulating the patient into a lateral position, it has the potential for being the definitive study and the first study of choice compared with tomography. Kaufman et al. [4] also used a direct approach in children, measuring the width of the atlantooccipital joint from the lateral radiograph. However, in adults the fully developed mastoid air cells often obscure the joint, preventing measurement.

The last approach was an indirect one and devised because of the difficulty in demonstrating the atlantooccipital joint on the lateral radiograph. Key anatomic landmarks with constant relationships to one another were identified on the radiograph. Lines were drawn between these reference landmarks, and measurements and ratio calculations were also performed. This includes the Wholey et al. method, the Powers et al. ratio, the Dublin et al. method, and our X-line method. The basion and opisthion indirectly reflect the location of the occipital condyles; and the C1 anterior arch, dens, C1 and C2 spinolaminar lines, and ramus of the mandible indirectly reflect the location of the condylar fossa. If these normal relationships were disrupted or if the measurements exceeded certain values, then AOD was present.

The opisthion may be the most difficult structure to identify on the lateral radiograph when using these indirect methods. Nance et al. [20] were able to identify the opisthion in 84% of 50 cervical radiographs, and the typical teardrop appearance was present in 56%. An underpenetrated radiographic technique and rotation and tilting of the head were responsible for failure to identify the opisthion in our normal cases. This limits the ability of the Powers et al. ratio and our X-line method. The opisthion was also more difficult to identify in children 5 years old or younger.

Our X lines were a modification of and a combination of the other plain radiographic methods, especially the Powers et al. ratio. When applied to the radiographs of the normal population, one of the X lines may not fall exactly on either the dens or the superior aspect of the C1 spinolaminar line, although the other line does. If one or both limbs of the X fall exactly on the above reference points, then most likely there is no AOD. When both limbs of the X were displaced away from their reference points then it was likely that AOD was present. Furthermore, the anterior, posterior, and longitudinal forms of AOD could be differentiated by our method. However, hyperextension of the head may produce false-positive diagnoses of AOD. Our series was too small to postulate the true efficacy of our X-line method over other radiographic methods. Nevertheless, we did find the X-line method to be helpful: it does not require measurements or ratio calculations and it identifies dislocation correctly more often than the other methods do (Table 3).

Although CT and tomography are superior to plain radiographs in identifying the atlantooccipital joint, in most situations it is the first cross-table lateral radiograph upon which all further decisions will be based, including the decision for other radiographic studies. The role of the cross-table lateral radiograph becomes even more important if CT or tomography is not routinely available.

With gross distraction of the skull, marked prevertebral soft-tissue swelling, a “bare” or “naked” occipital condyle, a “bare” condylar fossa, or anterior and superior perching of

the occipital condyles over the anterior arch of C1, the diagnosis of AOD is obvious on the lateral radiograph. With the lesser degrees of distraction it may be difficult to recognize AOD on plain radiographs. The indirect methods become useful if the atlantooccipital joint is not visible on the lateral radiograph.

In *adults* suspected of having traumatic AOD, we suggest first the use of the X lines on the lateral cervical radiograph if the opisthion can be identified. The dens-basion line is easy to measure and is helpful only if it is greater than 15 mm. The Powers et al. method was reliable for the anterior form of dislocation but not for the other forms of AOD. The definitive diagnostic tool should probably be either CT or tomography, if available.

In *children* suspected of having traumatic AOD we suggest the Kaufman et al. approach of measuring the width of the joint. The upper limit for normal should probably be 5 mm, although Kaufman et al. suggested 10 mm. In children younger than 5 years old, our X-line method does not work well. Again, the definitive diagnosis should probably be based on CT or tomography.

Serial changes were noted (Tables 1 and 2) in the measurements of several cases, especially after cervical traction was applied. In some cases no evidence of dislocation was present on one radiograph, but it was clearly present on another. The diagnosis of AOD may be overlooked if the entire series of radiographs is not reviewed. The changing measurements also point out the unstable nature of this injury.

REFERENCES

1. Wholey H, Bruwer AJ, Baker HL. The lateral roentgenogram of the neck. *Radiology* **1958**;71:350-356
2. Powers B, Miller MD, Kramer RS, Martinez S, Gehweiler JA. Traumatic anterior atlanto-occipital dislocation. *Neurosurgery* **1979**;4:12-17
3. Dublin AB, Marks WM, Weinstock D, Newton TH. Traumatic dislocation of the atlanto-occipital articulation (AOA) with short-term survival. *J Neurosurg* **1980**;52:541-546
4. Kaufman RA, Dunbar JS, Botsford JA, McLaurin RL. Traumatic longitudinal atlanto-occipital distraction injuries in children. *AJNR* **1982**;3:415-419
5. Fruin AH, Pirotte TP. Traumatic atlanto-occipital dislocation. Case report. *J Neurosurg* **1973**;39:394-397
6. Shapiro R, Youngberg AS, Rothman SLG. The differential diagnosis of traumatic lesions of the occipito-atlanto-axial segment. *Radiol Clin North Am* **1973**;11:505-526
7. Pang D, Wildberger JE. Traumatic atlanto-occipital dislocation with survival: case report and review. *Neurosurgery* **1980**;7:503-508
8. Eismont FJ, Bohlman HH. Posterior atlanto-occipital dislocation with fractures of the atlas and odontoid process. *J Bone Joint Surg [Am]* **1978**;60:397-399
9. Gabrielson TO, Maxwell JA. Traumatic atlanto-occipital dislocation with case report of a patient who survived. *Radiology* **1966**;97:624-629
10. Evarts CM. Traumatic occipital-atlantal dislocation. Report of a case with survival. *J Bone Joint Surg [Am]* **1970**;52:1653-1660
11. Grobovsek M, Scheibelbrandner W. Atlanto-occipital dislocation. *Neuroradiology* **1983**;25:173-174
12. Rockswold GL, Seeljeskog EL. Traumatic atlantocranial dislocation with survival. *Minn Med* **1979**;62:151-152
13. Farthing JW. Atlanto-cranial dislocation with survival. *NC Med J* **1948**;9:34-36
14. Woodring JH, Selke AC, Duff DE. Traumatic atlantooccipital dislocation with survival. *AJR* **1981**;137:21-24
15. Page CP, Story JL, Wissinger JP, Branch CL. Traumatic atlanto-occipital dislocation. Case report. *J Neurosurg* **1973**;39:394-397
16. Blackwood NJ. Atlanto-occipital dislocation. *Ann Surg* **1908**;47:654-658
17. Bohlman HH. Acute fractures and dislocations of the cervical spine. *J Bone Joint Surg [Am]* **1979**;61:1119-1142
18. Cone RO, Flournoy J, MacPherson RI. The craniocervical junction. *Radiographics* **1981**;1:1-38
19. Christenson PC. In: Sandrock AR, ed. The radiological study of the normal spine. Cervical, thoracic, lumbar, and sacral. *Radiol Clin North Am* **1977**;15:133-154
20. Nance EP, Lams P, Gerlock AJ. The opisthion on the lateral radiograph of the cervical spine. *AJR* **1979**;133:905-908