

Generic Contrast Agents

Our portfolio is growing to serve you better. Now you have a *choice*.



FRESENIUS
KABI

[VIEW CATALOG](#)

AJNR

Serial MR imaging in neonatal cerebral injury.

M A Johnson, J M Pennock, G M Bydder, L M Dubowitz, D J Thomas and I R Young

AJNR Am J Neuroradiol 1987, 8 (1) 83-92
<http://www.ajnr.org/content/8/1/83>

This information is current as
of May 11, 2025.

Serial MR Imaging in Neonatal Cerebral Injury

M. A. Johnson^{1,2}
J. M. Pennock¹
G. M. Bydder¹
L. M. S. Dubowitz³
D. J. Thomas⁴
I. R. Young⁵

The results of serial MR imaging of the brain in 32 patients with neonatal cerebral injury who had two or more examinations are reviewed. By comparison with normal age-matched controls, delayed or deficient myelination was identified in eight patients on follow-up examination. Developmental delay was present in all of these patients. In three patients delayed myelination was identified at the first study and was normal at follow-up. These patients improved clinically. The most severe delays or deficits in myelination and the most severe handicaps were present in patients with subcortical and periventricular leukomalacia. Ventricular size was readily assessed. Development of periventricular cysts at sites of previous hemorrhage and infarction was recognized. The lack of ionizing radiation is of particular importance in follow-up MR of children, and an increasing role for this technique in pediatric developmental neurology appears likely.

Although some MR studies in children with neonatal cerebral injury have been published, no large series has yet appeared and few serial studies have been reported [1–6]. We have now completed two or more examinations in 32 patients with neonatal cerebral injury and review the results of these studies below.

Subjects and Methods

Between December 1981 and May 1985, 10 normal children and 177 pediatric patients ranging in age from 32 weeks postmenstrual age (PMA) to 14 years were examined using MR. (The ages of children under 2 years were corrected for prematurity or postmaturity [2]). During this period, four normal children (three girls, one boy) and 58 patients (30 girls, 28 boys) had follow-up studies 2 weeks to 28 months after their initial study. Of these, 32 patients with neonatal cerebral injury (i.e., periventricular-intraventricular hemorrhage [PVH-IVH], hypoxic ischemic encephalopathy [HIE], subcortical and periventricular leukomalacia [PVL], and birth trauma) were studied serially (Table 1). Follow-up examinations in seven patients have been included in previous reports [1–3] and four of these patients have had further follow-up examinations. All the examinations were reviewed. The examinations were performed with the approval of the Research Ethics Committee of the Royal Postgraduate Medical School and the informed consent of a parent or guardian. The study conformed to guidelines published by the National Radiological Protection Board [7].

The preparation and sedation of the infants have not changed since our previous report [2]. The MR unit used for all examinations was a Picker prototype based on a cryogenic magnet operating at 0.15 T [8]. Slice thickness was 9 mm or 5 mm, with resolution of approximately 1 to 2 mm. Initial examinations were performed with a 28-cm saddle receiver coil. Since August 1983 smaller diameter saddle coils have been used, and since April 1984 closely coupled spherical receiver coils have been used [6, 9]. Until July 1983 image reconstruction was performed by Fourier transformation and projection-reconstruction, and since then by 2DFT with a reconstruction matrix of 128×192 . In April 1984 the matrix size was increased to 256×256 .

A variety of partial saturation (PS) pulse sequences (-90° —data collection without a refocusing 180° pulse) were used to demonstrate anatomy and pathology at different ages, including inversion recovery (IR) and spin-echo (SE) (Table 2). Age-adjusted IR sequences

Received December 31, 1985; accepted after revision June 10, 1986.

¹Department of Diagnostic Radiology, Royal Postgraduate Medical School, Hammersmith Hospital, Du Cane Road, London W12 0HS, U.K. Address reprint requests to J. M. Pennock.

²Present address: Department of Radiology and Diagnostic Imaging, University of Alberta Hospital, 8440 112th Street, Edmonton, Alberta, Canada T6G 2B7.

³Department of Pediatric Neonatal Medicine, Royal Postgraduate Medical School, Hammersmith Hospital, London W12 0HS, U.K.

⁴Institute of Neurology and National Hospital for Nervous Disease, Queen Square, London WC1, U.K.

⁵Picker International, Wembley, Middlesex HA9 7PR, U.K.

AJNR 8:83–92, January/February 1987
0195–6108/87/0801–0083

© American Society of Neuroradiology

were used from July 1984 to compensate for the changing T1 of the developing brain [6]. Preterm infants were examined with IR sequences with TR = 3000 msec and TI = 1000 msec, and patients from age 40 weeks to 3 months were examined with TR of 2400 msec and TI of 800 msec. For children aged 3 months to 4 years, IR sequences with TR = 1800 msec and TI = 600 msec were used. IR sequences with TR = 1500 msec and TI = 500 msec were used in

older children. Before that time the IR sequences with TR = 1800 msec and TI = 600 msec were used irrespective of the child's age. The magnetic field gradient strength was increased in infants and younger children to increase image size.

Serial neurosonographic examinations were performed with an ATL Mark 3 real-time mechanical sector scanner with a 5 or 7 MHz transducer until the closure of the anterior fontanelle. CT examinations were performed in eight of the patients using a Siemens Somatom 2 scanner.

TABLE 1: Clinical Diagnoses in 32 Patients

Periventricular-intraventricular hemorrhage (PVH-IVH):	
With parenchymal involvement	9
With questionable parenchymal involvement	3
Without parenchymal involvement	4
Probable intrauterine IVH with factor V deficiency	1
Subtotal	17
Hypoxic-ischemic encephalopathy (HIE):	
With full syndrome	3
Without full syndrome	2
Subtotal	5
Periventricular leukomalacia	5
Subcortical leukomalacia	2
Birth trauma	3
Subtotal	10
Total	32

TABLE 2: Pulse Sequences Used in This Study

Pulse Sequence	TR (msec)	TI (msec)	TE (msec)
PS 1000	1000		13
IR 3000/1000/44	3000	1000	44
IR 2400/800/44	2400	800	44
IR 2400/800/13f	2400	800	13
IR 1800/600/44	1800	600	44
IR 1800/600/13f	1800	600	13
IR 1500/500/44	1500	500	44
SE 1580/80	1580	—	80
SE 1160/160	1160	—	160
SE 1080/80	1080	—	80
SE 544/44	544	—	44

Note.—PS = partial saturation, TR = repetition time, TI = inversion time, TE = echo time, IR = inversion recovery, SE = spin echo, and f = field echo.

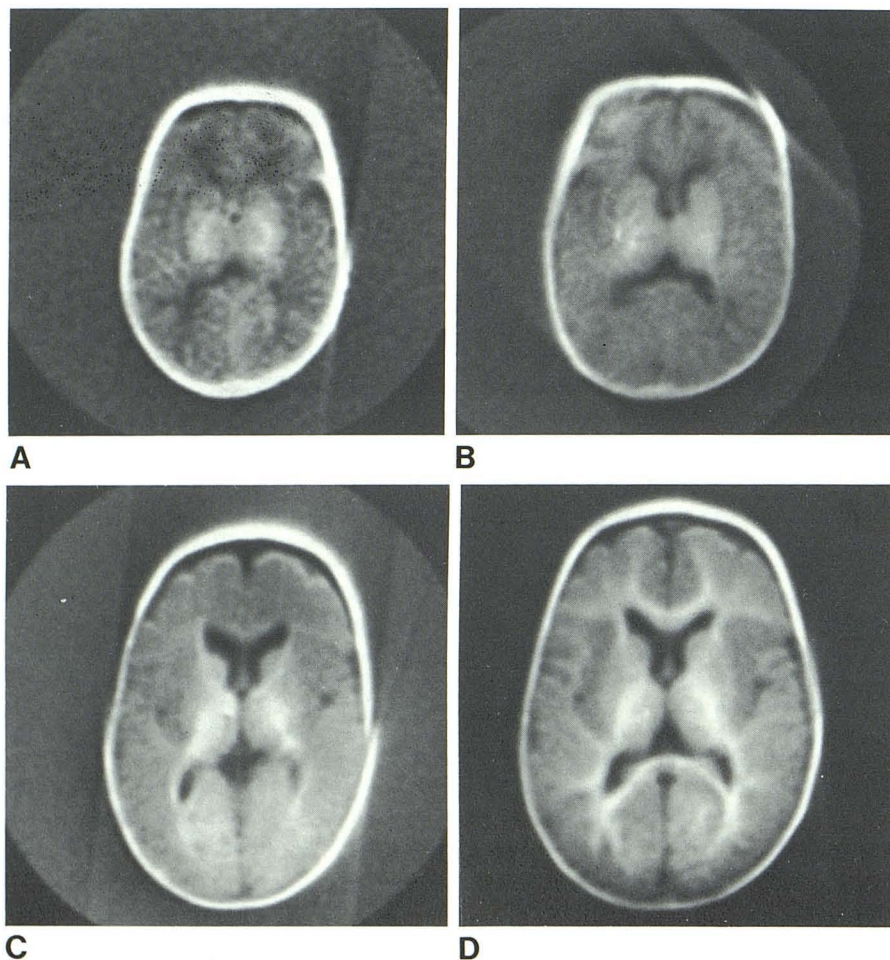


Fig. 1.—Normal IR scans in same child over time (IR 1800/600/13f). A, At 42 weeks postmenstrual age (PMA). B, At 3 months PMA. C, At 6 months PMA. D, At 10 months PMA.

Results

No adverse effects were observed in any of the children examined. A black and white central artifact was seen on many images. Patient movement produced streak artifacts at the edge of projection-reconstruction images and repetitive "ghosts" on 2DFT images. Local defects in the image were produced by ventricular shunts. These defects were occasionally outlined by a rim of high signal. A linear area of absent signal was produced by the shunt when it was in the image plane.

Normal Appearances

The normal appearances of images produced by PS, IR, and SE sequences have been described previously [2]. Serial examinations in one infant using IR 1800/600/13f (f = field echo) sequences showed the normal pattern of development of white matter with age (Fig. 1). From birth until the age of 3 to 6 months, the long T1 of periventricular white matter resulted in lower signal of unmyelinated white matter relative to gray matter. With IR images this produced an "edge-enhancement" effect with highlighting of cortical gray matter between the long T1 (low signal) of CSF and unmyelinated white matter (Fig. 2). Crossover of the T1 values of gray matter and unmyelinated white matter occurred between 3 and 6 months of age, when the highlight effect disappeared.

Abnormal Appearances

Myelination of white matter was assessed on initial and follow-up examinations (Table 3) using a low ventricular slice at the level of the thalami and internal capsule. The level of myelination was divided into three categories: (A) "normal,"

when the level of myelin was the same as in an age-matched normal child, (B) "delayed," if little or no myelination was identified in a major tract in which it was present in a normal age-matched control (these two comparisons were made only if the examinations had been done with the same technique), or (C) "not assessable," when no satisfactory age-matched control was available or where focal pathology such as hemorrhage was present in the region of the thalami and internal

TABLE 3: Myelination Assessment ($n = 32$)

Diagnosis	Initial Examination			Follow-up Examination		
	N	D	NA	N	D	NA
PVH-IVH with parenchymal involvement ($n = 9$)	4	4	1	6	2	1
PVH-IVH with questionable parenchymal involvement ($n = 3$)	3	0	0	3	0	0
PVH-IVH without parenchymal involvement ($n = 4$)	3	1	0	3	0	1
Probable intrauterine IVH ($n = 1$)	1	0	0	1	0	0
Hypoxic-ischemic encephalopathy with full syndrome ($n = 3$)	3	0	0	3	0	0
Hypoxic-ischemic encephalopathy with partial syndrome ($n = 2$)	0	2	0	0	2	0
Periventricular leukomalacia ($n = 5$)	1	2	2	1	4	0
Subcortical leukomalacia ($n = 2$)	0	0	2	0	0	2
Birth trauma ($n = 3$)	2	0	1	2	1	0

Note.—PVH = periventricular hemorrhage, IVH = intraventricular hemorrhage, N = normal, D = delay, and NA = not assessable.

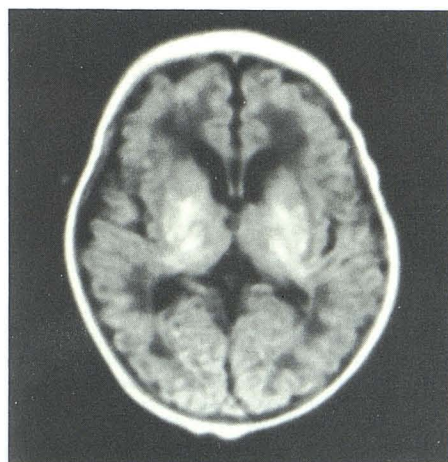

Fig. 2.—Normal scan (IR 2400/800/44) at 9 days of age in term infant with birth asphyxia. Note prominent long T1 of periventricular white matter with edge-enhancement effect resulting in highlighting of cortical mantle. Early myelination in thalami is present.

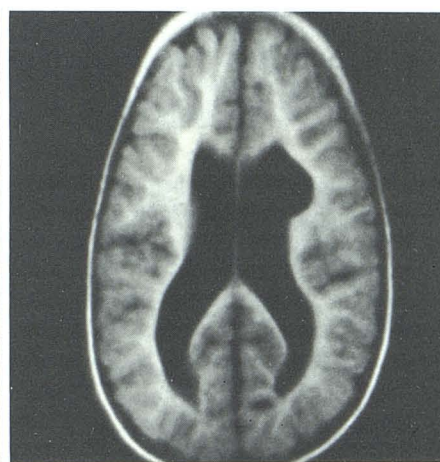
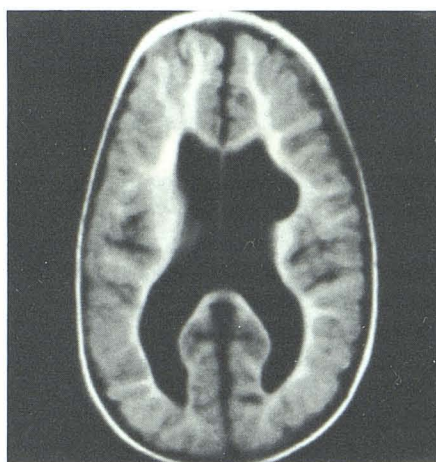
Fig. 3.—PVH-IVH with parenchymal involvement and left porencephalic cyst. High-resolution scans (IR 1800/600/44) at 13 months postmenstrual age (PMA) (A) and 17 months PMA (B). Note relative decrease in amount of myelin and small porencephalic cyst on left.

capsule, making comparison difficult or impossible. Ventricular size was assessed as normal or increased and the presence and location of porencephalic cysts were recorded. Results of clinical developmental assessments were also recorded.

Periventricular-Intraventricular Hemorrhage (PVH-IVH) (16 Cases)

A. PVH-IVH with Associated Parenchymal Involvement (9 Cases)

Three infants had a normal level of myelination on the initial and follow-up studies in the presence of ventricular dilatation and porencephalic cysts. Two of these children had motor delay and hemiplegia contralateral to the porencephalic cyst. One child with normal development showed a relative decrease in myelin ipsilateral to a porencephalic cyst but with no hemiplegia (Fig. 3).

In one child myelination was not assessable on the initial scan at 36 weeks PMA because of hemorrhage. At 20 months the level of myelination was within normal limits despite

anatomic distortion from bilateral porencephalic cysts at the sites of previous infarction (Fig. 4). This child had delayed motor development and a left hemiplegia.

Four infants had a delay or deficit in myelination on the initial study. Two of these had achieved the expected level of myelination at follow-up and were developmentally normal although a slight hemiplegia was found in one child. The ventricles were not dilated in either child but a small porencephalic cyst was seen in one of them. The third child had a motor delay but the level of myelination was not assessable on follow-up examination, although an increase in the myelination had occurred despite hydrocephalus. The fourth infant failed to achieve the expected level of myelination for his age at follow-up and was grossly retarded. Placement of a ventricular shunt had no clinical benefit.

One child who had associated periventricular leukomalacia (PVL) had normal myelination at 40 weeks PMA. Periventricular cysts were seen on the first scan. Increased ventricular dilatation was seen on a later study despite a ventricular shunt, which suggested either absorption of the cysts into the ventricular system or dilatation of the ventricular system after cyst collapse. This patient had mixed dystonic cerebral palsy and severe developmental delay.

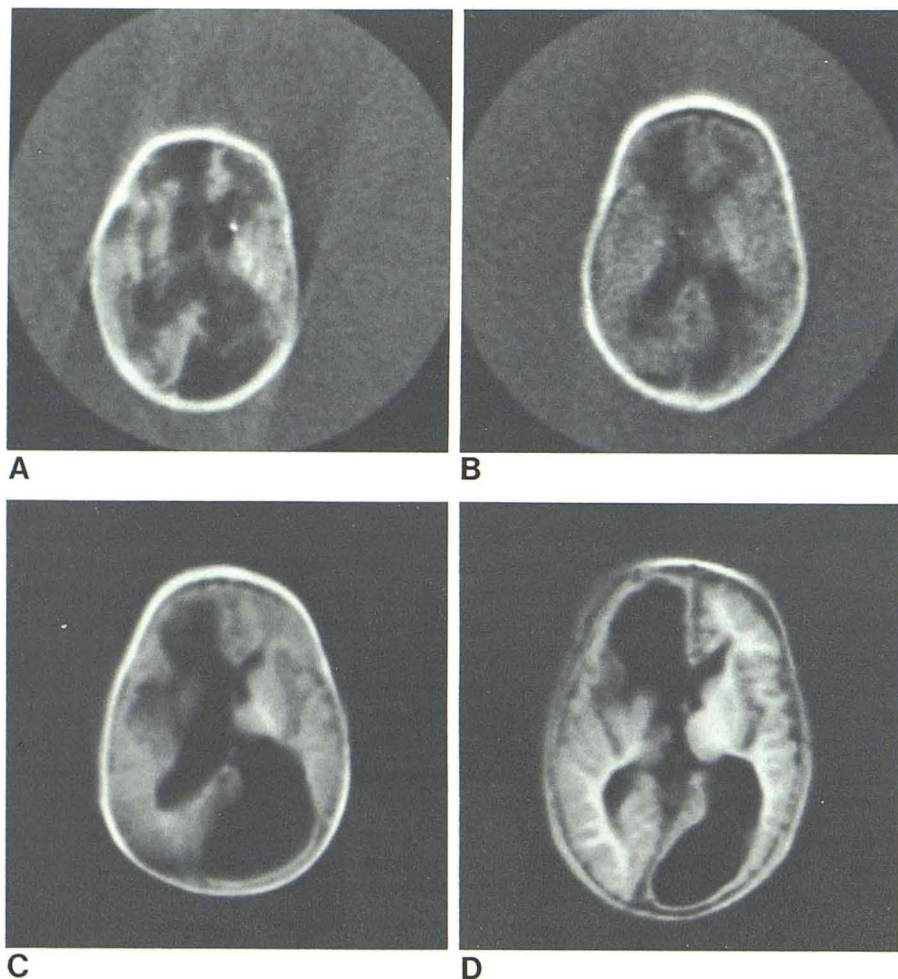


Fig. 4.—IR 1800/600/13f scans in a child with PVH-IVH with parenchymal involvement at 35 weeks postmenstrual age (PMA) (A), at 40 weeks PMA (B), at 9 months PMA (C), and at 18 months PMA (D). Note right intracerebral hematoma and long T1 of infarcts on A with resolution of hemorrhage and early myelination on B. Porencephalic cysts at sites of hematoma and infarcts with progressive delayed myelination identified on C and D.

B. PVH-IVH with Questionable Parenchymal Involvement (3 Cases)

The level of myelination was normal on initial and follow-up scans in all three patients. The ventricular system was normal in two of these infants and returned to normal in the third child after placement of a ventricular shunt with a concomitant reduction in periventricular edema. After the shunt placement this patient showed an improvement in her right hemiparesis and motor development. In one child an ill-defined area of mixed long and short T1 in the right parietooccipital area on the initial IR scan at 13 months PMA was not identified on follow-up scans 7 months later. The significance of this area seen on the first scan remains uncertain, as the child was developing normally. The third child, scanned at 11 and 20 months PMA, had generally delayed development and hypotonia.

C. PVH-IVH Without Parenchymal Involvement (4 Cases)

Normal myelination was identified on initial and follow-up scans in the three patients with normal clinical development. Ventricular enlargement was seen in two of these children at

both examinations. In the third child, a term baby examined at 43 weeks PMA, subarachnoid hemorrhage and periventricular edema were seen. A ventricular shunt was inserted 3 months later causing a further subarachnoid hemorrhage. At 10 months PMA the level of myelination was normal with mildly increased ventricular size (Fig. 5). Asymmetry of tone present initially in this child resolved with subsequent normal development. The fourth patient showed delay in myelination at the initial examination and was not assessable at 45 months for want of an age-matched control. An increase in the level of myelination had occurred between the scans, and ventricular dilatation was seen. This child had developmental delay.

D. Probable Intrauterine IVH (1 Case)

A child with probable intrauterine IVH and factor V deficiency showed marked enlargement of the right occipital horn on initial IR scan at 39 weeks PMA, when early myelin was present. At 18 months PMA, after a ventriculoperitoneal shunt, myelination and ventricular size were normal except for a right occipital porencephalic cyst. Within this cyst was a lesion with shorter T1, possibly representing retained thrombus. The patient had had bleeding problems related to the

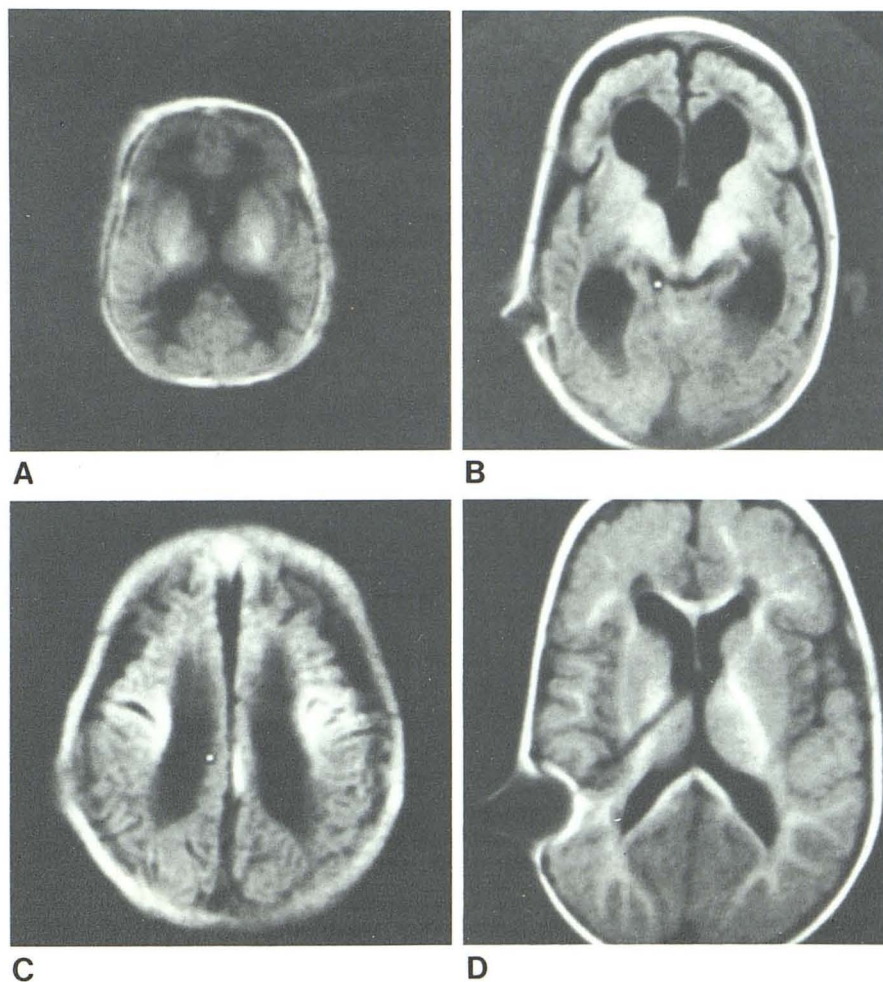


Fig. 5.—PVH-IVH without parenchymal involvement. A, IR 1800/600/13f scans at 43 weeks postmenstrual age (PMA) show mild ventricular dilatation, prominent long T1 of periventricular white matter, early myelination, and right subarachnoid hemorrhage. B and C, Follow-up IR 1800/600/44 scans at 4 months PMA after ventriculoperitoneal shunt placement, with further ventricular enlargement, periventricular edema, and subarachnoid hemorrhage. D, Final IR 1800/600/44 scan at 10 months PMA, with normal myelination apart from slight relative decrease in right frontal lobe and mild ventricular dilatation. Note defect related to ventriculoperitoneal shunt.

shunt. Her development was borderline and she had a marked convergent squint.

Hypoxic Ischemic Encephalopathy (HIE) (5 Cases)

A. HIE with the Full Syndrome (3 Cases)

Three children had the full syndrome of fetal bradycardia, meconium-stained amniotic fluid, neonatal seizures, and altered consciousness. Myelination was normal in these children. One patient had developmental delay, retardation, and athetoid type cerebral palsy despite a normal MR. The initial scan in the second patient, performed at 42 weeks PMA, showed more prominent periventricular areas of long T1 and long T2 on IR and SE scans than those seen in a normal child. A follow-up scan at 20 months PMA was normal apart from focal increased T2 at the posterior angle of the right lateral ventricle on SE scan. This child was neurologically

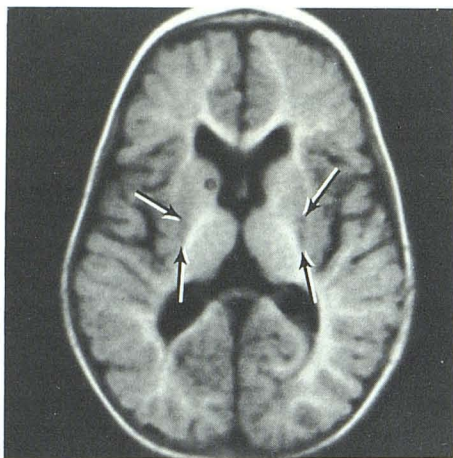


Fig. 6.—Hypoxic-ischemic encephalopathy with full syndrome. IR 1800/600/44 scan at 9 months. Note area of long T1 in basal ganglia (arrows).

normal. In the third child, examined at 41 weeks PMA, early myelin was seen with extensive areas of long T1 in the periventricular regions on the first scan. Follow-up study revealed normal myelination with areas of long T1 in the basal ganglia and mild ventricular dilatation (Fig. 6). Clinically, this child had mixed spastic and athetoid cerebral palsy.

B. HIE with the Partial Syndrome (2 Cases)

Myelination was delayed initially and at follow-up in these infants, and the ventricular size was normal. In a patient of 12 months PMA, an area thought to represent infarction was present at the right vertex. Reduced myelination was seen posteriorly on the right below the level of the infarct. An increase in myelination was seen 7 months later; however, myelination remained reduced posteriorly on the right. Clinically, mixed dystonic cerebral palsy and delayed development were present. The other child was scanned at 5 months PMA and focal areas of long T2 in periventricular white matter were seen at the anterior angles of the lateral ventricles on SE scans. Follow-up IR and SE scans 13 months later revealed increased myelination, although there was a delay posteriorly in the thalamooccipital radiation. Focal areas of long T1 and long T2 were again noted at the ventricular angles in this patient who had spastic quadriplegia.

Periventricular Leukomalacia (PVL) (5 Cases)

One child in this group was examined at 8 months and showed a delay in myelination, ventricular dilatation, and multiple cystic areas in the periventricular white matter. The follow-up scan at 17 months PMA showed very little change (Fig. 7). This child was cortically blind, with severe developmental delay and diplegia. A second child had normal myelination at age 4 months, ventricular dilatation, and cystic areas in white matter. After shunt revision, the ventricles collapsed and no myelin could be identified. There was little evidence

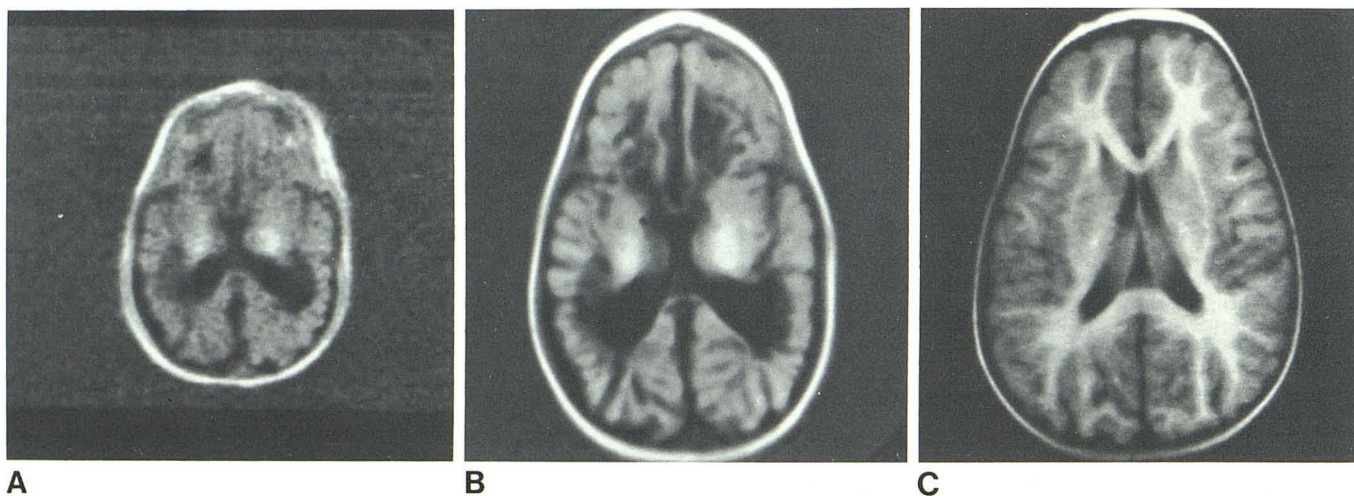


Fig. 7.—Periventricular leukomalacia. A, IR 1800/600/13f scan at 8 months postmenstrual age (PMA) shows reduced myelination with periventricular long T1 cystic areas. B, Follow-up high-resolution IR 1800/600/44 scan at 17 months PMA shows little progress in myelination and persistent periventricular cystic areas. C, IR 1800/600/44 scan in normal twin at 17 months PMA for comparison.

44 scan at 17 months PMA shows little progress in myelination and persistent periventricular cystic areas. C, IR 1800/600/44 scan in normal twin at 17 months PMA for comparison.

of development of myelin on the final examination on this child at age 26 months. The ventricles remained collapsed. The child was cortically blind and had gross motor and mental delay with spastic quadriplegia. The third patient in this group had enlarged posterior horns of the lateral ventricles. The delay in myelination on both examinations in this patient was most marked in the thalamooccipital radiation. This child had spastic quadriplegia.

In the fourth infant almost no increase in the level of myelination was seen between the initial scan at 40 weeks and the follow-up scan at 4 months PMA. Multiple areas of long T1 were present in the brain parenchyma on the initial scan. At 4 months, increased ventricular size, especially posteriorly, suggested cyst coalescence with the ventricles. This child was cortically blind with spastic quadriplegia. In the fifth patient cystic areas were seen in the centrum ovale at 33 weeks PMA. At 40 weeks PMA, short T1 areas of periventricular hemorrhage were identified and the level of myelin was not assessed. The hemorrhage resolved but the long T1 cystic areas in periventricular white matter and the centrum semiovale remained and the level of myelination was normal at 6 months PMA (Fig. 8). Spastic diplegia and motor delay were present in this child, who had normal vision.

Subcortical Leukomalacia (2 Cases)

The initial scans on both infants were done at 37 weeks PMA. Myelination was not assessable on the initial or follow-up study. One patient demonstrated short T1 areas in the basal ganglia, and there were extensive areas of long T1 throughout the hemispheres. These findings were interpreted as basal ganglia hemorrhage (short T1) and extensive infarction (long T1). Follow-up scans at ages 3 and 5 months PMA showed little or no development of myelination in either case. The ventricles were dilated and the extensive areas of long T1 remained (Fig. 9). Both infants were severely retarded with microcephaly and spastic quadriplegia.

Birth Trauma (3 Cases)

A hemorrhagic infarct involving most of the right hemisphere in a patient with birth trauma was recognized by its short T1 on IR and long T2 on SE scans at 1 week of age. Associated mass effect and ventricular displacement were present. Myelination was not assessable. Follow-up scans at ages 2 weeks, 6 months, and 10 months showed resolution of the hemorrhage and development of an irregular cystic area with internal strands at the site of the previous infarct. Loss of volume of the right hemisphere, ventricular enlargement, and relatively decreased myelination on the right were identified (Fig. 10). Left hemiplegia and absent left auditory response were noted.

A baby scanned at 43 weeks PMA with myelin in the thalami demonstrated an extraaxial collection of fluid with long T1 in the left posterior fossa with associated displacement of the cerebellum and brainstem and mild ventricular dilatation. This collection traversed the tentorium to lie posterolateral to the brainstem. A ventricular shunt was inserted and subsequently a left choroid plexus papilloma was resected. Follow-up scans at 10 and 19 months PMA showed a reduction in size of the extraaxial fluid collection with normal ventricular size and myelination. At the time of the last scan there was delayed motor development and asymmetry of tone. A subdural effusion was diagnosed in an infant with a history of birth trauma who demonstrated widened anterior extracerebral spaces on IR scans at 6 and 11 months PMA. Atrophy of the frontal lobes with mild ventricular dilatation was identified, but myelination and development were normal at both examinations.

Discussion

Follow-up MR examinations display a variety of features. In some diseases such as subcortical leukomalacia there is a close correlation with clinical features, but in other diseases,

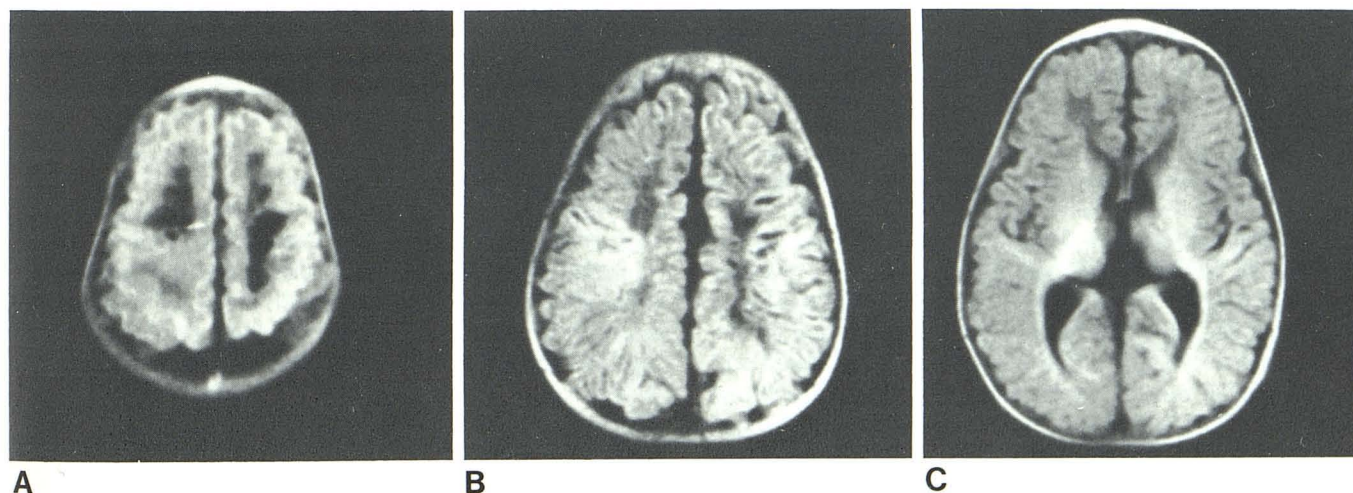


Fig. 8.—Cystic periventricular leukomalacia. A, IR 3000/1000/44 scan at 36 weeks postmenstrual age (PMA) shows cysts in white matter. B and C, IR 1800/600/44 scans at 6 months PMA with normal myelination despite persistent cystic areas in centrum semiovale.

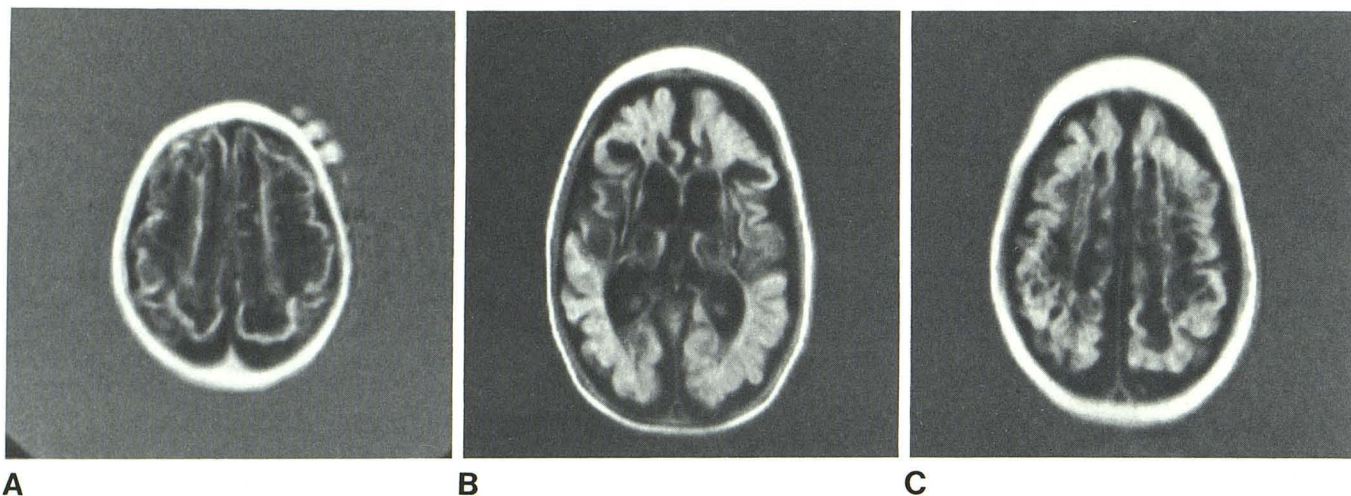


Fig. 9.—Subcortical leukomalacia.

A, IR 2400/800/44 scan at 37 weeks postmenstrual age (PMA).

B and C, IR 1800/600/44 scans at 5 months with ventricular dilation, extensive cystic change, and little development of myelinated white matter on follow-up scan.

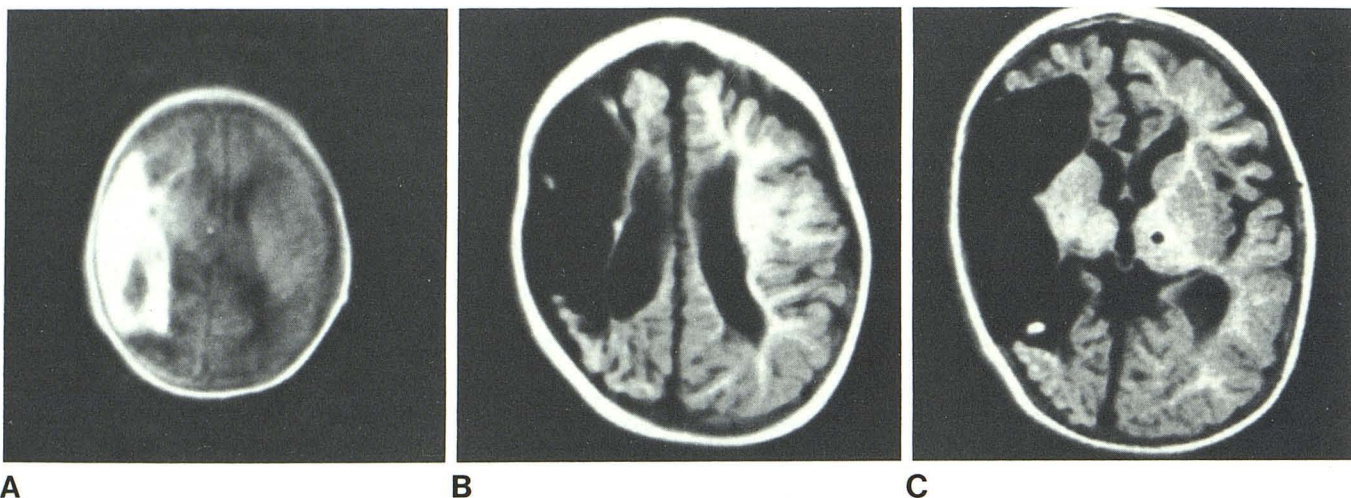


Fig. 10.—Right hemorrhagic infarct.

A, IR 3000/1000/44 scan at age 2 weeks shows increased signal intensity in most of right hemisphere with ventricular compression and minimal mass effect.

B and C, Follow-up IR 1800/600/44 scans at age 10 months. Note development of porencephalic cyst with loss of volume of right hemisphere.

such as infarction or porencephalic cyst formation, dramatic lesions may be seen on MR associated with little or no clinical deficit.

The ability to observe myelination is one of the most striking features of MR, although care is necessary to recognize delays or deficits. These may not be apparent in the first 6 months of life, since the normal level of myelination is low. When children are older there is time for them to "catch up," as the normal rate of myelination slows down. Generally, delays or deficits are easiest to recognize between the ages of about 6 and 24 months. The pattern of myelination identified on IR scans corresponds to that described at postmortem [10–12]. The vulnerability of myelination to adverse effects has been recognized pathologically [12–15] but delays or

deficits in this process have not been recognized in vivo prior to the use of MR.

PVH-IVH is the most common neurologic problem in premature neonates, and the highest mortality and neurologic morbidity occurs in those infants with associated parenchymal involvement [16, 17]. Porencephalic cysts are frequent sequelae. On the basis of neuropathologic observations and positron emission tomography (PET) studies, hemorrhagic intracerebral involvement is thought to be a component of a primary ischemic lesion, representing hemorrhagic infarction rather than extension of IVH [18, 19]. The hemorrhagic component tends to occur anteriorly and on the side of largest IVH, although PET studies demonstrate that the ischemic lesion is much more extensive [18]. Like MR, CT and sonog-

raphy are sensitive in revealing PVH-IVH and the development of porencephalic cysts and ventricular dilatation in the neonate [19, 20]. But unlike MR, CT and sonography cannot be used to follow subsequent development of white matter in these patients.

Another major cause of neurologic morbidity and mortality in neonates is the hypoxic-ischemic lesions, including HIE in the asphyxiated term infant and PVL in the premature neonate [18, 21]. Children with HIE demonstrate weakness of proximal limbs; and abnormalities on radionuclide brain scans are suggestive of ischemia, particularly in the parasagittal region posteriorly [22]. PET studies suggest reduced blood flow to the parasagittal region, with neuropathologic evidence of softening in the parasagittal parietal cortex and subcortical white matter at autopsy [18]. The location is suggestive of watershed infarction with ischemia as the primary pathologic factor. The patient with HIE in this study who demonstrated a cystic lesion in the right parietal area is of interest as an example of probable watershed infarction. One of the other patients with HIE is also worthy of comment; the areas of long T1 in the basal ganglia correlated with the clinical finding of athetoid cerebral palsy.

PVL predominantly involves periventricular white matter in two locations, the occipital radiation at the trigone and deep cerebral white matter of the frontal radiation of the centrum semiovale [23]. PVL may be hemorrhagic or nonhemorrhagic and may result in demyelination or cystic degeneration [15]. In two patients, a severe degree of PVL was present, with extensive cystic white-matter degeneration indicating subcortical leukomalacia. More reports of sonographic diagnosis of PVL are appearing, but the CT diagnosis of the nonhemorrhagic form has been unreliable [19, 24, 25]. In the present study, myelin was not assessable in the patients with subcortical leukomalacia due to extensive cyst formation. Only one patient with PVL had normal myelination at follow-up. All the patients with PVL and subcortical leukomalacia demonstrated developmental delay, spastic diplegia, or quadriplegia, and three were cortically blind. These severe handicaps are in keeping with the previously reported high incidence of serious sequelae of this lesion [26].

The role of MR in intracranial trauma remains to be defined, as few cases have been reported to date [2, 5]. However, initial and follow-up scans in three patients with birth trauma in this study indicate a possible role in assessment of extra-cerebral fluid collections and hemorrhagic infarction and their sequela. The benign subdural effusion was similar to those previously described on CT [27].

The value of T2-weighted sequences in examination of the pediatric brain was not specifically considered in this study. The high level of gray-white matter contrast achieved using IR T1-weighted sequences was thought to be useful in assessing the level of myelination in infants and young children, and these sequences were therefore primarily used in this study. T2-weighted sequences were of value in demonstrating specific pathologic entities such as hemorrhage, infarction, and periventricular edema, although these were equally well-demonstrated on IR sequences.

The lack of ionizing radiation is of particular importance in

serial MR examinations of children, but in addition to this the technique demonstrates anatomic detail well and it is sensitive to a variety of pathologic changes. A start has been made in correlating MR and clinical features, and sequential examinations may help in the study of the natural history of neonatal cerebral injury.

REFERENCES

1. Levene MI, Whitelaw A, Dubowitz V, et al. Nuclear magnetic resonance imaging of the brain in children. *Br Med J* **1982**;285:774-776
2. Johnson MA, Pennock JM, Bydder GM, et al. Clinical NMR imaging of the brain in children: normal and neurologic disease. *AJR* **1983**;141:1005-1018, *AJNR* **1983**;4:1013-1026
3. Johnson MA, Bydder GM. NMR imaging of the brain in children. *Br Med Bull* **1983**;40:175-178
4. Smith FW. The value of NMR imaging in paediatric practice: a preliminary report. *Pediatr Radiol* **1983**;13:141-147
5. Han JS, Benson JE, Kaufman B, et al. MR imaging of pediatric cerebral abnormalities. *J Comput Assist Tomogr* **1985**;9:103-114
6. Dubowitz LMS, Pennock JM, Johnson MA, Bydder GM. High-resolution magnetic resonance imaging of the brain in children. *Clin Rad* **1986**;37:113-117
7. National Radiological Protection Board ad hoc Advisory Group on Nuclear Magnetic Resonance Clinical Imaging. Revised guidelines on acceptable limits of exposure during nuclear magnetic resonance clinical imaging. *Br J Radiol* **1983**;56:944-947
8. Young IR, Burl M, Clarke GJ, et al. Magnetic resonance properties of hydrogen: imaging of the posterior fossa. *AJNR* **1981**;2:487-493
9. Bydder GM, Butson PC, Harman RR, Gilderdale DJ, Young IR. Use of spherical receiver coils in MR imaging of the brain. *J Comput Assist Tomogr* **1985**;9:413-414
10. Lucas Keene MF, Hewer EE. Some observations on myelination in human nervous system. *J Anat* **1931**;6:1-13
11. Yakolev PI, Lecours AR. The myelogenetic cycles of regional maturation in the brain. In: Minkowski A, ed. *Regional development of the brain in early life*. Oxford: Blackwell Scientific Publications, **1967**:3-69
12. Davison AN, Peters A. *Myelination*. Springfield, Ill: Thomas, **1970**:162-182
13. Dobbing J, Sands J. Quantitative growth and development of human brain. *Arch Dis Child* **1973**;48:757-767
14. Dobbing J. The later development of the brain and its vulnerability. In: Davis JA, Dobbing J, eds. *Scientific foundations of pediatrics*. London: William Heinmann Medical Books, **1981**:744-759
15. Larroche JC. *Developmental pathology of the neonate*. Amsterdam: Excerpta Medica, **1977**:269-276, 283-294, 319-344
16. Tarby TJ, Volpe JJ. Intraventricular hemorrhage in the premature infant. *Ped Clin of N Am* **1982**;29:1077-1104
17. McMenamin JB, Shackleford GD, Volpe JJ. Outcome of periventricular-intraventricular hemorrhage with apparent intraparenchymal hemorrhage. *Ann Neurol* **1986** (in press)
18. Volpe JJ. Positron emission tomography in the study of cerebral blood flow in the premature infant with major intraventricular hemorrhage and in the term newborn with asphyxia. Presented at the Developmental Neurobiology Madrid Symposium, Madrid, April **1985**
19. Flodmark O, Becker LE, Harwood-Nash DC, Fitzhardinge PH,

- Fitz CR, Chuang SH. Correlation between computed tomography and autopsy in full-term neonates that have suffered perinatal asphyxia. *Radiology* **1980**;137:93-103
20. Bowerman RA, Donn SM, Silver TM, Jaffe M. Natural history of periventricular/intraventricular hemorrhage and its complications: sonographic observations. *AJNR* **1984**;5:527-538
21. Volpe JJ. Perinatal hypoxic-ischemic brain injury. *Pediatr Clin N Am* **1976**;23:383-397
22. Volpe JJ, Pasternak JF. Parasagittal injury in neonatal hypoxic-ischemic encephalopathy: clinical and neuroradiologic features. *J Pediatr* **1977**;91:472-476
23. Shuman RM, Selednik LJ. Periventricular leukomalacia: one year autopsy study. *Ann Neurol* **1980**;37:231-235
24. Schellinger D, Grant EG, Richardson JD. Cystic periventricular leukomalacia: sonographic and CT findings. *AJNR* **1984**;5:439-445
25. Nwaesei CG, Page KE, Martin DJ, Becker LE, Fitz CR. Periventricular infarction diagnosed by ultrasound: a postmortem correlation. *J Pediatr* **1984**;105:106-110
26. DeReuck J, Chattha A, Richardson EP. Pathogenesis and evolution of periventricular leukomalacia in infancy. *Arch Neurol* **1972**;27:229-236
27. Mori K, Handa H, Itoh M, Okuno T. Benign subdural effusion in infants. *J Comput Assist Tomogr* **1980**;4:466-471