AJNR

MR imaging of optic pathways in patients with neurofibromatosis.

E W Brown, V M Riccardi, M Mawad, S Handel, A Goldman and R N Bryan

AJNR Am J Neuroradiol 1987, 8 (6) 1031-1036
http://www.ajnr.org/content/8/6/1031

MR Imaging of Optic Pathways in Patients with Neurofibromatosis

Eugene W. Brown[1]
Vincent M. Riccardi[2]
Michael Mawad[1,3]
Stanley Handel[4]
Arnold Goldman[4]
R. Nick Bryan[1,3]

Twenty-one patients with documented neurofibromatosis had MR examinations to evaluate possible intracranial disease. In five cases the indication was a known or suspected optic glioma. Two patients were examined because of a history of seizures; the rest were examined as part of a baseline evaluation. Eighteen patients showed evidence of signal hyperintensity on T2-weighted images. Lesions involved the optic nerves, optic chiasm, optic tracts, lateral geniculate body, optic radiations, basal ganglia, periventricular white matter, cerebellar white matter, and dentate nucleus of the cerebellum. Comparison between MR and concurrent CT scans showed MR to be superior in demonstrating the posterior extent of optic-pathway gliomas. In addition, MR showed focal areas of hyperintensity in the basal ganglia, internal capsule, cerebellum, and/or white matter that were not detected on CT.

Although we found MR to be superior to CT in detecting intracranial tumors in patients with neurofibromatosis, and in evaluating the extensive involvement of known lesions, the full clinical implications of our findings remain to be determined.

Neurofibromatosis refers to a broad spectrum of disorders characterized primarily by neurofibromas and/or café-au-lait spots [1, 2]. The most common variety, von Recklinghausen disease, is also characterized by iris Lisch nodules, optic-pathway gliomas (OPGs), and other cerebral astrocytomas [2–4]. Alternative forms of neurofibromatosis may include intracranial CNS tumors of other types; for example, acoustic neuromas and meningiomas in acoustic neurofibromatosis [1, 2]. In general, neurofibromatosis is associated with a frequency of intracranial neoplasms six times that found in the general population, and multiple neoplasms are characteristic [5, 6].

Stern et al. [6] have suggested distinct pathologic features of OPGs associated with neurofibromatosis vs those that arise in other settings. In addition, they have suggested that OPGs associated with neurofibromatosis are different from those in other patients because patients with neurofibromatosis were found to have a mean age of 4.9 years at the time of diagnosis vs a mean age of 12 years in patients without neurofibromatosis. Although the suggestions based on their pathologic data have not been substantiated, the results discussed in the present article apply only to OPGs associated with neurofibromatosis.

Often, OPGs are confined to the anterior optic pathways and are associated with a good prognosis [7]. Neurosurgical therapy has been directed at resection of tumors confined to the anterior optic nerves, while tumors involving the chiasm or posterior optic pathways have been irradiated or managed conservatively [8]. An important radiologic contribution to the management of OPG patients involves accurate detection of the intracranial extension of these lesions.

In this context, we retrospectively reviewed the MR and CT scans of 21 patients with von Recklinghausen neurofibromatosis in order to define the roles these techniques play in evaluating such patients. Previously, MR has been shown to provide excellent morphologic demonstration of the optic pathways [9].

In this study, new MR findings of neurofibromatosis were identified that have not

Received October 20, 1986; accepted after revision April 22, 1987.

[1] Department of Radiology, Baylor College of Medicine, Houston, TX 77030.

[2] Department of Medicine and Neurofibromatosis Program, Baylor College of Medicine, One Baylor Plaza, Houston, TX 77030. Address reprint requests to V. M. Riccardi.

[3] Department of Radiology, The Methodist Hospital, Texas Medical Center, Houston, TX 77030.

[4] NMR Associates, 8968 Kirby Dr., Houston, TX 77035.

***AJNR* 8:1031–1036, November/December 1987**
0195–6108/87/0806–1031

TABLE 1: Intracranial MR Findings in Patients with Neurofibromatosis

Case No.	Age	Gender	MR Lesions		CT Lesions
			Optic Pathway	Elsewhere	
1	1½	M	R ON	—	R ON
2	5	F	L ON, R ON, CH	Increased signal in globus pallidus and internal capsule	CH
3	1	M	Englarged orbit, R ON, parasellar mass	Increased signal in periventricular white matter; low-density basal ganglia	CT not available
4	3	F	OT, CH, ON	Increased signal in dentate nucleus of cerebellum	CH, ON
5	5	F	R ON, L ON, CH, OT	Increased signal in basal ganglia and L cerebellar white matter	CH, R ON, L ON
6	5	M	L ON, CH	—	L ON, CH
7	1	F	Probable plexiform neurofibroma, L orbit	—	Probable plexiform neurofibroma in L orbit
8	5	F	R ON, CH	Increased signal in periventricular white matter (frontal region)	CH
9	8	F	CH, OT	Increased signal in posterior midbrain tegmen, dentate nucleus, and globus pallidus	Subtle lucency in globus pallidus
10	5	M	CH, OT, LGB	Cerebellar white matter	CT not available
11	10	F	L ON, R ON, CH, OT, LGB, OR	Possible increased signal in cerebellum	R ON, L ON
12	9	M	CH, OT, hypothalamus	Increased signal in dentate and basal ganglia	R ON, L ON, CH
13	43	F	ON	—	CT not available
14	34	F	—	—	—
15	31	M	—	?Increased signal in periventricular white matter	—
16	7	M	—	Increased signal in basal ganglia and L cavernous sinus; asymmetry of sphenoid bone	Mass in L cavernous sinus with orbit foramina enlargement (probable trigeminal neurofibroma)
17	20	M	—	Large R subependymal lesion with increased signal	—
18	8	M	—	?Increased signal in quadrigeminal plate	CT not available
19	5	M	—	?Increased signal in brainstem and area of midbrain	—
20	8	F	—	—	—
21	29	F	—	—	—

Note.—R = right; L = left; ON = optic nerve; CH = chiasm; OT = optic tract(s); LGB = lateral geniculate body; OR = optic radiation.

been described in the literature before. Also, posterior extension of OPGs to the optic tracts and radiations were demonstrated.

Materials and Methods

MR scans were obtained with a superconducting magnet operating at 0.35 T. Multiple-slice spin-echo images were obtained at short repetition times (TRs), usually 0.5 or 1.0 sec, and at longer TRs of 1.5 or 2.0 sec. Echo times were 28 and 56 msec (30 and 60 msec after renovation and upgrading of our unit). Axial, coronal, and sagittal images were obtained in all patients. The slice thickness was 7.0 mm with 3.0-mm interslice gaps or contiguous, interleaved 5.0-mm slices. Images were acquired on a 128 × 128 matrix with a pixel size of 1.7 mm. Display was on a 256 × 256 matrix. After upgrading of the unit, high-resolution scans were obtained on a 256 × 256 matrix and displayed on a 256 × 256 matrix.

CT scans were obtained on GE 8800 or 9800 scanners. Contiguous axial images with supplemental coronal scans were obtained in some cases. IV contrast material was administered in all cases when clinically feasible, the dose being in proportion to the weight of the patient.

All patients were referred to this study from the neurofibromatosis program, Baylor College of Medicine. In all, the diagnosis of von Recklinghausen disease was documented by one of us. All scans were initially interpreted or reviewed by an experienced neuroradiologist.

A total of 21 patients were included in this study. Both CT scans and MR images were available in 17 of the patients. Four patients had MR but did not have CT for comparison. The patients were 1–43 years old, and included 10 males and 11 females.

Results

Optic-Pathway Lesions

Thirteen patients showed evidence of optic-pathway lesions (Table 1). Two had involvement of a single optic nerve;

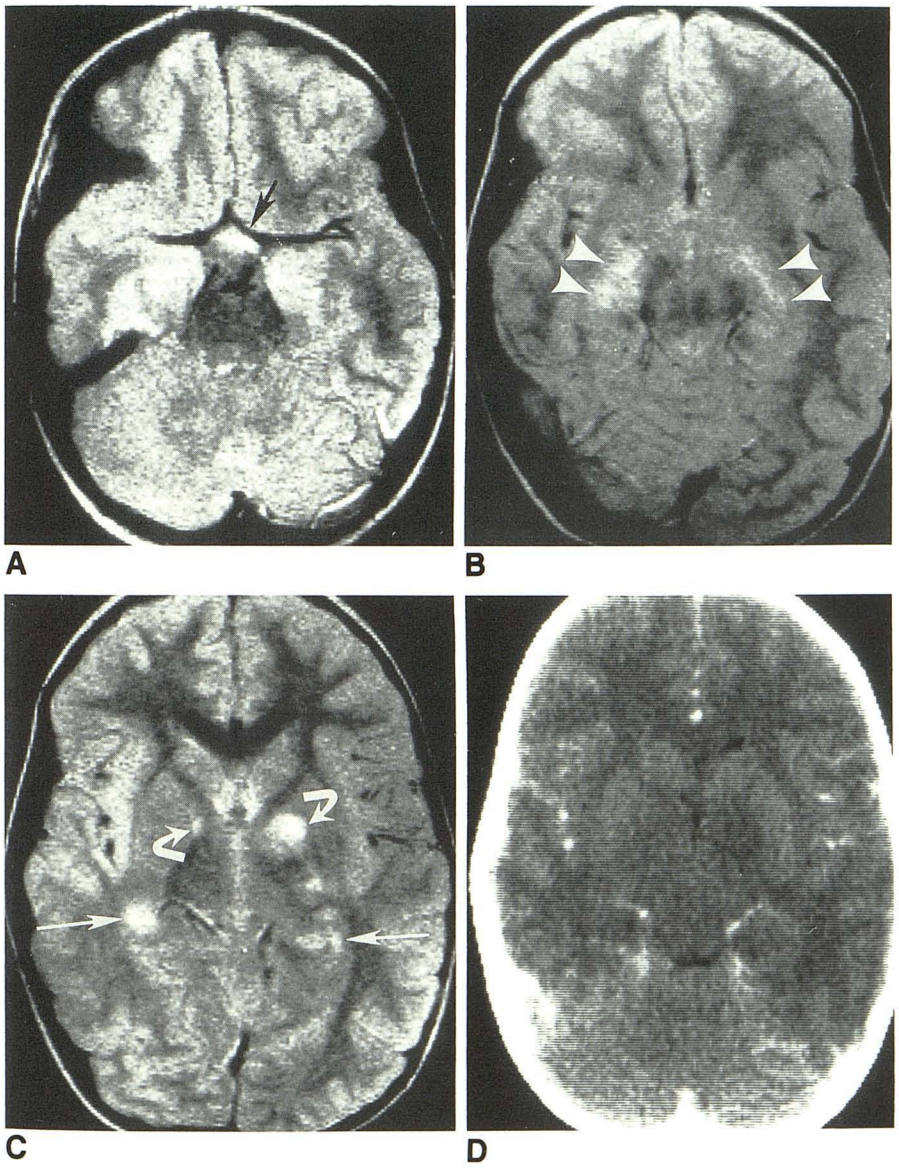

Fig. 1.—Optic-pathway involvement in neurofibromatosis.

***A–C*, T2-weighted MR images show optic-pathway glioma involving chiasm (*black arrow*) with extension into optic tracts (*arrowheads*) and lateral geniculate body (*straight white arrows*). Abnormal signal intensity bilaterally in basal ganglia (*curved arrows*).**

***D*, Contrast-enhanced CT scan at approximate level of *C* shows no definite abnormality.**

another five had involvement of an optic nerve and chiasm. Two patients showed signal hyperintensity along the optic tracts in addition to the nerve and chiasm. In four patients, all elements of the visual pathways were involved, including the optic nerve, chiasm, optic tracts, lateral geniculate body, and optic radiations (Fig. 1).

Table 2 summarizes the distribution of the lesions. The lesions were assigned to one of four areas of involvement: (1) optic nerves; (2) optic chiasm; (3) posterior optic pathways (including optic tracts, lateral geniculate bodies, and optic radiations); and (4) other lesions (including those in the basal ganglia, midbrain, periventricular white matter, and cerebellar white matter). CT and MR were comparable in detecting lesions in the optic nerves and chiasm. The difference in the number of lesions detected by MR (12 optic-nerve and nine chiasmal lesions) and by CT (nine optic-nerve and six chiasmal) is attributable to the three patients who did not have CT scans. Contrast-enhanced CT detected no lesions in the posterior optic pathways, whereas 12 were detected by MR. We believe this result is significant, since, in the 10 patients who had both CT and MR, MR detected 10 lesions, none of which were demonstrated by CT. Therefore, MR was superior in detecting posterior extension along the optic tracts and radiations. No biopsies of these pathways were available in these patients, since in our institution optic-pathway lesions associated with neurofibromatosis are treated conservatively. Thus, the precise pathologic nature of these lesions was not determined; they may represent edema, hamartomas, or neoplastic infiltration.

TABLE 2: MR and CT Distribution of Intracranial Lesions in Patients with Neurofibromatosis

Location	No. of Lesions	
	MR	CT
Optic nerves	12	9
Chiasm	9	6
Posterior optic pathways	12	0
Other	18	2
Total	51	17

Note.—*Posterior optic pathways* include optic tracts, lateral geniculate body, and optic radiations. *Other* locations include lesions of the periventricular white matter, cerebellar white matter (including dentate nucleus), basal ganglia, and midbrain.

Other Intracranial Lesions

Areas of signal hyperintensity on T2-weighted images were detected outside of the optic pathways in a number of patients. These included lesions in the basal ganglia, midbrain, cerebellum, periventricular white matter, and hypothalamus (Fig. 2). A strict tabulation of lesions in these areas showed that while MR detected 18 lesions, only two lesions were detected by CT in these same areas. Again, we emphasize that 21 patients had MR examinations while only 17 were examined by CT.

In eight patients there was no evidence of optic-nerve tumors on CT or MR. Of these eight patients, two showed definite parenchymal abnormalities on MR and another three showed probable abnormalities. Lesions were areas of focal hyperintensity in the basal ganglia, globus pallidus, and periventricular and cerebellar white matter. The cerebellar lesions were difficult to localize precisely. Most often they appeared to be in the dentate nucleus (Fig. 3). However, a white-matter location of these lesions could not be excluded. Except for the absence of optic-pathway involvement, there was no difference in the MR appearances of the lesions in these patients and the parenchymal lesions, described below, in patients with OPGs.

Of the 13 patients with optic-nerve gliomas, seven showed evidence of signal hyperintensity in the basal ganglia, globus pallidus, periventricular white matter, brainstem, and cerebellum. These lesions were indistinguishable from those in patients without optic-nerve tumors. The lesions tended to be focal, without evidence of mass effect. They arose most often in white matter or central nuclear structures. Most were less than 2 cm in diameter. Occasionally they were bilateral but more often they were asymmetric or did not involve the contralateral structure at all. In summary, MR and CT were found to be approximately comparable for evaluating the optic nerves and chiasm. However, intracranial extension along the optic tracts, lateral geniculate body, and optic radiations almost always was demonstrated better by MR than by comparable CT scans. In addition, MR detected multiple parenchymal abnormalities in neurofibromatosis patients with OPGs as well as in patients without evident pathway tumors.

Discussion

The finding of considerable posterior extension of optic-pathway tumors in a large population of neurofibromatosis cases has been described before. Savoiardo et al. [10] described posterior extension to the optic tracts in 13 of 22 cases. In four cases the lateral geniculate body was involved. In no cases did the lesions involve the optic radiations. Savoiardo et al. suggested that contrast-enhanced CT was necessary to detect extension to the structures posterior to the chiasm. They also commented that, in a few cases, spread along the optic tracts was not detected with enhanced CT and was recognized only at surgery. Albert et al. [11] more recently reported MR demonstration of optic-tract extension in two of three cases of chiasmal OPGs. In close agreement with previous results, we found posterior extension demonstrated by MR in six (46%) of 13 cases with optic-nerve or chiasm involvement. However, in our experience, CT scanning alone detected no cases of posterior extension along the optic pathways. This is at odds with the results of Savoiardo et al. [10]. CT scans were not available in all cases, but when available and compared with MR, CT suggested less extensive involvement.

As mentioned above, CT and MR were comparable for detection of optic-nerve and chiasm lesions. This most likely reflects the location of the intraorbital nerve in fat and/or CSF and of the chiasm in the suprasellar cistern and CSF, which provide natural contrast. The infiltrating nature of some optic-

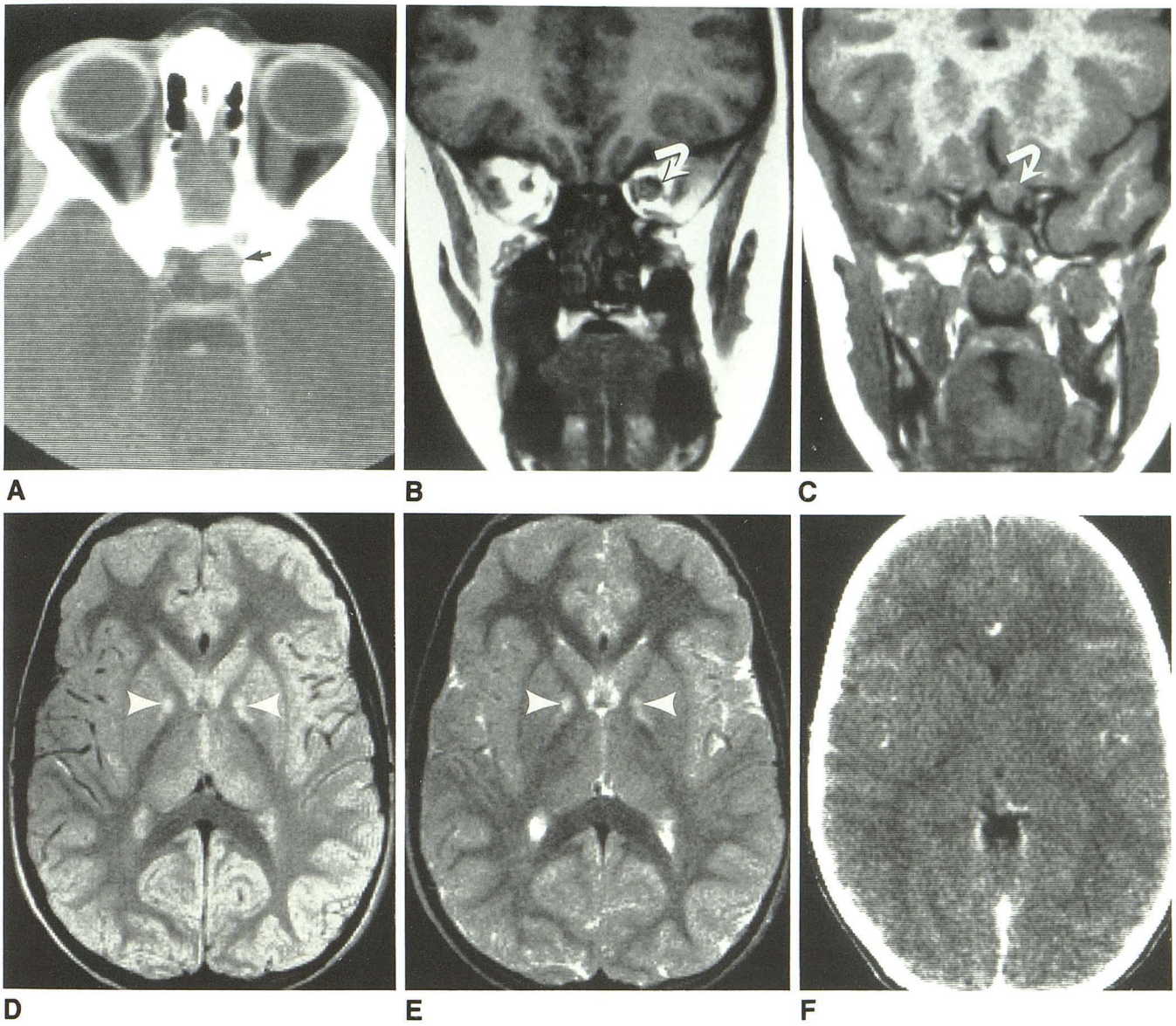

Fig. 2.—Basal-ganglia abnormality in patient with optic-chiasm glioma.
***A*, Contrast-enhanced CT scan shows left optic-nerve glioma extending intracranially to involve optic chiasm (*arrow*).**
***B* and *C*, Coronal T1-weighted scans show similar findings (*arrows*).**
***D* and *E*, Spin-density (*D*) and T2-weighted (*E*) scans show bilateral signal abnormalities in medial aspect of globus pallidus (*arrowheads*).**
***F*, Enhanced CT scan at same level shows no abnormality.**

pathway tumors, especially along the posterior optic pathways, may make CT detection more difficult. MR advantages in the evaluation of these tumors include the lack of ionizing radiation, the lack of a requirement for IV contrast material, and the ease with which scans in different planes can be obtained. For these reasons we suggest that MR should be the study of choice in the evaluation of OPGs.

The finding of multiple parenchymal lesions in the basal ganglia, globus pallidus, brainstem, and cerebellum has not been previously described. In part, this is probably because of the lack of inherent contrast on CT scans. The work of Jacoby et al. [5] suggests that these lesions may actually represent low-grade astrocytomas. Others have believed that such lesions may represent benign hamartomas [12]. However, tumor histopathology cannot be deduced from this mode of study. Serial MR may be helpful in following them. These lesions almost certainly represent an example of the unusual tendency for multifocal dysplasia/neoplasia in the CNS of von Recklinghausen patients and may be closely related to the tendency of these patients to develop visual-pathway tumors. Also of interest is the finding that similar parenchymal lesions are seen in neurofibromatosis patients without optic-pathway involvement. However, a smaller number (two of eight if we count definite lesions) of patients in our groups showed these lesions, which may reflect selection bias in our study and/or the small number of patients.

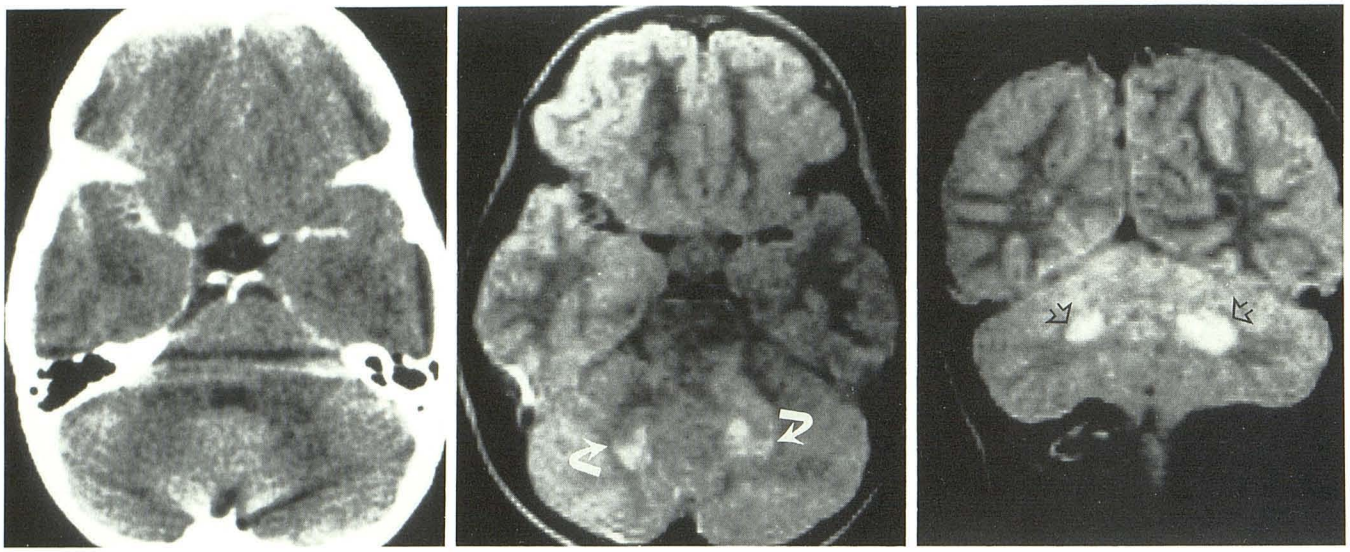

A B C

Fig. 3.—Cerebellar white-matter lesions.
***A*, Contrast-enhanced CT scan at level of fourth ventricle shows no abnormality.**
***B*, T2-weighted MR image at comparable level shows striking hyperintensity in cerebellar white matter (*arrows*).**
***C*, Coronal T2-weighted image at level of cerebellum shows bilateral signal hyperintensity in region of dentate nucleus (*arrows*).**

Like the parenchymal lesions, the optic-pathway involvement detected by MR may represent a spectrum of disease and not necessarily neoplastic change. In fact, MR may be detecting dysplastic areas that have not yet become frankly neoplastic. This is supported by our observation that in cases in which MR showed more extensive involvement than CT did, structures posterior to the chiasm (optic tracts, geniculate bodies, and optic radiations) were involved. One might then speculate that these tumors spread along the optic pathways from anterior (optic nerves and chiasm) to more posterior structures and that areas of dysplastic change might precede the development of neoplasms.

The MR abnormalities seen in these patients undoubtedly will be of interest to students of neurofibromatosis pathogenesis. However, it is not clear that these lesions represent clinically significant abnormalities or that they should influence clinical-management decisions until their natural history is better understood.

ACKNOWLEDGMENTS

We thank Gail Barnard and Jo Lynn Ritter for technical assistance and Karen Pogue and Lynn Sanders for typing the manuscript.

REFERENCES

1. Riccardi VM. Neurofibromatosis: clinical heterogeneity. *Curr Probl Cancer* **1982**;7(2):1–34
2. Riccardi VM, Eichner JE. *Neurofibromatosis. Phenotype, natural history, and pathogenesis.* Baltimore: Johns Hopkins University, **1986**:1–352
3. Lewis RA, Riccardi VM. Von Recklinghausen neurofibromatosis: I. Prevalence of iris hamartomata. *Ophthalmology* **1981**;88:348–354
4. Lewis RA, Riccardi VM, Gerson LP, Whitford R, Axelson KA. Von Recklinghausen neurofibromatosis: II. Incidence of optic-nerve gliomata. *Ophthalmology* **1984**;91:929–935
5. Jacoby CG, Go RT, Beren RA. Cranial CT of neurofibromatosis. *AJNR* **1980**;1:311–315
6. Stern J, Jakobiec FA, Housepian EM. The architecture of optic nerve gliomas. *Arch Ophthalmol* **1980**;98:505–511
7. Swenson SA, Forbes GS, Younge BR, Campbell RJ. Radiologic evaluation of tumors of the optic nerve. *AJNR* **1982**;3:319–326
8. Tenny RT, Laws ER, Younge BR, Rush JA. The neurosurgical management of optic glioma: results in 104 patients. *J Neurosurg* **1982**;57:457–458
9. Daniels DL, Herkins R, Gager WE, et al. Magnetic resonance imaging of the optic nerves and chiasm. *Radiology* **1984**;152:79–82
10. Savoiardo M, Harwood-Nash D, Tadmor R, Scotti G, Musgrave M. Gliomas of the intracranial optic pathways in children: the role of computed tomography, angiography, pneumoencephalography, and radionuclide brain scanning. *Radiology* **1981**;138:601–610
11. Albert A, Lee BCP, Saint-Louis L, Deck MDF. MRI of optic chiasm and optic pathways. *AJNR* **1986**;7:255–258
12. Hoyt WG, Baghdassarian SA. Optic glioma of childhood: natural history and rationale for conservative management. *Br J Ophthalmol* **1969**;53:793–798