

**Are your MRI contrast agents cost-effective?**

Learn more about generic **Gadolinium-Based Contrast Agents**.



**FRESENIUS  
KABI**

caring for life

**AJNR**

**The pituitary mass after transsphenoidal hypophysectomy.**

M M Teng, C I Huang and T Chang

*AJNR Am J Neuroradiol* 1988, 9 (1) 23-26

<http://www.ajnr.org/content/9/1/23>

This information is current as  
of March 27, 2025.

# The Pituitary Mass After Transsphenoidal Hypophysectomy

Michael Mu Huo Teng<sup>1</sup>  
Chun-I Huang<sup>2</sup>  
Tsuen Chang<sup>3</sup>

To understand the natural changes in the CT appearance of a pituitary mass after transsphenoidal hypophysectomy of a pituitary tumor, we obtained CT follow-up studies in 12 patients with pituitary adenoma. The heights of the pituitary masses on the coronal sections of each CT study were measured. It was found that the height of the pituitary mass did not return to normal immediately after the operation, despite complete removal of the pituitary tumor. Instead, the height gradually returned to normal between 3 and 4 months after the operation.

Results of this study suggest that follow-up CT study of pituitary masses is best performed 3–4 months after transsphenoidal hypophysectomy.

Pituitary adenomas are classified as microadenomas or macroadenomas, depending on their size. If the diameter is equal to or less than 1 cm, it is termed microadenoma. Pituitary adenomas can also be grouped into functioning and nonfunctioning adenomas. Functioning adenomas secrete hormones that can cause clinical manifestations even when the mass is small. Therefore, most functioning adenomas are found at the microadenoma stage. We can measure the hormone change postoperatively to determine if there is any residue or recurrence of the pituitary adenoma in functioning adenoma. The symptoms and signs of nonfunctioning adenomas are usually due to mass effect causing compression of surrounding structures and/or impairment of the hormone-secreting function of the pituitary gland. Functioning adenomas may become macroadenomas and cause mass effects; therefore, CT plays an important role in postoperative follow-up.

Transsphenoidal microsurgery has been widely used for pituitary adenoma and is a safe and effective procedure. After the procedure, the height of the soft-tissue contents of the sella (pituitary mass) may not immediately return to normal, despite complete removal of the pituitary adenoma. Pituitary mass may gradually return to normal size with the passage of time [1, 2]. The effect of postoperative radiotherapy may not be accurately evaluated if we do not know the natural course of postoperative change.

This study was designed to evaluate the natural changes in the CT appearance of the pituitary mass after transsphenoidal hypophysectomy.

## Materials and Methods

We performed and reviewed a series of CT studies before and after transsphenoidal hypophysectomy in 12 cases of pituitary adenoma. All these cases were operated on by one neurosurgeon. CT images were obtained with a third-generation high-resolution Siemens Somatom DR3 CT scanner. Coronal scans with magnification after infusion of contrast medium were obtained in every CT study. The angle of coronal CT was usually parallel with the dorsum sellae. The thickness of each slice was 2 or 4 mm, with 2- or 4-mm intervals, respectively. Since only macroadenomas were included in this study, 4-mm slices were usually good enough for us to see and to measure the pituitary mass.

To study the natural posthypophysectomy changes of the pituitary mass, CT of patients

Received April 2, 1987; accepted after revision July 29, 1987.

<sup>1</sup> Department of Radiology, Veterans General Hospital, National Defense Medical Center, and National Yang Ming Medical College, Taipei, Taiwan. Address reprint requests to M. M. H. Teng, Department of Radiology, Veterans General Hospital, 201, Section 2, Shih-Pai Road, Taipei, Taiwan, 11217 Republic of China.

<sup>2</sup> Department of Neurosurgery, Veterans General Hospital, and National Yang Ming Medical College, Taipei, Taiwan, 11217 Republic of China.

<sup>3</sup> Department of Radiology, Veterans General Hospital, and National Yang Ming Medical College, Taipei, Taiwan, 11217 Republic of China.

*AJNR* 9:23–26, January/February 1988  
0195–6108/88/0901–0023

© American Society of Neuroradiology



with a previous history of radiotherapy were not included in this study. To be included in the study, every patient had to have at least one preoperative CT study and two postoperative CT studies. If the patient received a transcranial operation or radiation therapy after the transsphenoidal microsurgery, CT examinations after the second operation or radiation therapy were excluded. The number of postoperative CT follow-up studies ranged from two to five. The time of the last CT follow-up ranged from 79–1065 days after the operation (except case 3, at 34 days).

Six of these cases had nonfunctioning adenomas and six had functioning adenomas. Microadenomas were excluded from this study. The male to female ratio was 4:8. The maximum height of the pituitary mass in each CT study was measured on coronal sections (Table 1).

### Results

The height of the pituitary mass before operation ranged from 1.3–4.7 cm (Table 1). With two exceptions, these masses were high in density or isodense in noncontrast CT, with rather intense and homogeneous enhancement after contrast. One case had mixed density with a fluid level inside due to previous hemorrhage; the other had low density inside without enhancement in the postcontrast study.

In postoperative CT, we can usually see the following: (1) bone defect in the sellar floor due to previous operation; (2) soft tissue in the sphenoid sinus due to blood or fluid accumulation, sometimes with a fluid level; (3) blood clot, air, and packing material such as fat or muscle in the sella; and (4) surgical clip at the diaphragma sellae. The pituitary mass is usually still large in the immediate postoperative study, although it may be slightly smaller than on the preoperative study (Figs. 1–4).

A homogeneously enhancing mass before operation may change to various densities without enhancement inside the mass, with enhancement only in its periphery, in the immediate postoperative CT study. This is due to the removal of the central portion of the mass and replacement with fat, blood, or packing material. Then, the more the nonenhanced part of the mass disappears, the more the height of the diaphragma sellae descends. The height of the pituitary mass before operation ranged from 1.3–4.7 cm. In the final CT study, height was: 1 cm in three cases, greater than 1 cm in two cases, and less than 0.9 cm in seven cases (Table 1). Further treatment was undertaken in both cases in which height was

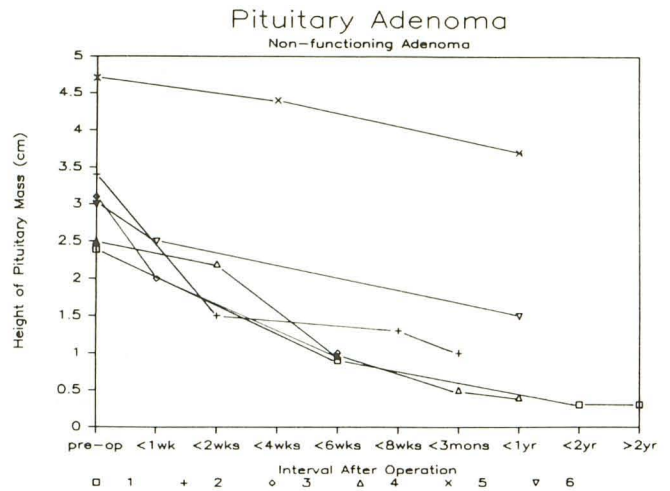


Fig. 1.—Height of pituitary mass after transsphenoidal hypophysectomy in six cases of nonfunctioning pituitary adenoma.

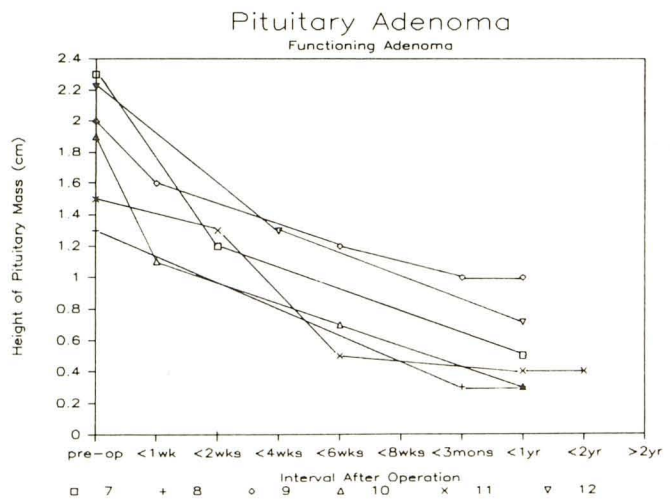


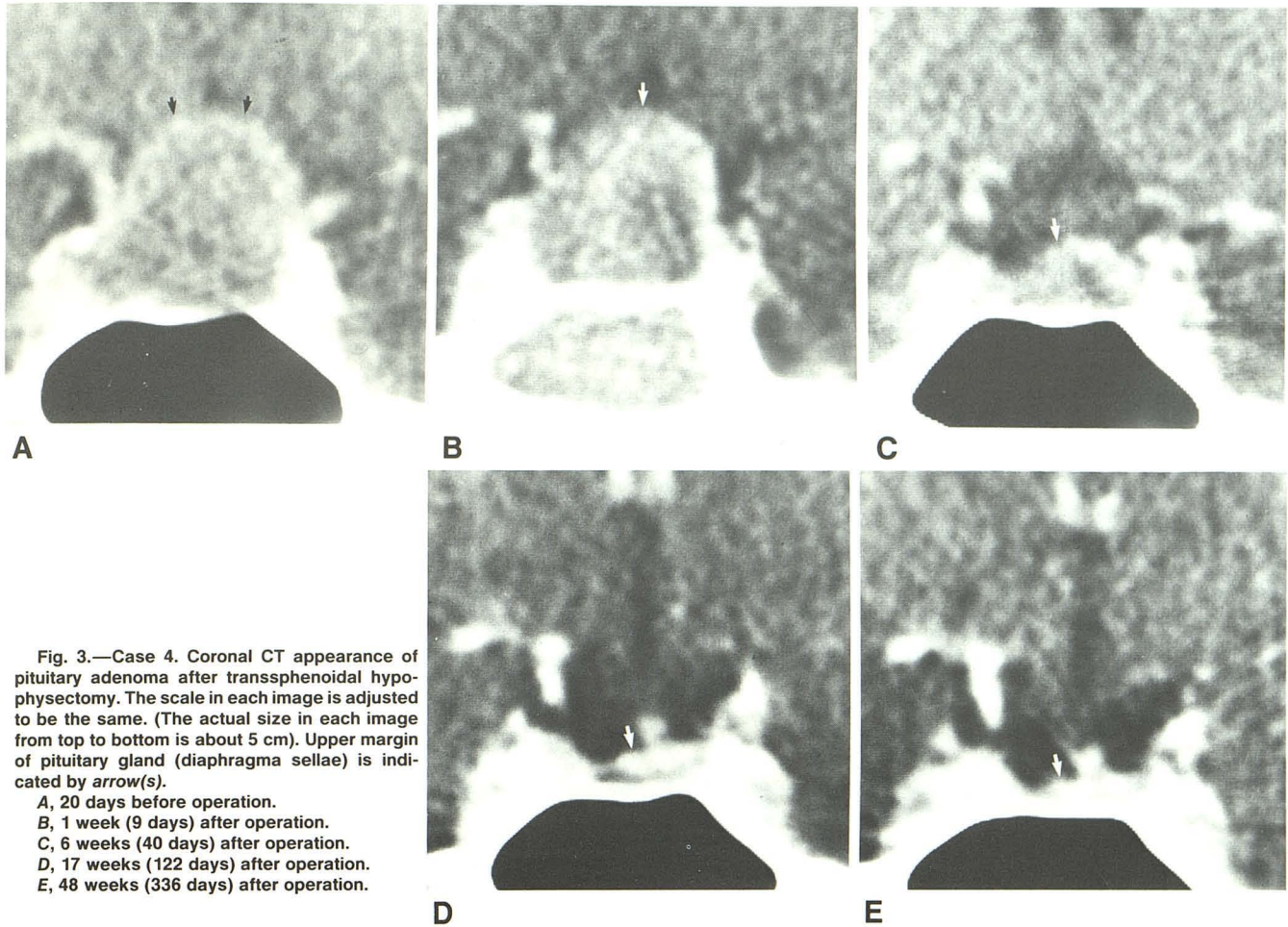
Fig. 2.—Height of pituitary mass after transsphenoidal hypophysectomy in six cases of functioning pituitary adenoma.

TABLE 1: Summary of 12 Cases

Case No.	Age	Gender	Type*	Height of Pituitary Mass (cm)					
				Preoperative CT Scan	Postoperative CT Scans (day/height)				
					1st	2nd	3rd	4th	
1	56	M	NF	2.4	35/0.9	587/0.3	1065/0.3		
2	32	F	NF	3.4	12/1.5	44/1.3	79/1.0		
3	53	M	NF	3.1	3/2.0	34/1.0			
4	33	F	NF	2.5	9/2.2	40/1.0	122/0.5	336/0.4	
5	27	M	NF	4.7	22/4.4	154/3.7			
6	60	M	NF	3.0	7/2.5	148/1.5			
7	20	F	P	2.3	11/1.2	220/0.5			
8	18	F	P	1.3	83/0.3	600/0.3			
9	24	F	P	2.0	7/1.6	40/1.2	94/1.0	265/1.0	
10	22	F	G	1.9	7/1.1	41/0.7	261/0.3	352/0.3	
11	29	F	P	1.5	10/1.3	43/0.5	279/0.4	435/0.4	
12	33	M	G	2.2	23/1.3	225/0.7			

\* NF = nonfunctioning adenoma, P = prolactinoma, G = growth hormone adenoma.





**Fig. 3.**—Case 4. Coronal CT appearance of pituitary adenoma after transsphenoidal hypophysectomy. The scale in each image is adjusted to be the same. (The actual size in each image from top to bottom is about 5 cm). Upper margin of pituitary gland (diaphragma sellae) is indicated by arrow(s).

- A, 20 days before operation.
- B, 1 week (9 days) after operation.
- C, 6 weeks (40 days) after operation.
- D, 17 weeks (122 days) after operation.
- E, 48 weeks (336 days) after operation.

greater than 1 cm in the last CT study: one had a transcranial operation and the other had radiotherapy later. The preoperative high level of secreting hormones in four cases of functioning adenoma returned to normal range. The average height of the pituitary mass before operation was 2.0 cm (1.3–2.5 cm) for tumors with a height less than 9 mm on the final CT study. Although the pituitary mass had been removed completely and had later disappeared spontaneously on CT study, in case 4 it was 2.2 cm on the 9th day after operation (Figs. 1 and 3). All 10 cases that had CT both before the 44th postoperative day and after the 44th postoperative day showed a reduction in the height of the pituitary mass in the later study. Of five cases with two CT studies after the 93rd postoperative day, only one case (20%) showed a decrease in the height of the pituitary mass in the later study (Table 1).

### Discussion

This study confirms that the sellar contents will not return to normal size immediately, regardless of whether the tumor has been completely removed by transsphenoidal hypophysectomy. The reasons why the height of the pituitary mass will not return to normal immediately after operation are as follows: (1) blood clot accumulation in the sella, (2) packing material such as muscle or fat in the sella, and (3) adhesion between the diaphragma sellae or tumor and brain tissue above.

All 10 cases that had CT both before the 44th postoperative day and after the 44th postoperative day showed a reduction in the height of the pituitary mass in the later study. Of five

cases with two CT studies after the 93rd postoperative day, only one case (20%) showed a decrease in the height of the pituitary mass in the later study. We did not see an increase in the height of the pituitary mass in any of these cases, probably because the follow-up period was still too short. From the above data, we suggest that to assess the result of the operation and the size of the residual tumor, CT within 44 days after operation is not necessary and often misleading. If the surgical procedure was smooth and without any complication, 3–4 months after operation may be the optimal time for CT study to evaluate the result.

According to Ciric et al. [2], the rate of recurrence after this operation is about 12%. The time at which the recurrence occurs is 4–8 years after operation for most cases. Six of the 100 cases in the report by Ebersold et al. [3] had clinical evidence of tumor recurrence, and the other 10 cases had radiologic evidence of tumor recurrence. All occurred 48–100 months after operation. Because growth of the pituitary tumor is usually slow and recurrence is often more than 2 years after operation, it seems reasonable to set the postoperative baseline study 3–4 months after the operation.

The contraindications for transsphenoidal hypophysectomy include invasion of brain tissue and cavernous sinus or middle cranial fossa extension [4–7]. A dumbbell type of pituitary tumor in the diaphragma region may be removed better by transcranial resection [6, 8]. Incomplete pneumatization of the sphenoid sinus and previous transcranial removal of the sellar mass are relative contraindications [4, 6, 7]. Transsphenoidal microsurgery is also contraindicated if there is infection



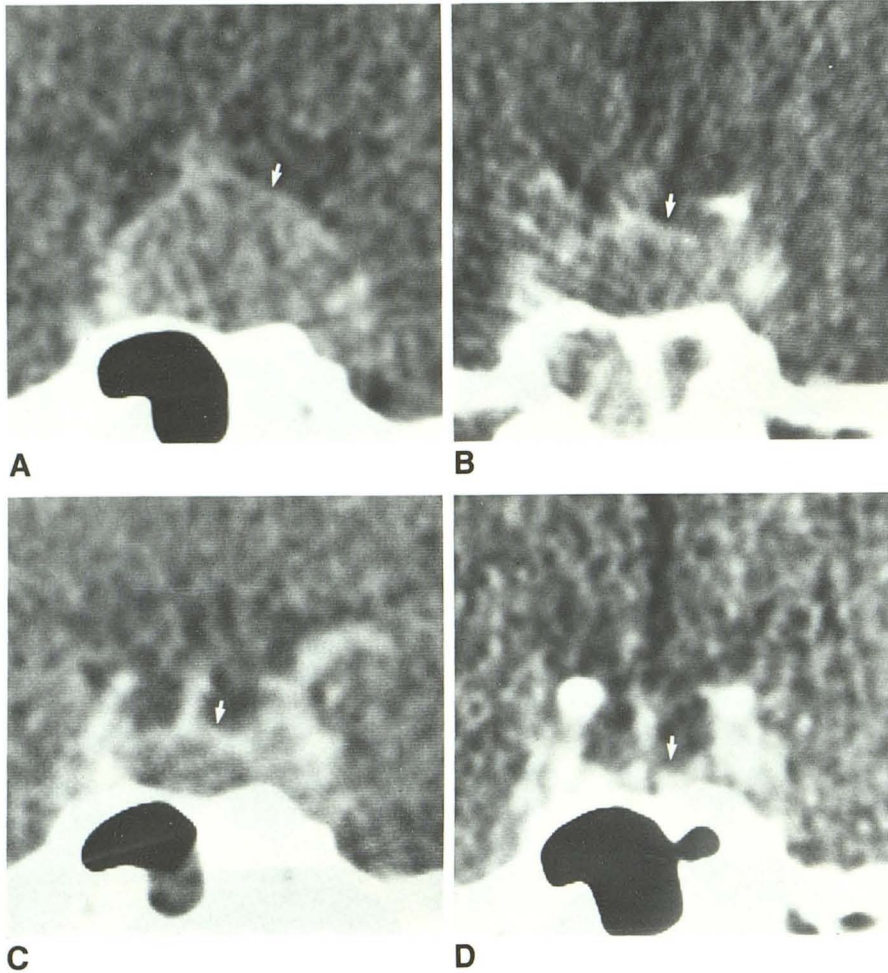


Fig. 4.—Case 10. Coronal CT appearance of pituitary adenoma after transsphenoidal hypophysectomy. The scale in each image is adjusted to be the same. Upper margin of pituitary mass is indicated by arrow.

A, 1 day before operation.

B, 1 week (7 days) after operation.

C, 6 weeks (41 days) after operation.

D, 50 weeks after operation.

of the nasal fossa or sphenoid sinus, for fear of meningitis [8, 9]. This operation is most successful in purely intrasellar masses. Complete removal in our cases was relatively difficult because all of them were macroadenomas with suprasellar extension.

If we consider CT only after the 93rd postoperative day as reliable in evaluating residual tumor, the height of the pituitary gland was still abnormal (higher than 9 mm) in three of 10 cases that had CT later than the 93rd postoperative day. None of the remaining seven cases (70%) showed evidence of residual tumor either by CT (with height 3–7 mm) or by hormone study on the last CT follow-up. The greatest height of the pituitary mass before operation for those completely resected by transsphenoidal microsurgery was 2.5 cm in this study. Pituitary mass lesions with heights more than 2.5 cm may be difficult to remove completely by transsphenoidal microsurgery.

The normal pituitary gland and the diaphragma sellae usually show enhancement as intense as the cavernous sinus. Postoperative enhancement showing decrease in size and intensity with time was presumed to be inflammatory by Kaplan et al. [10]. We saw enhancement in the periphery of the postoperative pituitary mass on CT before the 93rd day after operation in the seven cases in which CT showed no residual tumor after the 93rd postoperative day. With time, the nonenhancing central part gradually disappears and the height of the pituitary mass gradually decreases. Therefore, enhancement itself before 3 months after operation does not necessarily indicate recurrence or a residue of the pituitary tumor [9, 11].

In conclusion, the immediate postoperative CT study is usually misleading in regard to the size of the pituitary mass. For the evaluation of a possible residual tumor and as a baseline for future evaluation of recurrence, postoperative CT is best delayed 3–4 months after operation.

#### REFERENCES

1. Dolinskas CA, Simeone FA. Transsphenoidal hypophysectomy postsurgical CT findings. *AJR* 1985;144:487–492
2. Ciric I, Mikhael M, Stafford T, Lawson L, Graces R. Transsphenoidal microsurgery of pituitary macroadenomas with long-term follow-up results. *J Neurosurg* 1983;59:395–401
3. Ebersold MJ, Quast LM, Laws ER, Scheithauer B, Randall RV. Long-term results in transsphenoidal removal of nonfunctioning pituitary adenomas. *J Neurosurg* 1986;64:713–719
4. Kenan PD. The rhinologist and the management of pituitary disease. *Laryngoscope* 1979;89 (Suppl 14):1–26
5. Zervas NT, Martin JB. Current concepts in cancer: management of hormone secreting pituitary adenomas. *N Engl J Med* 1980;320:210–214
6. Wilson CB, Dempsey LC. Transsphenoidal microsurgical removal of 250 pituitary adenomas. *J Neurosurg* 1978;48:13–22
7. Laws ER, Kern EB. Special circumstances in operative management. In: Laws ER, Randall RV, Abboud CF, eds. *Management of pituitary adenomas and related lesions with emphasis on transsphenoidal microsurgery*. New York: Appleton-Century-Crofts, 1982:271–276
8. Post KD. General considerations in the surgical treatment of pituitary tumors. In: Post KD, Jackson IMD, Reichlin S, eds. *The pituitary adenoma*. New York: Plenum, 1980:341–363
9. Allen MB Jr, El Gammal T, Nathan MD. Transsphenoidal surgery on the pituitary. *Am Surg* 1981;47:291–306
10. Kaplan HC, Baker HL Jr, Houser OW, Laws ER Jr, Abboud CF, Scheithauer BW. CT of the sella turcica after transsphenoidal resection of pituitary adenomas. *AJNR* 1985;6:723–732
11. El Gammal T. CT after transsphenoidal hypophysectomy. *AJNR* 1985;6:842