AJNR

Spontaneous resolution of spinal canal deformity after burst-dispersion fracture.

T M Chakera, G Bedbrook and C M Bradley

AJNR Am J Neuroradiol 1988, 9 (4) 779-785
http://www.ajnr.org/content/9/4/779

Spontaneous Resolution of Spinal Canal Deformity After Burst-Dispersion Fracture

T. M. H. Chakera[1]
George Bedbrook[2]
C. M. Bradley[3]

We reviewed the records of 28 patients with 30 burst-dispersion spinal fractures treated since the introduction of CT facilities in Western Australia. Twenty-five patients showed spinal canal deformity and stenosis with bone fragments protruding into the canal on the initial scan. Of these, 22 patients were treated nonsurgically. Fifteen of the conservatively treated patients were available for follow-up, and they form the basis of this report. Thirteen of the 15 patients who had repeat CT at follow-up showed correction of the previously measured spinal canal stenosis by spontaneous resorption of intraspinal bone fragments. In view of this previously unreported finding, it is suggested that the role of surgical correction of spinal canal stenosis resulting from displaced bone fragments after trauma be more clearly defined.

Knowledge of the detailed anatomy of spinal fractures has advanced significantly since the introduction of CT [1, 2]. The burst-dispersion injury of the thoracolumbar vertebrae has been described previously as the comminuted burst fracture [3] and as the crush-cleavage fracture [4]. The optimal management of this injury is controversial, and relatively few authors have addressed the issue of the burst-dispersion fracture and its management [5]. Direct removal of the bone fragments from the spinal canal has been proposed and a new technique recently described [6]. There is no doubt that surgery, adequately performed, can correct the spinal canal deformity. However, the natural history of the structural changes occurring after injury has not been completely described. For this reason we decided to study the natural history of bone fragments within the spinal canal after a burst-dispersion type of vertebral body fracture in patients with significant neurologic deficit.

Materials and Methods

All the spinal CTs were obtained at Royal Perth Hospital on a Siemens Somatom 2 (third generation) scanner. There were 30 fractures in 28 patients. The sites of fracture are shown in Table 1. Most of the injuries occurred in the thoracolumbar region. All patients showed neurologic lesions, which varied from complete paraplegia to incomplete isolated radiculopathy. Of the 25 patients who showed bone fragments deforming the spinal canal and causing a varying degree of stenosis, 22 patients were managed conservatively. Fifteen of these latter patients had follow-up scans and form the basis of this report. Duration of follow-up varied from 3 months to 4 years. Reference was made to original scans to duplicate conditions (scanning angle and slice thickness) to obtain comparable images in order to eliminate artifacts and errors in measurements.

The sagittal and coronal diameters of the spinal canal and the area of the spinal canal at the level of the fracture were measured on the initial scan and subsequently on comparable images of the follow-up scans to determine the improvement in the degree of stenosis. Reference was made to original scans so as to produce comparable images as far as practicable. The anteroposterior measurements of the canal were obtained directly by the use of cursors. A cross-sectional area of the spinal canal was determined manually by simple graphic integration after optical (equimetric) enlargement of selected slices to ×2 size. Measurements were always made at the level of maximum stenosis.

Received August 10, 1987; accepted after revision January 6, 1988.

[1] Department of Diagnostic Radiology, Royal Perth Hospital, Box 22133 GPO, Perth, Western Australia 6001. Address reprint requests to T. M. H. Chakera.

[2] Spinal Unit, Royal Perth (Rehabilitation) Hospital, Shenton Park, Western Australia 6008.

[3] Department of Orthopaedics, Royal Perth (Rehabilitation) Hospital, Shenton Park, Western Australia 6008.

AJNR 9:779–785, July/August 1988
0195–6108/88/0904–0779

Results

Thirteen of 15 patients showed spontaneous resolution of the previously measured spinal canal stenosis and deformity, as illustrated in the following cases.

Case 1

A 27-year-old miner was admitted after having fallen 30 meters down a mine shaft. There was no loss of consciousness and limb movement and sensation were never impaired.

TABLE 1: Frequency Distribution of the Fractures and Results After Follow-up CT

Region	No. of Fractures	Treated Surgically	Treated Nonsurgically	Fragments in Canal	Follow-up CT Scan	Improvement on CT Scan
Cervical	4	2	2	3	—	—
Thoracic	7	1	6	4	3	3
T12	2	—	2	2	2	2
L1	7	2	5	6	4	4
L2	3	2	1	3	1	1
L3	1	—	1	1	1	1
L4	2	—	2	2	1	1
L5	3	1	2	3	2	1
Sacrum	1	—	1	1	1	—
Total	30	8	22	25	15	13

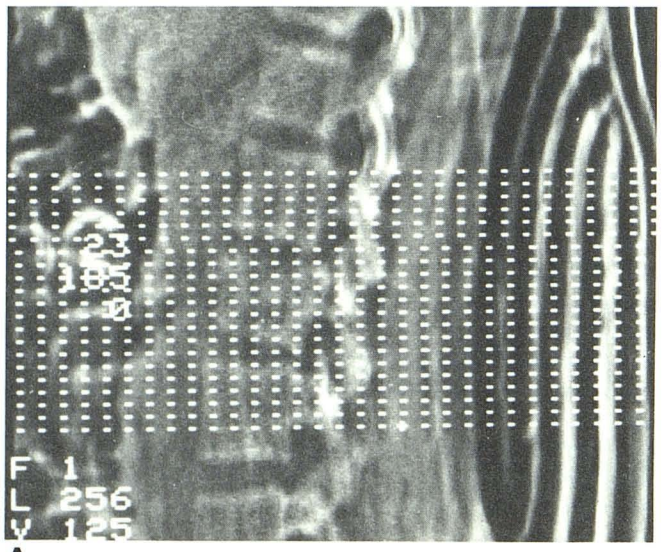

A

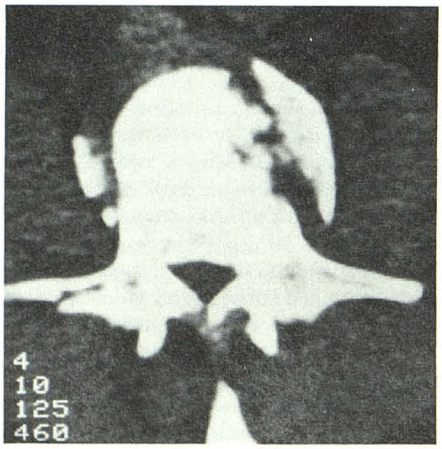

B

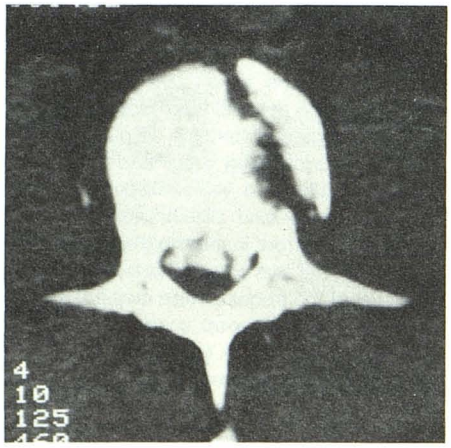

C

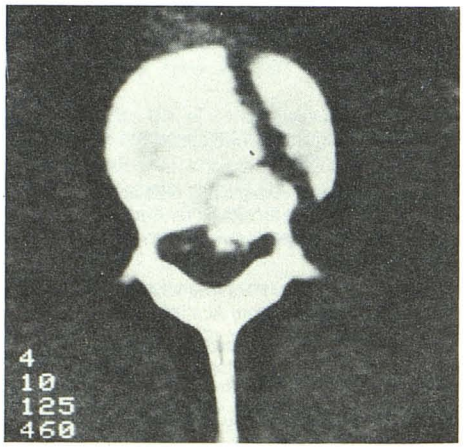

D

Fig. 1.—*A*, Lateral scanogram showing the slices obtained at 0° gantry angle.

***B–D*, CT scans (June 1984). Contiguous 4-mm axial slices through fractured body of L2 delineating the degree of spinal deformity and focal stenosis.**

***E–H* are on opposite page.**

However, the patient was unable to walk because of pain in his back. Radiographs showed a burst-dispersion fracture of L2. On admission the patient's neurologic deficit was charted at Frankel grade D, and on follow-up 21 months later it was charted at Frankel grade E, indicating complete neurologic recovery [7]. He was treated in extension with an extension pillow at the L2 level. Four weeks after the injury he was gradually mobilized in a plaster jacket. His rehabilitation was uneventful and he was discharged 9 weeks after the accident. The initial scan, obtained in June 1984, showed severe spinal stenosis secondary to displaced bony fragments (Figs. 1A–1D). Follow-up CT in March 1986 (21 months after the initial scan) showed resorption of displaced bone fragments and spontaneous correction of the spinal stenosis (Figs. 1E–1H).

Case 2

A 29-year-old man was knocked down by a heavy door that fell across his back. There was no loss of consciousness, but he could not feel or move his legs. On admission the neurologic deficit was charted at Frankel grade A. He was treated posturally with an extension pillow and intermittent catheterization. One week after admission he developed a deep venous thrombosis with pulmonary embolism. This was treated with anticoagulation therapy. Six weeks after the initial injury he was gradually mobilized in a plaster jacket and was finally discharged after being fitted with braces for his legs and elbow crutches. He has been taught to walk using the crutches and braces. The total hospital stay was 11 weeks. The initial scan, obtained in December 1983, revealed a burst-dispersion fracture of the T12 vertebral body with large bone fragments within the canal, causing almost total obliteration of the spinal canal (Figs. 2A–2D). Repeat scan in April 1986 (28 months after the injury) showed considerable spontaneous correction of the spinal canal stenosis (Figs. 2E–2H). The patient's neurologic status had improved and was charted at Frankel grade D in April 1986.

Case 3

A 16-year-old boy fell off his motorcycle and landed on his hands and knees. Immediately after impact he noted total

_E_, Lateral scanogram showing slices obtained at –5° gantry angle.
_F–H_, Follow-up CT scans (March 1986) 21 months after initial injury. Contiguous 4-mm sections showing resorption of posteriorly displaced bone fragments (seen on CT scans of June 1984) with spontaneous correction of spinal stenosis.

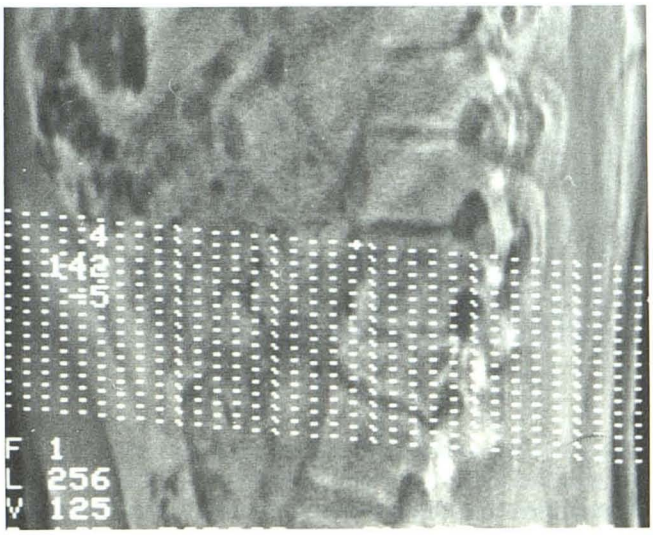

E

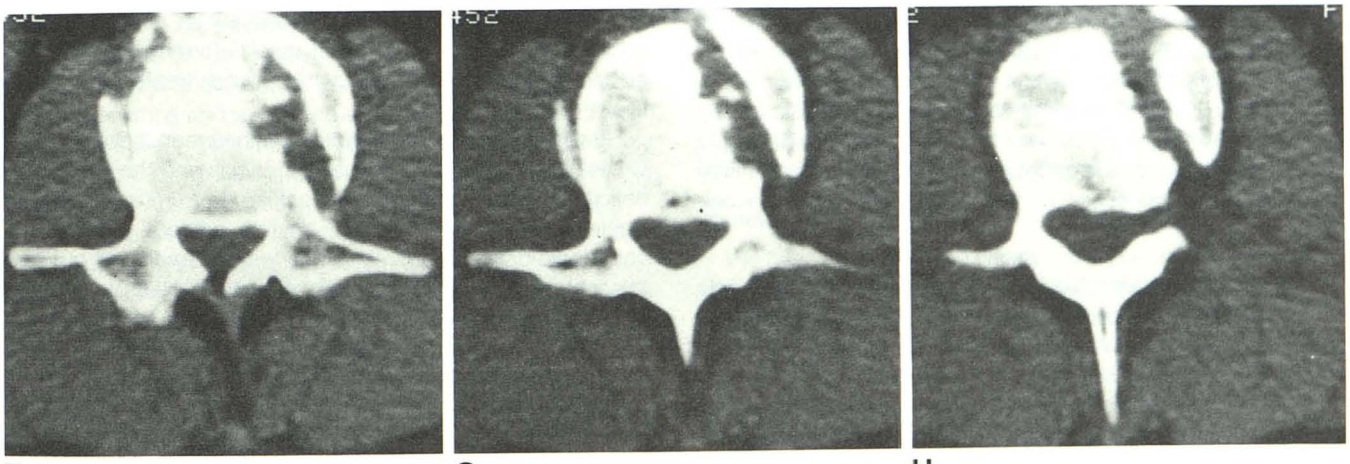

F G H

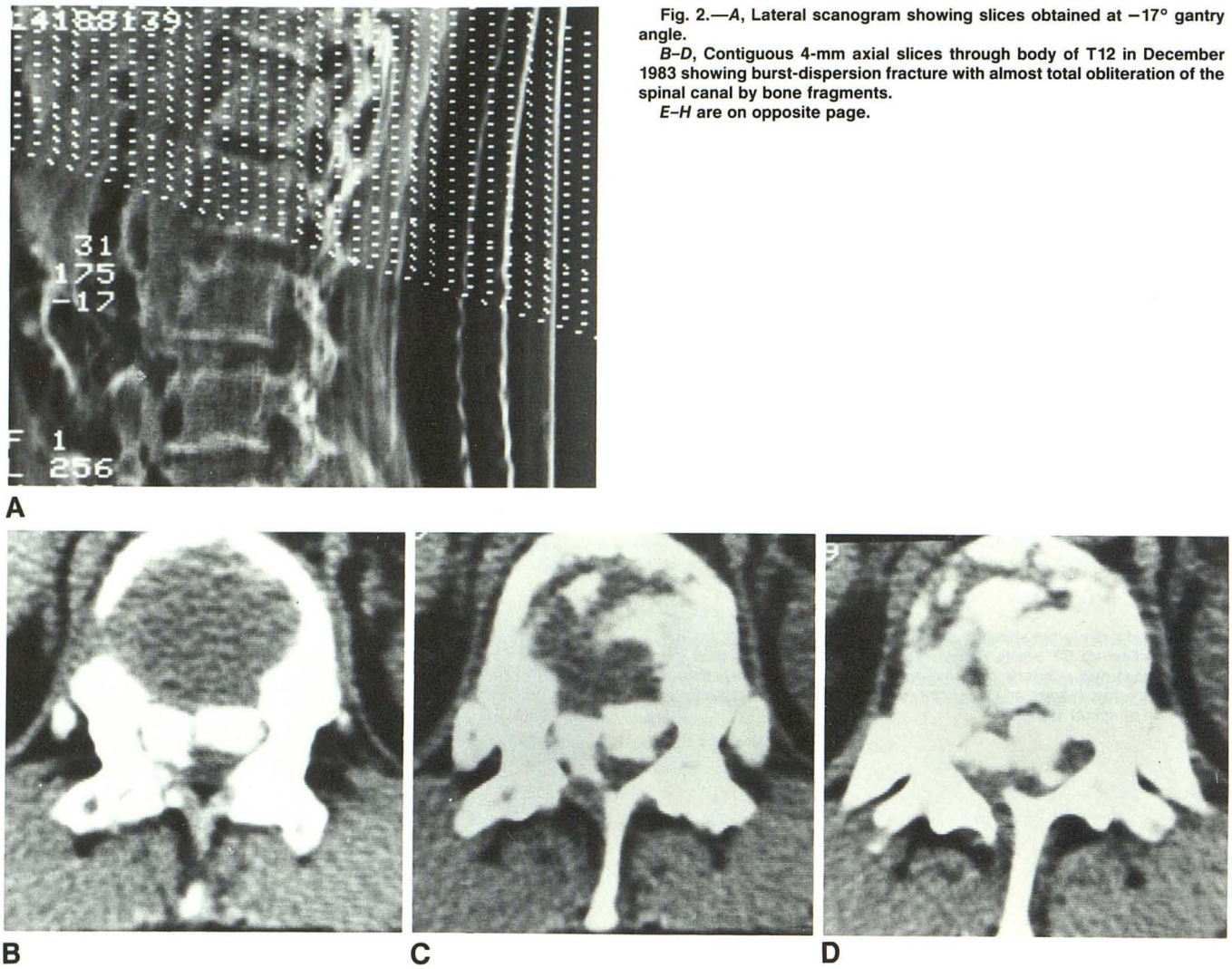

Fig. 2.—*A*, Lateral scanogram showing slices obtained at −17° gantry angle.

***B–D*, Contiguous 4-mm axial slices through body of T12 in December 1983 showing burst-dispersion fracture with almost total obliteration of the spinal canal by bone fragments.**

***E–H* are on opposite page.**

loss of power and feeling in both his legs. Bowel and bladder were normal. The initial scan, obtained in July 1985, revealed a burst-dispersion fracture of the L2 vertebral body with large posteriorly displaced fragments protruding into the spinal canal causing significant stenosis (Figs. 3A–3D). The patient's neurologic deficit was charted at Frankel grade D. Follow-up scan in March 1986 (9 months later) showed dramatic spontaneous resolution of the canal stenosis at the fracture site (Figs. 3E–3H). At follow-up he was neurologically completely intact (Frankel grade E). He was treated posturally with slight extension posturing side to back to side for 3 weeks and then mobilized in a plaster jacket and discharged home a week later.

The neurologic deficit has improved in all our conservatively (nonsurgically) managed patients (Table 2). However, in our series of nonsurgically treated patients there were two patients (one with lumbosacral fracture and the other with sacral fracture) who showed no change in morphology of the spinal canal on the follow-up CT scan. Both had minor spinal deformities and minimal neurologic lesions.

Discussion

Controversy surrounds the management of burst-dispersion fractures of the vertebral column. Our results suggest that "anatomic restoration" of the spinal canal with surgery after such injury may not be necessary in all cases since spontaneous resolution of spinal canal deformity by resorption of bone fragments can occur in patients treated conservatively.

However, evidence of a relationship between the magnitude of the spinal canal deformity and stenosis and the neurologic deficit in such cases has been lacking. In our conservatively treated patients (in extension posture without traction) the neurologic deficit improved in every case, and in all but two this matched the bony change in magnitude. Neurologic progress was assessed according to the Frankel grading in use at Stoke Mandeville Hospital in the United Kingdom. The Frankel grades of neurologic deficit are as follows:

1. A: complete. This means the lesion is found to be complete (both motor and sensory) below the level of the lesion.

***E*, Lateral scanogram on follow-up CT showing slices obtained at −5° gantry angle.**

***F–H*, Similar series of 4-mm axial slices through T12 in April 1986 (28 months later) showing dramatic correction of focal spinal stenosis secondary to spontaneous resorption of displaced bone fragments.**

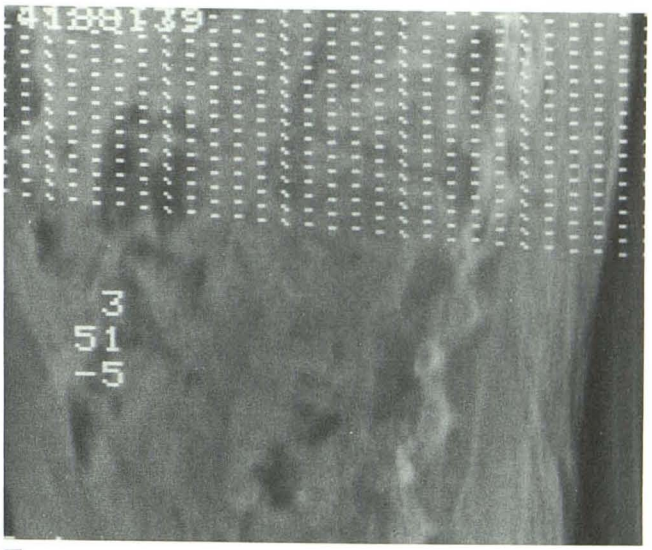

E

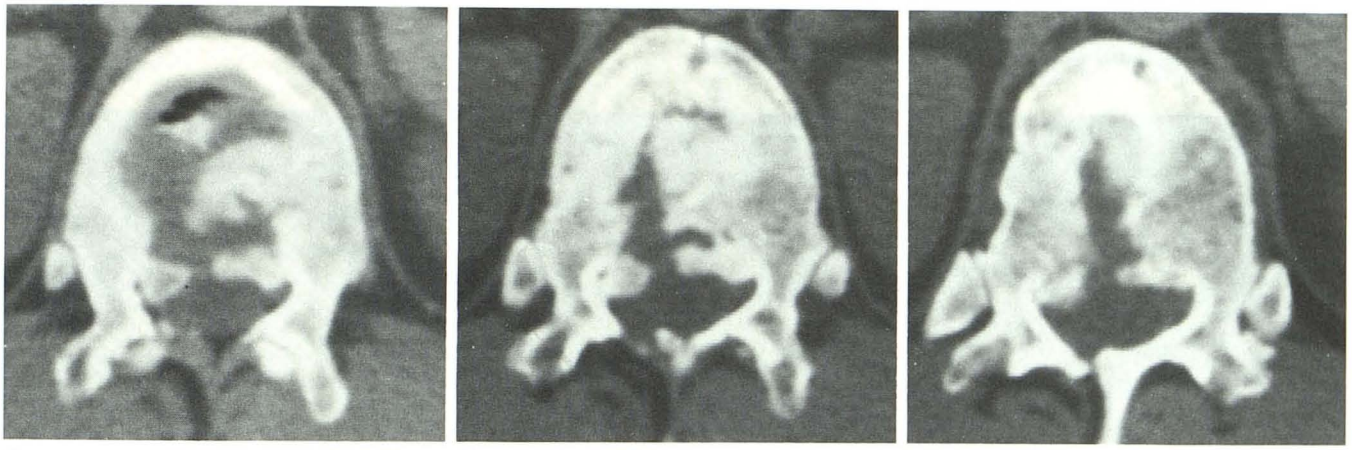

F G H

2. B: sensory only. This implies there is some sensation present below the level of the lesion but that the motor paralysis is complete below that level.

3. C: motor useless. This implies there is some motor power present below the level of the lesion but it is of no practical use to the patient.

4. D: motor useful. This implies there is useful motor power below the level of the lesion. Patients in this group can move their lower limbs and many can walk, with or without aids.

5. E: recovery. This means the patient is free of neurologic symptoms; i.e., no weakness, no sensory loss, no sphincter disturbance. Abnormal reflexes may be present.

In many cases it was not possible to correlate the time-course of bone change in the patient's recovery. However, in those cases scanned serially, increasing resolution of stenosis was identifiable during the period of neurologic improvement. Since the patients reported were treated conservatively, we cannot comment whether the posterior longitudinal ligament was intact or not, and hence we do not know what, if any, contribution is made by the posterior longitudinal ligament in helping to restore the normal configuration. It is accepted that some degree of repositioning of the posteriorly displaced fragments may occur during conservative treatment in the extension posture. However, careful study of our cases leads us to believe that the major factor contributing to reduction in osseous stenosis is spontaneous resorption of displaced bone fragments. The contribution made by damaged intervertebral disk and resolving epidural hematoma to initial neurologic deficit and subsequent recovery is difficult to estimate at present. However, it is hoped that MR imaging will increase our understanding of the mechanism of initial neurologic deficit and subsequent recovery in acute spinal trauma.

Conclusions

We have demonstrated clearly that spontaneous correction of focal spinal stenosis and deformity associated with burst-dispersion fractures of dorsolumbar vertebrae may occur in some patients. Our patients also showed significant neurologic improvement without any corrective surgery. In view of these new findings we would like to suggest that the role of surgical correction of spinal canal deformity associated with spinal burst-dispersion fractures be reevaluated.

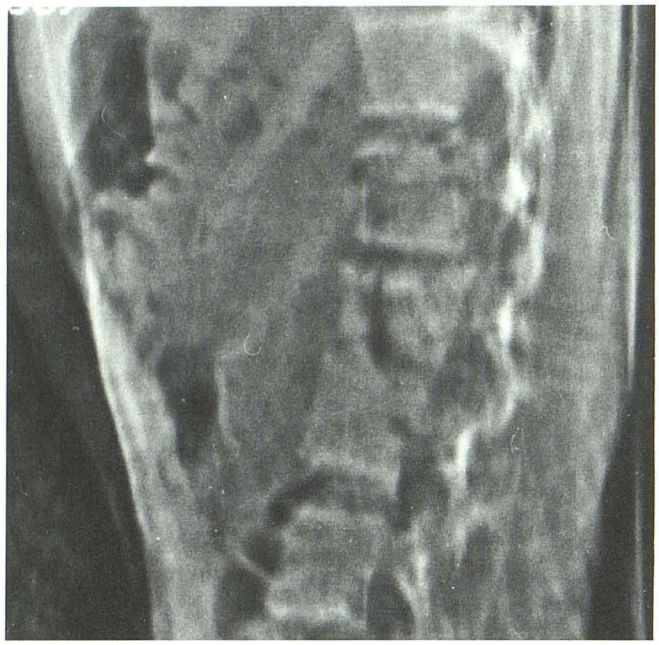

A

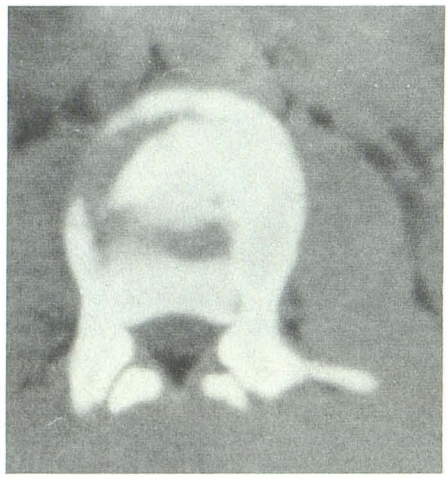

B

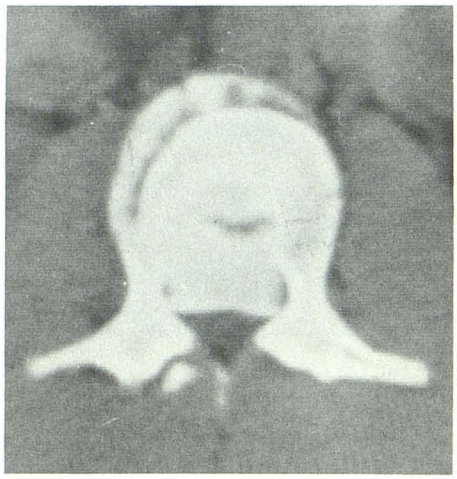

C

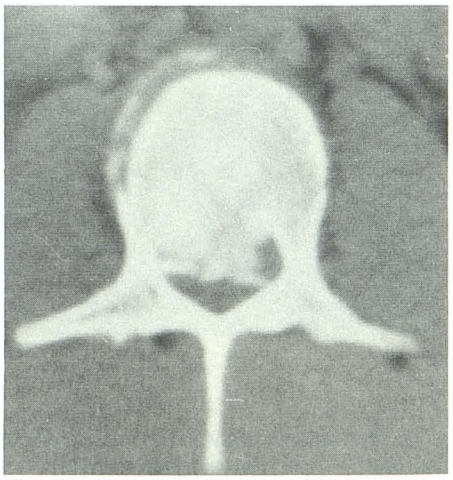

D

Fig. 3.—*A*, Lateral scanogram showing initial spinal deformity.

***B–D*, CT scans (July 1985). Contiguous 4-mm sections through L2 vertebral body showing posteriorly displaced bone fragments causing focal stenosis.**

***E–H* are on opposite page.**

***E*, Lateral scanogram showing spontaneous correction of spinal deformity at fracture site.**

***F–H*, Contiguous 4-mm axial slices from follow-up CT (March 1986) 9 months after initial injury showing remarkable spontaneous correction of stenosis at fracture site.**

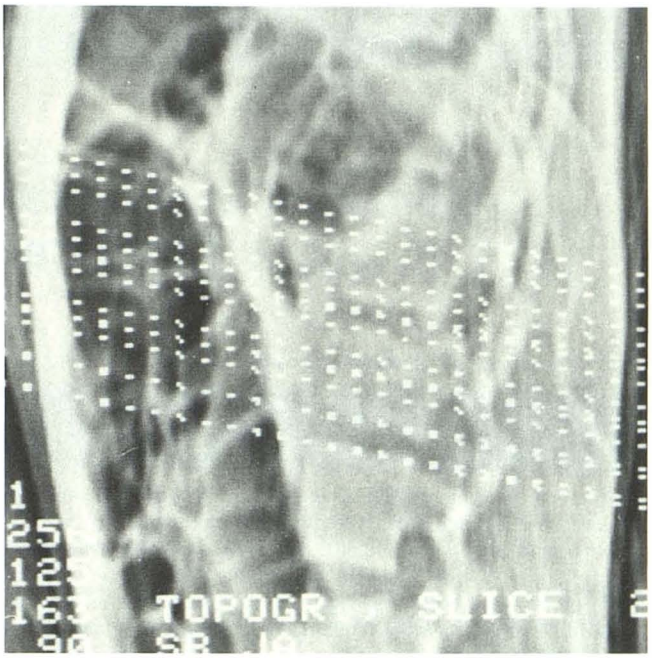

E

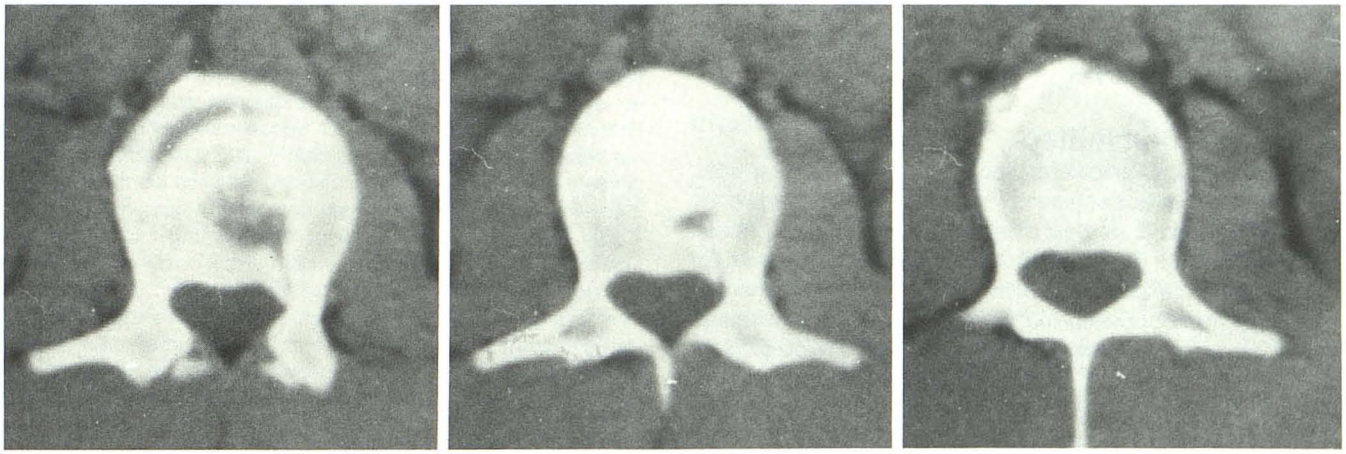

F G H

TABLE 2: Neurologic Change (Frankel Classification)

Frankel Grade	On Admission	At Follow-up
A	1	—
B	2	—
C	4	1
D	8	11
E	—	3
Total	15	15

REFERENCES

1. Brant-Zawadzki M, Miller EM, Federle MP. CT in the evaluation of spine trauma. *AJR* **1981**;136:369–375
2. Brant-Zawadzki M, Jeffrey B Jr, Minagi H, Pitts L. High resolution CT of thoraco-lumbar fractures. *AJNR* **1982**;3:69–74
3. Holdsworth F. Fractures, dislocations and fracture dislocations of spine. *J Bone Joint Surg [Am]* **1970**;32:1534–1551
4. Lindahl S, Willen J, Nordwall A, Istram L. The crush-cleavage fracture. A "new" thoraco-lumbar unstable fracture. *Spine* **1983**;8:559–569
5. Whitesides TE, Ali Shah SG. On the management of unstable fractures of the thoraco-lumbar spine. Rationale for use of anterior decompression, fusion and posterior stabilization. *Spine* **1976**;1:99–107
6. Grant JMF, Sears WR. Spinal injury and computerised tomography: a review of fracture pathology and a new approach to canal decompression. *Aust NZ J Surg* **1986**;56:299–307
7. Frankel HL, Hancock DO, Hyslop G, et al. The value of postural reduction in the initial management of closed injuries of the spine with paraplegia and tetraplegia. *Paraplegia* **1970**;7:179–192