

Are your **MRI contrast agents** cost-effective?

Learn more about generic **Gadolinium-Based Contrast Agents**.



FRESENIUS
KABI

caring for life

AJNR

**High-Resolution MR Imaging of Microadenomas
at 1.5 T: Experience with Cushing Disease**

Wallace W. Peck, William P. Dillon, David Norman, T. H.
Newton and Charles B. Wilson

AJNR Am J Neuroradiol 1988, 9 (6) 1085-1091

<http://www.ajnr.org/content/9/6/1085>

This information is current as
of May 12, 2024.

High-Resolution MR Imaging of Microadenomas at 1.5 T: Experience with Cushing Disease

Wallace W. Peck¹
 William P. Dillon¹
 David Norman¹
 T. H. Newton¹
 Charles B. Wilson²

The MR images of 27 patients with clinically and biochemically suspected Cushing disease were evaluated retrospectively in a blinded fashion. The MR interpretation was compared with detailed operative diagrams and operative and pathologic reports. The examinations were performed on a 1.5-T MR system with thin-section sagittal and coronal T1-weighted (short TR/TE) images. Each pituitary half was considered separately (54 "halves"). Twenty-one pituitary halves were considered to have glandular abnormalities on MR. Compared with surgical findings, 17 MR findings were true positives and four were false positives (one pars intermedia cyst, three normal tissue). Of the 33 pituitary halves considered normal on MR, 26 were true negatives and seven were false negatives. MR had an overall sensitivity of 71% and a specificity of 87% for these adrenocorticotrophic hormone (ACTH)-secreting pituitary adenomas. A focal glandular hypointensity identified on coronal images was the most sensitive predictor of adenoma location. Sagittal images were not useful in either detection or localization. Upward convexity of the gland and deviation of the stalk were less useful indicators. Abnormalities of the sellar floor were the least reliable.

In comparison with the capabilities of CT detection of microadenomas described in the current literature, it appears that high-field thin-section MR of the sella is the most sensitive imaging method for preoperative localization of ACTH-secreting adenomas in patients with Cushing disease.

Cushing syndrome is characterized by hypercortisolism leading to typical clinical features including, but not limited to, obesity, hypertension, hirsutism, ecchymoses, menstrual irregularities, cutaneous striae, acne, and fatigue. Cushing disease is characterized by hypersecretion of adrenocorticotrophic hormone (ACTH) by the pituitary gland with secondary bilateral adrenal cortical hyperplasia [1]. Pituitary adenomas are estimated to be present in 60–96% of these patients [2–4]. As a rule these adenomas are 10 mm in diameter or smaller (microadenomas) [3, 4]. Previous studies that used thin-section contrast-enhanced CT of the sella for preoperative localization of these tumors have reported disappointing results [5–10]. The value of MR imaging in the evaluation of sellar and parasellar diseases has recently been emphasized [11–15]. Our purpose was to determine the sensitivity and specificity of thin-section high-field MR in Cushing disease.

Materials and Methods

Twenty-seven patients with a clinical diagnosis of Cushing disease were evaluated preoperatively with MR examination of the sella from January 1985 to March 1987. The diagnosis of Cushing disease was established before MR examination by (1) an abnormal response to the dexamethasone suppression test [3, 4] as reflected in nonsuppressibility of steroids in plasma and/or urine by the administration of low-dose dexamethasone, or some suppressability with high-dose dexamethasone, and (2) normal or slightly elevated plasma levels of ACTH as determined by immunoassay techniques in the presence of hypercortisolism. All patients had transsphenoidal surgery, performed by a single neurosurgeon, subsequent to MR examination. When abnormal tissue was evident at the surface of the normal anterior

This article appears in the November/December 1988 issue of *AJNR* and the January 1989 issue of *AJR*.

Received February 17, 1988; accepted after revision June 16, 1988.

¹ Department of Radiology, University of California, San Francisco, 505 Parnassus Ave., San Francisco, CA 94143. Address reprint requests to W. P. Dillon.

² Department of Neurosurgery, University of California, San Francisco, San Francisco, CA 94143.

AJNR 9:1085–1091, November/December 1988
 0195–6108/88/0906–1085

© American Society of Neuroradiology

lobe, this tissue was selectively resected and the tumor bed cauterized with an absorbable gelatin sponge (Gelfoam) soaked in absolute alcohol. When no tumor was evident by direct inspection, the pituitary was explored with a series of horizontal and vertical incisions. When the tumor was located, the margins of the incision were separated, abnormal tissue was resected, and the cavity was cauterized with absolute alcohol. When the margin between adenoma and the adjacent pituitary gland was sharp and distinct, no normal pituitary tissue was removed. When the preoperative MR study correctly localized the tumor, the surgeon would not routinely examine the remaining pituitary tissue, as the incidence of simultaneous pituitary neoplasms is extremely small. When surgical exploration of the pituitary gland revealed no abnormal tissue (nine patients), a total hypophysectomy (six patients) or biopsy (three patients) was performed. All specimens were subject to pathologic review. Adenomas demonstrated a homogeneous cell population and stained selectively for ACTH with immunohistologic techniques. If an adenoma could not be identified, reticulic stains were used to rule out pituitary hyperplasia.

MR images were obtained with a 1.5-T system.* T1-weighted 3-mm-thick sagittal and coronal spin-echo images, 600/20/4 (TR/TE/excitations), were obtained by using a 20-cm field of view, a 256 × 256 matrix, and an interslice gap of 0.3 mm (10%). Five patients had preoperative contrast-enhanced CT and six patients had an inferior petrosal sinus sampling.

The scans were retrospectively reviewed in consensus by four neuroradiologists who were aware that the patients had a diagnosis of Cushing disease with subsequent transsphenoidal surgery. The results of surgery, pathologic examination, and contrast-enhanced CT or venous sampling were not known at the time of the review. The presence or absence of an abnormality was determined for the left and right halves of each pituitary gland. Thus, 54 pituitary halves were evaluated in 27 patients. The MR image was considered positive only if the pituitary gland contained a focal area of low signal and/or focal enlargement. The size of the adenoma, position of the stalk, sloping of the sellar floor, and possible involvement of the cavernous sinus were also recorded. The surgical and pathologic reports were reviewed and correlated with the MR findings. Because a positive or negative score was recorded for each half of the pituitary gland, sensitivity and specificity were calculated. For example, if the consensus was that an adenoma was present on the left, but one was found on the right, then the result of the left side was a false positive and on the right side a false negative.

Results

The group of 27 patients comprised 21 females and six males with a mean age of 35 years (range, 14–56 years). Adenomas were pathologically confirmed in 24 patients (89%) (Table 1). Neither a discrete adenoma nor pituitary hyperplasia was identified in the remaining three patients (two total hypophysectomies, one biopsy). A "white, watery" lesion ranging from 1.5 to 10 mm in diameter (mean, 5 mm) typical of an ACTH-producing adenoma was resected and confirmed pathologically in 18 patients. Six (mean age, 46) of nine patients who had negative explorations had total hypophysectomies. Small (1–2 mm) adenomas were found on histologic analysis in four of these six patients. The remaining two glands were normal. Pituitary glands in the three remaining negative explorations (mean age, 20) were biopsied. In two of the three

TABLE 1: Surgical Results in Patients with Cushing Disease

Finding	No. of Patients (n = 27)
Pathologically proved adenoma	24
Adenoma found at surgery	18
Negative exploration:	
Total hypophysectomy:	
Adenoma	4
Normal	2
Subtotal	6
Biopsy:	
Adenoma	2
Normal	1
Subtotal	3
Total	9

TABLE 2: MR and Surgical Correlation in 27 Patients with Cushing Disease

MR Finding: Surgical Determination	No. of Pituitary Halves
Abnormal (19 patients):	
Adenoma:	
Hypointense	14
Isointense	3
Subtotal (true positive)	17
Pars intermedia cyst	1
Normal	3
Subtotal (false positive)	4
Total	21
Normal (25 patients):	
Normal (true negative)	26
Adenoma (false negative)	7
Total	33

Note.—Sensitivity = true positive/(true positive + false negative) = 17/(17 + 7) = 71%; specificity = true negative/(true negative + false positive) = 26/(26 + 4) = 87%.

TABLE 3: MR Observations in Surgically Verified Cushing Adenoma

Finding	
Mean size (range) of adenoma (in mm):	
MR	6.0 (3.0–10)
Surgery	4.6 (1.5–10)
Stalk deviation:	
Contralateral	12
Midline	8
Ipsilateral	4
Sloped sellar floor:	
Ipsilateral	5
Straight	15
Contralateral	4
Cavernous invasion on MR:	
False negative	4
False positive	1

* General Electric, Milwaukee, WI.

patients, the biopsies were in areas considered to be abnormal on the MR image. On histologic examination an adenoma was identified in both patients. In the third patient (normal MR image), a discolored area within the pituitary gland was biopsied but was histologically normal. These data are summarized in Table 1.

The MR results are summarized and correlated with surgical findings in Table 2. Table 3 summarizes some secondary MR observations. Twenty-one pituitary halves exhibited focal abnormalities on MR images in 19 patients (in two patients focal lesions were identified on each side of the gland) on the coronal images (Tables 2 and 3). The sagittal images were much less useful in detecting abnormalities. Seventeen (81%) of these twenty-one focal abnormalities (14 hypointense and three isointense on MR) were adenomas (Figs. 1–3), one (low intensity) was a pars intermedia cyst, and three (14%) (two

isointense, one hypointense) were normal (Figs. 4 and 5). No signal intensity or morphologic differences were noted among these lesions on T1-weighted studies. Since T2-weighted sequences were not routinely obtained, we do not know if these lesions could have been differentiated further. These results were expressed as 17 (81%) true positives and four (19%) false positives. Thirty-three pituitary halves were considered normal: 16 were from the eight patients with completely normal studies and 17 from the patients considered to have a focal lesion on the contralateral side (Table 2). At surgery and/or pathology, seven (21%) of these 33 halves contained adenomas (seven false negatives) ranging from 1.5 to 6 mm in diameter (mean, 3.5 mm) (Figs. 5 and 6). The remaining 26 halves were all true negatives (Fig. 7). The overall sensitivity of MR in detecting ACTH-secreting adenomas was 71% and the specificity was 87%.

Fig. 1.—17-year-old woman with Cushing disease. T1-weighted coronal images, 600/20.

A, Right-sided 4-mm low signal intensity abuts medial dural reflection of cavernous sinus (*arrow*). Left half of gland is normal.

B, More posterior cut. Pituitary stalk is midline (*long arrows*). High signal intensity (*short arrows*) of posterior pituitary is a normal finding.

At surgery, low-intensity focus corresponded to 3-mm right-sided ACTH-secreting adenoma (right half = true positive; left half = true negative).

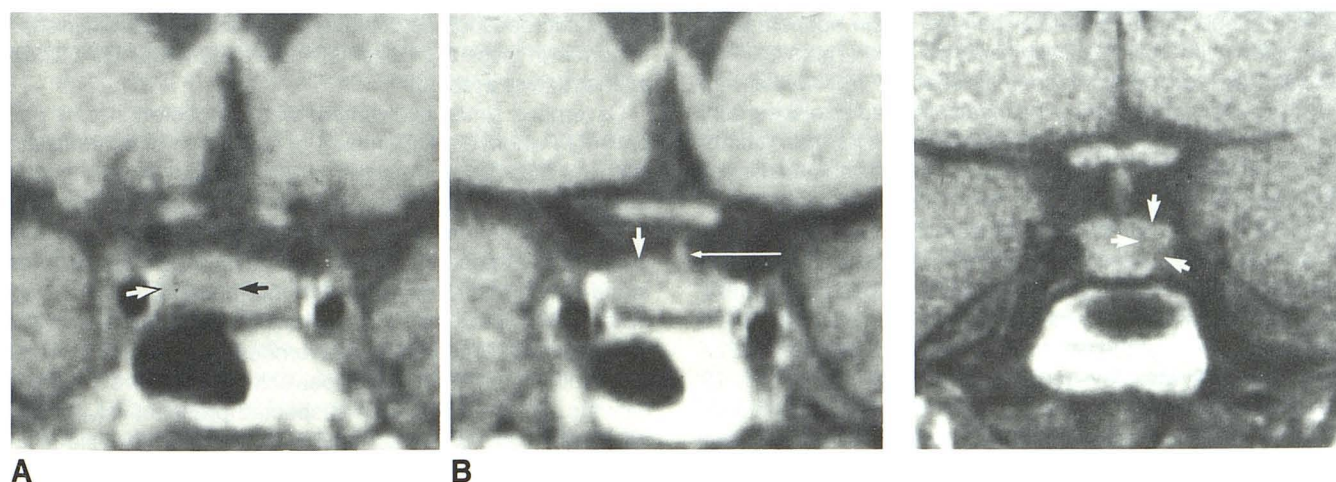
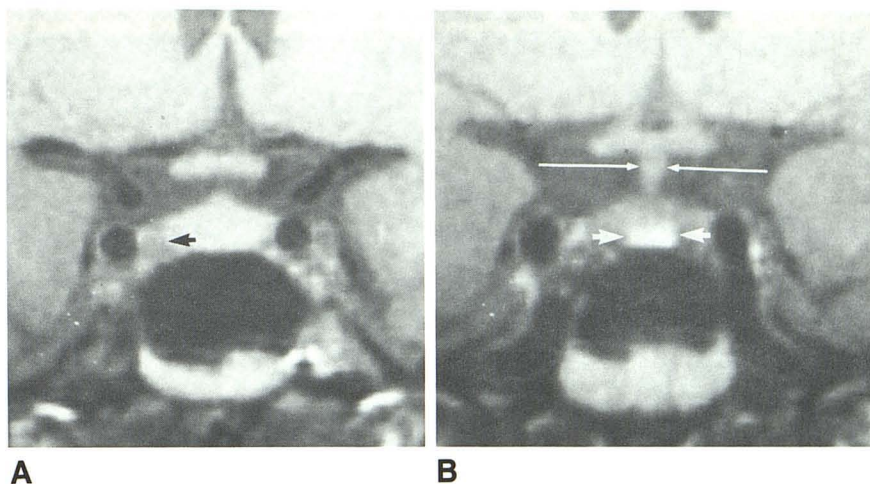


Fig. 2.—A and B, 29-year-old woman with Cushing disease. T1-weighted coronal images, 600/20, show right-sided 9-mm hypointense adenoma (*short arrows*) with slight upward convexity of pituitary gland. B (3 mm posterior to A) also shows slight leftward shift of pituitary stalk (*long arrow*). At surgery, low-intensity focus corresponded to 8-mm right-sided ACTH-secreting adenoma. (Right half = true positive; left half = true negative.)

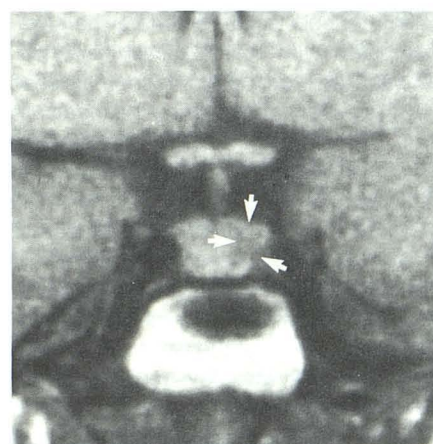


Fig. 3.—30-year-old woman with Cushing disease. T1-weighted coronal image, 600/20, shows poorly margined left-sided hypointensity measuring 8 mm in diameter (*arrows*) with normal midline stalk. At surgery, low-intensity focus corresponded to left-sided 5-mm ACTH-secreting adenoma. (Left half = true positive; right half = true negative.)

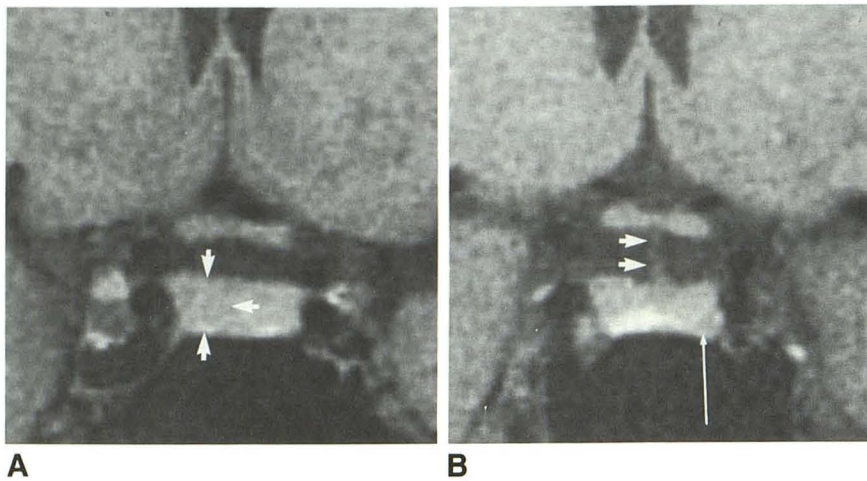


Fig. 4.—27-year-old woman with Cushing disease. T1-weighted coronal images, 600/20.

A, Poorly defined right-sided 5-mm low-intensity area with slight upward convexity of pituitary gland (arrows).

B, Adjacent posterior section shows 3-mm focus of low signal in left posterolateral wing adjacent to medial dural reflection of cavernous sinus (long arrow). Pituitary stalk is shifted slightly to left (short arrows).

At surgery, 3-mm right-sided adenoma was identified corresponding to low-intensity lesion seen on MR. Left side was normal. (Right half = true positive; left half = false positive.)

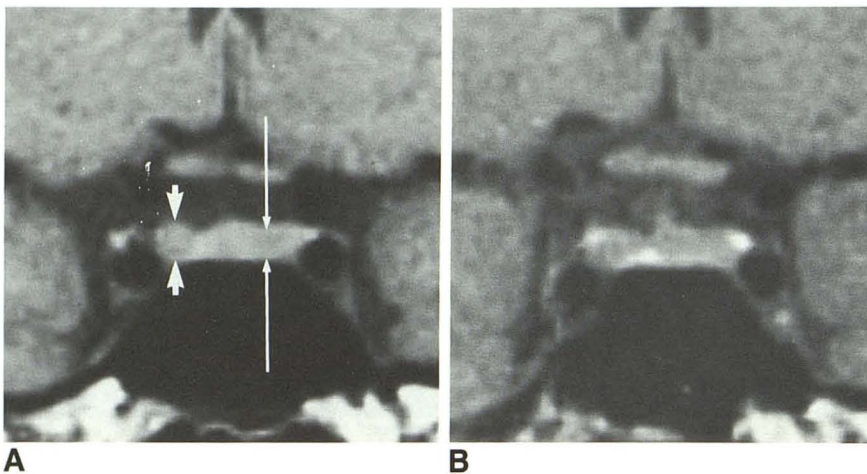


Fig. 5.—A and B, 38-year-old woman with Cushing disease. T1-weighted coronal images, 600/20. Well-defined prospectively identified 4-mm focus of low signal in right lateral wing, adjacent to medial dural reflection of cavernous sinus (short arrows). Less well defined 5-mm region of low signal on left (long arrows) not identified prospectively. Stalk is midline. At surgery, right side was normal, and 6-mm ACTH-secreting adenoma was found in left lateral wing, corresponding to low intensity identified (long arrows). (Right half = false positive; left half = false negative.)

MR tended to overestimate the size of the adenomas as compared with the surgically reported size (Table 3). The average size of the 17 adenomas seen on MR was 6 mm (range, 3–10 mm), whereas the mean reported size at surgery was 4.6 mm (range, 1.5–10 mm). The reason for this discrepancy is uncertain. In the data analysis, the adenomas missed at surgery were all assumed to be smaller than 2 mm.

Secondary findings of mass effect supported the diagnosis in some of the 24 cases of adenoma: The sellar floor sloped ipsilateral to the adenoma in five patients, sloped contralateral to the adenoma in four patients, and was straight in 15 patients. Erosion of the lamina dura could not be identified on MR. The stalk was deviated away from the adenoma in 12 patients (50%), was deviated toward the adenoma in four patients, and was midline in eight patients (Table 3). In two of the three adenomas that were isointense, the stalk was deviated away from the adenoma. In two patients suspicious lesions were identified in both halves of their glands. Stalk deviation to the contralateral side correctly identified the side of the adenoma in both these patients. However, surgical confirmation of the second abnormality was not obtained, because once an adenoma is encountered, the remaining gland is not routinely explored owing to the rarity of simulta-

neous microadenomas. Follow-up prolactin levels diminished to normal in these two patients, and we presume only a single adenoma was present.

Cavernous sinus involvement was suspected in only one patient in whom a small amount of soft tissue of intermediate intensity was found adjacent to the intracavernous carotid artery. This soft tissue was directly contiguous with a focal low-intensity abnormality in the pituitary. At surgery, this side was normal; the adenoma (without cavernous invasion) was found on the contralateral side. In four patients, it was determined at surgery that the adenoma was adherent to the medial dural reflection of the cavernous sinus (Table 3). Total resection of the tumor was possible in only two of these patients. This had not been suspected prospectively, and in retrospect there were no findings to suggest possible invasion.

Sampling of the inferior petrosal sinuses correctly predicted tumor location in five of six patients. In one patient, ACTH levels were slightly higher on the normal side. Thin-section, high-resolution contrast-enhanced CT yielded three true positives, one false negative, and one true negative. The MR findings in these five patients were four true positives and one true negative.

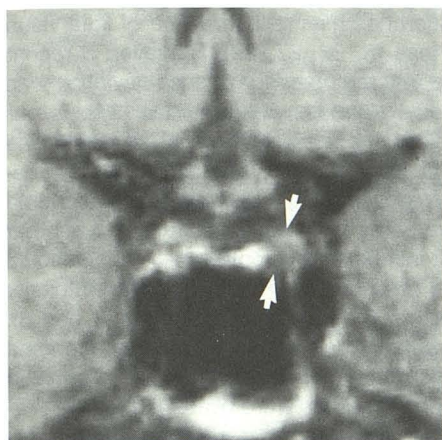


Fig. 6.—32-year-old woman 2 years after trans-sphenoidal surgery for Cushing disease. Persistent symptoms initiated reevaluation. T1-weighted coronal image, 600/20, was prospectively called normal with a midline stalk. In retrospect, there is a well-defined 4-mm low-intensity focus on left adjacent to cavernous sinus (arrows). Preoperative inferior petrosal sinus sampling showed abnormal ACTH elevation on left. At surgery, low-intensity focus corresponded to 4-mm left-sided ACTH-secreting adenoma. (Right half = true negative; left half = false negative.)

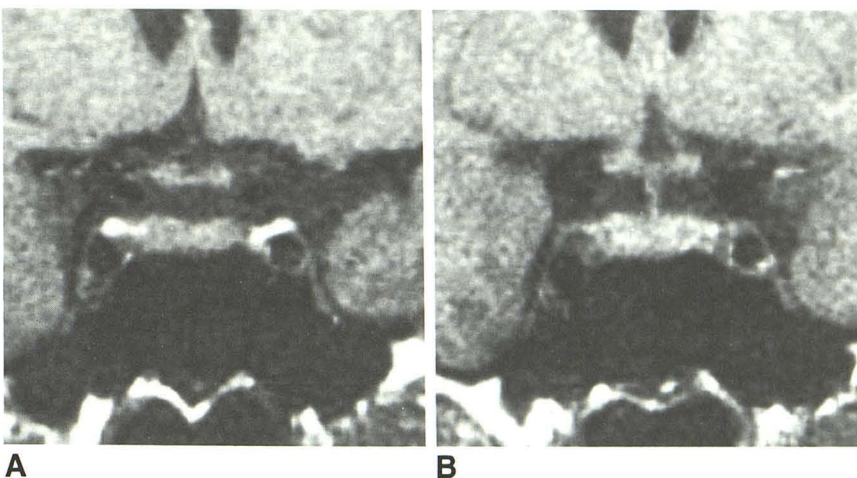


Fig. 7.—A and B, 41-year-old man with Cushing disease. T1-weighted coronal images, 600/20. Normal anterior lobe. Stalk is midline. Total hypophysectomy was performed after negative exploration. At final pathology, only normal pituitary gland was identified. (Left half = true negative; right half = true negative.)

Discussion

Pituitary adenomas constitute approximately 10% of all symptomatic brain tumors [16]. They may be classified as nonsecreting or secreting. The former are always macroadenomas and cause signs or symptoms secondary to either local mass effect or pituitary secretory failure. Secretory adenomas typically are smaller and usually have one of three clinical features: (1) acromegaly (growth hormone-secreting adenomas), (2) amenorrhea and/or galactorrhea in women or decreased libido in men (prolactinomas), or (3) Cushing syndrome (ACTH-secreting adenomas).

Hypersecretion of ACTH in Cushing syndrome originates either in the pituitary (Cushing disease) or in an ectopic ACTH-secreting tumor. ACTH secretion from a pituitary adenoma usually is not suppressed by small doses of dexamethasone but is suppressed by large doses of dexamethasone. By contrast, ACTH secretion from ectopic ACTH-producing tumors usually is autonomous and should lack inhibitory control by plasma cortisol. In one clinical series, however, a large dose of dexamethasone did produce suppression in 19% of patients with ectopic ACTH-producing tumors [17].

Pituitary adenomas (predominantly microadenomas) are reported in 60–96% of patients with Cushing disease [2–4]. Abnormal hypothalamic-pituitary function may be responsible for the hypersecretion of ACTH in the remainder of patients [18, 19]. Transsphenoidal resection of the adenoma currently is believed to be the therapeutic procedure of choice [4, 17]. The fact that most but not all patients with a positive dexamethasone suppression test have a pituitary tumor and that the hypothalamus may be the source of hypersecretion justifies

the need for an imaging technique that accurately localizes a lesion within the sella.

The sensitivity of CT in detecting pituitary adenomas is influenced by the size of the tumor, the quality of equipment, the imaging technique, the amount of iodinated contrast material, and the method of contrast administration. Although somewhat variable, routine rapid-drip-infusion contrast-enhanced CT studies generally demonstrate microadenomas as being lower in density and macroadenomas as being higher in density than the adjacent pituitary gland. The sensitivity of CT in detecting macroadenomas is reported to be as high as 100% [20]. Microadenomas (tumors 10 mm in diameter or smaller) traditionally have been more difficult to detect. This was especially true for lesions smaller than 5 mm [6]. With high-resolution CT, Marcovitz et al. [20, 21] recently reported a sensitivity of 81.2% for growth-hormone microadenomas and a sensitivity of 91.9% for prolactin microadenomas. The vast majority of the growth-hormone microadenomas were larger than 5 mm, whereas the prolactin microadenomas had a broader range of sizes with equal numbers being larger and smaller than 5 mm. The literature would suggest that prolactinomas in general are easier to detect on CT than are most adenomas [22]. False-positive rates vary from 25 to 50% for microadenomas [6, 22]. Focal low densities that can simulate a pituitary microadenoma include pars intermedia cysts or high-spatial-frequency artifacts [23].

About 73–88% of ACTH-secreting tumors are microadenomas [3, 10]. Cushing adenomas traditionally have been very difficult to detect with CT. This may relate to the contrast enhancement characteristics of the tumor. In a series of 14 patients with Cushing disease, Teasdale et al. [6] reported

detection by CT in eight (57%) of 14 patients. A recent investigation of 50 patients with surgically verified Cushing adenomas reported an overall 30% sensitivity with high-resolution thin-section contrast-enhanced CT, but only a 17% sensitivity in the 42 patients with microadenomas [9]. Marcovitz et al. [10] recently reported a sensitivity of 63% and specificity of 62.5% for ACTH-secreting adenomas with direct coronal enhanced CT. However, they reported a sensitivity of only 58% for microadenomas. In our series, all lesions found at surgery were less than 10 mm in diameter.

Early reports indicated a poor sensitivity for MR in the detection of pituitary adenomas [5–10]. Images were acquired early in the evolution of MR instruments. Quality was limited by thick sections (greater than 5 mm), lower field strength, and suboptimal signal-to-noise. More recent studies have shown that microadenomas can be detected with MR [14, 15, 24–26]. Kulkarni et al. [26] recently reported a sensitivity of 83% for MR in detecting microadenomas at 1.5 T. This compared with a sensitivity of 42% for CT. In that particular study, only eight of the 37 patients had surgical confirmation via transsphenoidal surgery. On short TR/TE images (T1-weighted), most microadenomas are of low signal relative to that of the normal gland. On long TR/TE images (T2-weighted), the pattern is more variable, with an approximately equal distribution of hypo-, iso-, and hyperintense adenomas being identified relative to the normal pituitary gland [14]. In addition, our experience suggests that T2-weighted images rarely add any practical information to the T1-weighted studies, yet they take considerably longer to acquire. These findings have led to a recommendation we support that T1-weighted images alone be used for the routine evaluation of pituitary adenomas [24], reserving T2-weighted sequences for postoperative patients or those infrequent cases in which a suspected tumor cannot be detected on T1-weighted images alone.

Dwyer et al. [15] recently reported the findings on contrast-enhanced MR and CT in 12 patients with proved Cushing disease. They used a 0.5-T MR imager with 5-mm-thick contiguous slices and compared it with high-resolution, direct coronal CT with 3-mm slices overlapping 1 mm. Short TR images identified eight (67%) adenomas before enhancement and 10 (83%) after gadolinium-DTPA enhancement; contrast-enhanced CT detected four (33%) of the adenomas. Eight (67%) of these were microadenomas, comparing favorably with the sensitivity of 71% noted in our series.

In our series, MR tended to overestimate the surgically reported size of pituitary microadenomas (Fig. 4). In one patient this discrepancy was explained by hypointense scar tissue (resulting from previous transsphenoidal surgery) with a 2-mm microadenoma embedded within it. The explanation for the discrepancy in the remainder of the cases is less certain, but it may have been due in part to a lack of well-defined margins on MR, to peritumoral edema, or to an underestimation of the size of the tumor by the neurosurgeon.

Secondary signs of mass effect were not as helpful as focal-intensity changes within the pituitary gland (Figs. 1, 3, 6, and 7; Table 4). Changes in the floor of the sella are of little value in predicting the site of an adenoma [22]. Sloping of the sellar floor had no correlation with the location of the tumor.

Pituitary stalk deviation has been shown to be of little value for localizing adenomas [6, 22, 27, 28]. However, a recent MR study suggested that the presence of such deviation was helpful to confirm focal glandular abnormalities [14]. In our series, the pituitary stalk was displaced from its normal midline position in 16 patients. In 12 of these 16 patients the displacement of the stalk correctly predicted the side of the adenoma (Fig. 2). Although we agree with Kucharczyk et al. [14] that deviation of the stalk increases the confidence level, it should be discounted in the presence of a clear focal hypointensity on the side ipsilateral to the deviated stalk (Figs. 1 and 3). Stalk deviation proved very useful in localizing the adenoma in the patients in whom the adenomas were isointense or in whom pituitary MR abnormalities were bilateral (Fig. 4).

The predictability of cavernous sinus invasion with the use of MR is poor [29]. One patient in whom involvement of the cavernous sinus was suspected on MR proved to have no such invasion at surgery. In four other patients with surgically proved invasion of the cavernous sinus, no indication of such involvement was seen on MR. MR's poor sensitivity in the detection of cavernous sinus invasion most likely is due to an inability to visualize the very thin medial dural reflection of the cavernous sinus [29].

Our study was performed on a highly selected group of patients. The sensitivity and specificity of MR in the diagnosis of ACTH-secreting microadenomas may be overstated. The patients' preliminary diagnoses of Cushing disease were supported by clinical evaluations and hormonal assays. The probability of an adenoma was high. Although the patient population was skewed, our retrospective review is a realistic representation of the clinical situation at the time MR imaging is required. However, since 10–20% of patients examined at autopsy have asymptomatic adenomas [30] and 10–20% may have benign pituitary cysts [23], a prospective MR study is necessary to evaluate the appearance of the "normal" gland and to determine the true incidence of false-positive studies.

When our review is compared with the CT series cited herein, high-field, thin-section MR appears to be the preferable imaging method in the evaluation of patients with suspected Cushing disease. The technique has the added advantages of no contrast material and no radiation exposure. The radiologic diagnosis rests on the finding of a focal hypointensity or an isointense focal bulge within the pituitary gland on short TR images. Stalk displacement may support the diagnosis, but in the presence of a focal low intensity it should not be used to support a diagnosis of a lesion contralateral to the focal low-signal-intensity region. Gd-DTPA may prove useful in further increasing sensitivity [15]. Inferior petrosal sinus ACTH sampling should be reserved for patients with small or recurrent adenomas that cannot be accurately or confidently localized with planar imaging techniques.

REFERENCES

1. Gold EM. The Cushing syndromes: changing views of diagnosis and treatment. *Ann Intern Med* 1979;90:829–844
2. Robert F, Pelletier G, Hardy J. Pituitary adenomas in Cushing's disease. A histologic, ultrastructural, and immunochemical study. *Arch Pathol Lab Med* 1978;102:448–455
3. Boggan JE, Tyrrell JB, Wilson CB. Transsphenoidal microsurgical manage-

- ment of Cushing's disease. Report of 100 cases. *J Neurosurg* **1983**;59:195-200
4. Tyrrell JB, Brooks RM, Fitzgerald PA, Cofoid PB, Forsham PH, Wilson CB. Cushing's disease. Selective transsphenoidal resection of pituitary microadenomas. *N Engl J Med* **1978**;298:753-758
 5. Pojunas KW, Daniels DL, Williams AL, Thorsen MK, Haughton VM. Pituitary and adrenal CT of Cushing's syndrome. *AJR* **1986**;146:1235-1238
 6. Teasdale E, Teasdale G, Mohsen F, MacPherson P. High-resolution computed tomography in pituitary microadenoma: is seeing believing? *Clin Radiol* **1986**;37:227-232
 7. Valenta LJ, Sostrin RD, Eisenberg H, Tamkin JA, Elias AN. Diagnosis of pituitary tumors by hormone assays and computerized tomography. *Am J Med* **1982**;72:861-873
 8. Hemminghytt S, Kalkhoff RK, Daniels DL, Williams AL, Grogan JP, Haughton VM. Computed tomographic study of hormone-secreting microadenomas. *Radiology* **1983**;146:65-69
 9. Saris SC, Patronas NJ, Doppman JL, et al. Cushing syndrome: pituitary CT scanning. *Radiology* **1987**;162:775-777
 10. Marcovitz S, Wee C, Chan J, Hardy J. The diagnostic accuracy of preoperative CT scanning in the evaluation of pituitary ACTH-secreting adenomas. *AJNR* **1987**;8:641-644
 11. Lee BCP, Deck MDF. Sellar and juxtaseilar lesion detection with MR. *Radiology* **1985**;157:143-147
 12. Bilaniuk LT, Zimmerman RA, Wehrli FW, et al. Magnetic resonance imaging of pituitary lesions using 1.0 to 1.5T field strength. *Radiology* **1984**;153:415-418
 13. Glaser B, Sheinfeld M, Benmair J, Kaplan N. Magnetic resonance imaging of the pituitary gland. *Clin Radiol* **1986**;37:9-14
 14. Kucharczyk W, Davis DO, Kelly WM, Sze G, Norman D, Newton TH. Pituitary adenomas: high-resolution MR imaging at 1.5T. *Radiology* **1986**;161:761-765
 15. Dwyer AJ, Frank JA, Doppman JL, et al. Pituitary adenomas in patients with Cushing's disease: initial experience with Gd-DTPA-enhanced MR imaging. *Radiology* **1987**;163:421-426
 16. Sakoda K, Mukada K, Yonezawa M, et al. CT scans of pituitary adenomas. *Neuroradiology* **1981**;20:249-253
 17. Salassa RM, Law ER, Carpenter PC, Northcutt RC. Transsphenoidal removal of pituitary microadenoma in Cushing's disease. *Mayo Clin Proc* **1975**;53:24-28
 18. Imura H. Ectopic hormone syndromes. *Clin Endocrinol Metab* **1980**;9:235-260
 19. Feldman JM. Cushing's disease: a hypothalamic flush? *N Engl J Med* **1975**;293:930-931
 20. Marcovitz S, Wee R, Chan S, Hardy J. Diagnostic accuracy of preoperative CT scanning of pituitary somatotroph adenomas. *AJNR* **1988**;9:19-22
 21. Marcovitz S, Wee R, Chan J, Hardy J. Diagnostic accuracy of preoperative CT scanning of pituitary prolactinomas. *AJNR* **1988**;9:13-17
 22. Davis PC, Hoffman JC, Tindall GT, Braun IF. Prolactin-secreting pituitary microadenomas: inaccuracy of high-resolution CT imaging. *AJNR* **1984**;5:721-726
 23. Chambers EF, Turski PA, LeMasters D, Newton TH. Regions of low density in the contrast-enhanced pituitary gland: normal and pathologic processes. *Radiology* **1982**;144:109-113
 24. Pojunas KW, Daniels DL, Williams AL, Haughton VM. MR imaging of prolactin-secreting microadenomas. *AJNR* **1986**;7:209-213
 25. Davis PC, Hoffman JC, Spencer T, Tindall GT, Braun IF. MR imaging of pituitary adenoma: CT, clinical, and surgical correlation. *AJR* **1987**;148:797-802
 26. Kulkarni MV, Lee KF, McArdle C, Yeakley JW, Haar FL. 1.5-T MR imaging of pituitary microadenomas: technical considerations and CT correlation. *AJNR* **1988**;9:5-11
 27. Mark L, Pech P, Daniels D, Charles C, Williams A, Haughton V. The pituitary fossa: a correlative anatomic and MR study. *Radiology* **1984**;153:453-457
 28. Raji MR, Kishore PRS, Becker DP. Pituitary microadenoma: a radiological-surgical correlative study. *Radiology* **1981**;139:95-99
 29. Scotti G, Yu C-Y, Dillon WP, et al. MR imaging of cavernous sinus involvement by pituitary adenomas. *AJNR* **1988**;9:657-664, *AJR* **1988**;151:799-806
 30. Burrow GN, Wortzman G, Rewcastle NB, Holgate RC, Kovacs K. Microadenomas of the pituitary and abnormal sellar tomograms in an unselected autopsy series. *N Engl J Med* **1981**;304:156-158