

Are your MRI contrast agents cost-effective?

Learn more about generic Gadolinium-Based Contrast Agents.



AJNR

Extent of Microstructural White Matter Injury in Postconcussive Syndrome Correlates with Impaired Cognitive Reaction Time: A 3T Diffusion Tensor Imaging Study of Mild Traumatic Brain Injury

This information is current as of May 4, 2024.

S.N. Niogi, P. Mukherjee, J. Ghajar, C. Johnson, R.A. Kolster, R. Sarkar, H. Lee, M.R. Meeker, R.D. Zimmerman, G.T. Manley and B.D. McCandliss

AJNR Am J Neuroradiol published online 13 February 2008
<http://www.ajnr.org/content/early/2008/02/13/ajnr.A0970.citation>

Extent of Microstructural White Matter Injury in Postconcussive Syndrome Correlates with Impaired Cognitive Reaction Time: A 3T Diffusion Tensor Imaging Study of Mild Traumatic Brain Injury

ORIGINAL RESEARCH

S.N. Niogi
P. Mukherjee
J. Ghajar
C. Johnson
R.A. Kolster
R. Sarkar
H. Lee
M.R. Meeker
R.D. Zimmerman
G.T. Manley
B.D. McCandliss



BACKGROUND AND PURPOSE: Diffusion tensor imaging (DTI) may be a useful index of microstructural changes implicated in diffuse axonal injury (DAI) linked to persistent postconcussive symptoms, especially in mild traumatic brain injury (TBI), for which conventional MR imaging techniques may lack sensitivity. We hypothesized that for mild TBI, DTI measures of DAI would correlate with impairments in reaction time, whereas the number of focal lesions on conventional 3T MR imaging would not.

MATERIALS AND METHODS: Thirty-four adult patients with mild TBI with persistent symptoms were assessed for DAI by quantifying traumatic microhemorrhages detected on a conventional set of T2*-weighted gradient-echo images and by DTI measures of fractional anisotropy (FA) within a set of a priori regions of interest. FA values 2.5 SDs below the region average, based on a group of 26 healthy control adults, were coded as exhibiting DAI.

RESULTS: DTI measures revealed several predominant regions of damage including the anterior corona radiata (41% of the patients), uncinate fasciculus (29%), genu of the corpus callosum (21%), inferior longitudinal fasciculus (21%), and cingulum bundle (18%). The number of damaged white matter structures as quantified by DTI was significantly correlated with mean reaction time on a simple cognitive task ($r = 0.49$, $P = .012$). In contradistinction, the number of traumatic microhemorrhages was uncorrelated with reaction time ($r = -0.08$, $P = .71$).

CONCLUSION: Microstructural white matter lesions detected by DTI correlate with persistent cognitive deficits in mild TBI, even in populations in which conventional measures do not. DTI measures may thus contribute additional diagnostic information related to DAI.

Traumatic brain injury (TBI) is the leading cause of death and disability in young people, with 1.4 million annually reported cases in the United States and an estimated 57 million people worldwide hospitalized with 1 or more TBIs.¹ Furthermore, approximately 80% of the hospital-reported patients with TBI are categorized as having mild TBI on the basis of a Glasgow Coma Scale score between 13 and 15. Although those patients with mild TBI with normal CT findings and no post-traumatic amnesia usually have complete resolution of post-traumatic symptoms within 1 month, approximately 30% of patients with mild TBI with posttraumatic amnesia have persistent posttraumatic symptoms, and a significant number at 1-year postinjury have decreased functional outcome.^{2,3}

Received October 5, 2007; accepted after revision December 4.

From the Department of Psychiatry (S.N.N., R.A.K., B.D.M.), Sackler Institute, Weill Medical College of Cornell University, New York, NY; Department of Radiology (P.M.), University of California, San Francisco, San Francisco, Calif; Brain Trauma Foundation (J.G., R.A.K., R.S.), New York, NY; Departments of Neurological Surgery (J.G.) and Radiology (C.J., R.D.Z.), Weill Medical College of Cornell University, New York, NY; Department of Neurological Surgery (H.L., M.R.M., G.T.M.), University of California, San Francisco, Calif.

S.N. Niogi and P. Mukherjee contributed equally to this work.

This work was supported by a collaborative grant from the James S. McDonnell Foundation to the Brain Trauma Foundation with lead investigators of the Cognitive Neurobiological Research Consortium from Weill Cornell Medical College, University of California San Francisco, and University of California Berkeley.

Please address correspondence to Bruce D. McCandliss, MD, Sackler Institute, Department of Psychiatry, Weill Medical College of Cornell University, 525 E. 68th St, New York, NY 10065; e-mail: bdm2001@med.cornell.edu

Indicates article with supplemental on-line tables

DOI 10.3174/ajnr.A0970

Structural imaging studies of acute TBI demonstrate that MR imaging is more sensitive than CT in the number of traumatic lesions visualized.⁴ However, the relationship between focal structural lesions detected by conventional MR imaging and long-term patient outcome is controversial.^{3,5-7} Nevertheless, patients with TBI with posttraumatic symptoms often have cognitive impairment, and their cognitive function is a major predictor of poor outcome.⁸⁻¹² In particular, attention, working memory, cognitive manipulation of temporal information, and processing speed are vulnerable.^{13,14} Sequelae of TBI cause significant disability, which compelled the National Institutes of Health (NIH) to declare mild TBI as a major public health problem.¹⁵

Although conventional MR imaging techniques can readily visualize posttraumatic focal structural lesions, they fail to adequately detect diffuse axonal injury (DAI), the key mechanism of damage following TBI.¹⁶ DAI results from unequal rotational or acceleration/deceleration forces that cause multifocal lesions in white matter due to a shear-strain deformation.¹⁷⁻¹⁹ DAI is primarily responsible for transient deficits in cognitive performance in domains such as processing speed, working memory, and attention.^{20,21} More recent studies suggest that DAI causes persistent postconcussive symptoms in executive function and memory dysfunction.^{8,22-25}

MR diffusion tensor imaging (DTI) may be used to better assess DAI. In DTI, the characteristics of water diffusion in the brain are used to assess microstructural integrity of white matter pathways.²⁶ In white matter, water diffuses more readily along the orientation of axonal fibers than across the fibers due

to hindrance from structural elements such as the axolemma and the myelin sheath. One can calculate the apparent diffusion coefficient (ADC), which is a rotationally invariant measure of the magnitude of diffusion. The degree of directionality of diffusion is termed “anisotropy.” This is the variation in the eigenvalues of the diffusion tensor.²⁷ Fractional anisotropy (FA), a normalized measure of anisotropy, has been shown to be sensitive to microstructural changes in white matter integrity.^{28,29} Such measurements quantify the extent of damage following TBI^{24,30-32} and are more sensitive than conventional MR imaging to axonal injury in a mouse model of TBI.³³

In a group of patients with mild TBI with persistent postconcussive symptoms, we tested the hypothesis that the extent of microstructural white matter injury on DTI would account for deficits in cognitive reaction time, whereas the number of focal lesions on conventional MR imaging would not. The purpose of this study was to determine the predominant areas of damage in mild TBI and whether the spatial extent of white matter injury on DTI can be used as an effective biomarker for global cognitive outcome.

Methods

Participants

The group with mild TBI consisted of 34 patients (18 male, 16 female) who had Glasgow Coma Scale scores of 13–15 at the time of injury, loss of consciousness, and posttraumatic amnesia. All subjects with mild TBI were examined at least 1 month postinjury (range, 1–65 months) and had at least 1 persistent postconcussive symptom determined from a self-completed head injury symptom checklist survey. The subset of postconcussive symptoms in the head injury symptom checklist included headaches, fatigue, dizziness, irritability (lack of patience), anxiety or depression, difficulty sleeping, personality changes, or apathy.^{34,35} Exclusion criteria included any prior history of TBI and any history of neurologic or psychiatric illness including drug or alcohol abuse. The average age was 37.4 years (range, 16–61 years). Control subjects included 26 healthy volunteers (19 male, 7 female) with an average age of 28.3 (range, 17–58 years). Written informed consent was obtained from all subjects in accordance with NIH guidelines and as approved by protocols reviewed by the research ethics committees of each participating institution.

MR Imaging and DTI Acquisition and Analysis

MR imaging was performed in accordance with protocols approved by the Internal Review Board of Weill Cornell Medical College or the Committee on Human Research at University of California, San Francisco before testing. MR imaging was acquired on a 3T Excite scanner (GE Healthcare, Milwaukee, Wis) equipped with an 8-channel phased-array head coil. DTI was performed with a multisection single-shot spin-echo echo-planar pulse sequence (TE = 63 ms, TR = 14 seconds, NEX = 1) by using 55 diffusion-encoding directions isotropically distributed over the surface of a sphere with electrostatic repulsion, acquired at $b = 1000 \text{ s/mm}^2$, 1 acquisition with $b = 0 \text{ s/mm}^2$, 72 interleaved sections of 1.8-mm thickness, each with no gap between sections, with a 128×128 matrix that was zero-filled during reconstruction to 256×256 , and an FOV of 230 mm. The total acquisition time was 13.07 minutes. Images were postprocessed offline by using DTIstudio software (Johns Hopkins University, Baltimore, Md)³⁶ to obtain FA maps, ADC maps, and directionally encoded color FA maps. We acquired the following conventional 3T MR

imaging sequences: 1) axial 3D inversion recovery fast-spoiled gradient T1-weighted images (TE = 1.5 ms, TR = 6.3 ms, TI = 400 ms, flip angle = 15°) with a 230-mm FOV, one hundred fifty-six 1.0-mm contiguous partitions at a 256×256 matrix; 2) axial T2-weighted fluid-attenuated inversion recovery (FLAIR) images (TE = 126 ms, TR = 10 seconds, TI = 2200 ms) with a 220-mm FOV, forty-seven to forty-eight 3.0-mm contiguous sections at a 256×256 matrix; and 3) axial magnetization-prepared gradient echo (MPGR) T2*-weighted images (TE = 15 ms, TR = 500 ms, flip angle = 20°) with a 220 \times 170 mm FOV, and forty-seven to forty-eight 3.0-mm contiguous sections at a 256×192 matrix. Conventional MR images were interpreted by attending neuroradiologists certified by the American Board of Radiology.

To avoid several confounds associated with spatial normalization of white matter tracts, we adopted a region-of-interest approach to test specific structures throughout the brain selected in an *a priori* fashion. Each region of interest was placed in an anatomically identifiable white matter tract on the directionally encoded color FA images (Fig 1). The region-of-interest procedure consisted of using standard ellipse-shaped regions of interest. Selection and analysis were implemented with software written in Interactive Data Language, Version 6.0 (ITT Visual Information Solutions, Boulder, Colo). Ellipses were prescribed on axial directionally encoded anisotropy maps at the center and within the boundaries of each structure in normal-appearing white matter, as assessed from the conventional MR imaging sequences. The sizes and dimensions of ellipses were kept constant for each tract across subjects. Subsequently, the anatomic accuracy of the region-of-interest placement was validated by a board-certified neuroradiologist. Intrarater reliability was assessed from the coefficient of variation of FA from repeat region-of-interest measurements in 5 healthy subjects. The selected structures, following the nomenclature of Mori et al,³⁷ are displayed and listed in Fig 1.

Mean and SD of FA values for each region of interest were recorded. In patients with TBI, a white matter structure with an FA value reduced by more than 2.5 SDs below the mean for that region of interest in the control subjects was considered damaged. The posterior and anterior centrum semiovale were combined into 1 measure such that the centrum semiovale was defined as damaged if the FA was below the threshold in either region of interest. Similarly, the posterior and anterior inferior longitudinal fasciculi were combined into 1 measure. For paired structures, an FA value below the 2.5-SD threshold in either hemisphere designated the tract as damaged, regardless of whether the FA fell below the threshold in 1 or both hemispheres. The number of damaged white matter structures measured on the DTI scan and the number of traumatic microhemorrhages detected on the T2*-weighted MPGR scan by a board-certified neuroradiologist were tallied and correlated with the global measure of cognitive performance described below.

Cognitive Assessment

The Attention Network Task³⁸ provided quantitative assessment of cognitive performance. The test consists of 3 cue conditions with 2 target conditions. The 3 cue conditions were no-cue (baseline), center-cue (temporally informative), and spatial-cue (temporally and spatially informative). Stimuli consisted of a row of 5 visually presented arrows pointing either left or right, against a gray background. The subjects identified the direction of the central arrow by pressing a button with the index finger of the left hand for the left direction or the right hand for the right direction. Reaction times were recorded,

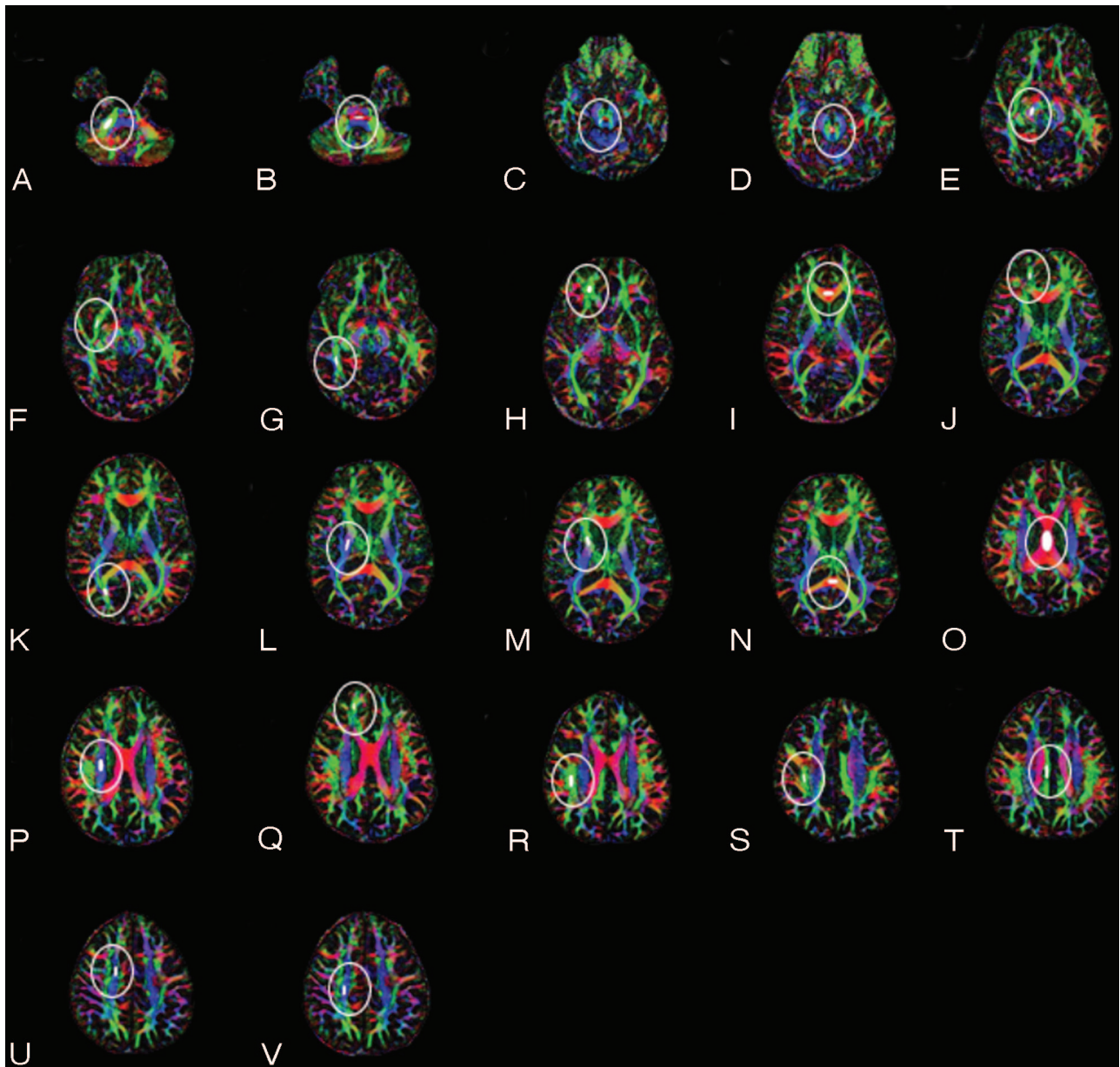


Fig 1. Region-of-interest placement for DTI analysis. Shown are corresponding regions of interest for the right hemisphere. The solid ellipse within the white outline indicates the location and size of the region of interest. *A*, Middle cerebral peduncle. *B*, Pontine crossing tract. *C*, Superior cerebellar peduncle. *D*, Decussation of the superior cerebellar peduncle. *E*, Cerebral peduncle. *F*, Anterior inferior longitudinal fasciculi. *G*, Posterior inferior longitudinal fasciculi. *H*, Uncinate fasciculus. *I*, Genu of the corpus callosum. *J*, Forceps minor. *K*, Forceps major. *L*, Posterior limb of the internal capsule. *M*, Anterior limb of internal capsule. *N*, Splenium of the corpus callosum. *O*, Body of the corpus callosum. *P*, Superior corona radiata. *Q*, Anterior corona radiata. *R*, Superior longitudinal fasciculus at level of the body of the corpus callosum. *S*, Superior longitudinal fasciculus at level of cingulum bundle. *T*, Cingulum bundle. *U*, Anterior centrum semiovale. *V*, Posterior centrum semiovale. Regions of interest were placed on both cerebral hemispheres when applicable, resulting in a total of 39 regions of interest per subject.

and a general measure of cognitive reaction time was evaluated by calculating the mean reaction time across the various conditions.

Statistics

Significance was demonstrated by nonparametric statistical tests. The Spearman ρ statistic was used to test for significance of correlations between FA and mean reaction time as well as between the number of self-reported symptoms and MR imaging findings. The Spearman ρ statistic was also used to test for any correlations between age and FA in the regions of interest measured in the control and patient groups. In this, a Bonferroni correction was used to correct for multiple comparisons. Mann-Whitney U tests were used to test statistical significance when comparing the mild TBI cohort and the healthy control group.

Results

Conventional MR imaging findings were normal in all 26 control subjects. Demographic data of the patients, including age, sex, Glasgow Coma Scale score, head injury symptom checklist, time since injury, and conventional MR imaging findings are displayed in On-line Table 1. The coefficient of variation for intraoperator reliability was $<3\%$ for all regions of interest measured. Although a significant difference of age was present between the TBI and control groups (Mann Whitney U test = 248.0, $P = .004$), no significant correlations were found between FA and age in any of the regions of interest in either the control or patient groups. On the basis of the MR imaging examination excluding DTI, 11 patients with TBI had normal

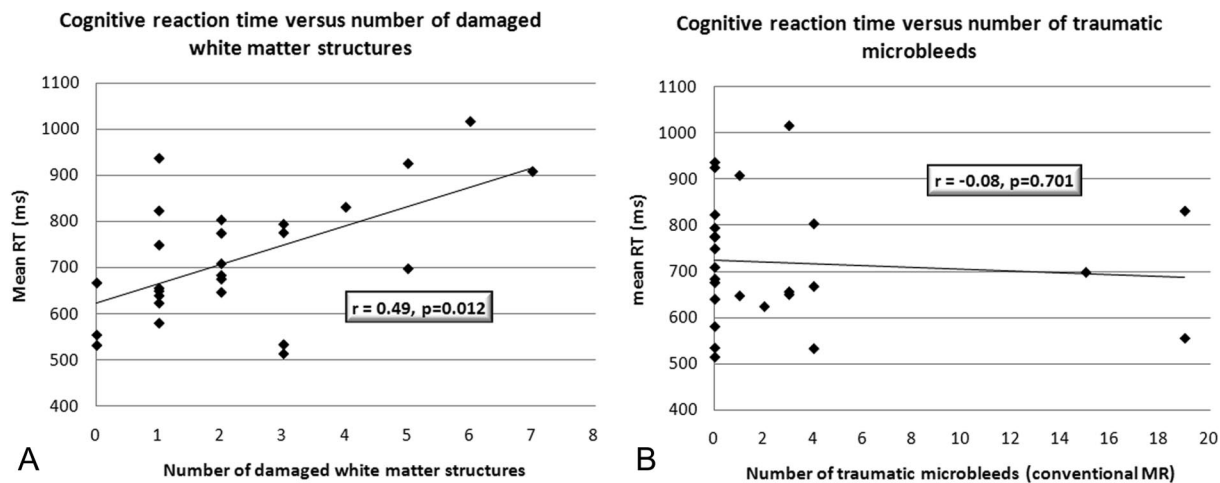


Fig 2. A, Correlation of the number of damaged white matter tracts and speed of processing. The correlation is statistically significant ($P = .012$) with $r = 0.49$. B, In contradistinction, the corresponding analysis, by using conventional MR imaging of the number of traumatic microhemorrhages correlated with speed of processing, is not statistically significant ($r = -0.08$, $P = .70$).

findings and 11 patients with TBI had traumatic microhemorrhages on 3T MPGR T2*-weighted imaging. The remaining 12 patients with TBI had either nonspecific white matter hyperintensities evident on T2-weighted FLAIR images or evidence of chronic hemorrhagic contusions. There was no correlation between the number of self-reported symptoms (head injury symptom checklist) and MR imaging findings ($r = 0.14$, $P = .46$).

For the DTI analysis, a white matter tract was considered to show microstructural injury in a patient with TBI if the FA was reduced by more than 2.5 SDs below the control mean. Following this definition, On-line Table 2 summarizes the structures damaged in the patients with mild TBI on the basis of DTI. The most frequently damaged tracts were the anterior corona radiata in 14 of 34 patients and the uncinate fasciculus in 10 of 34 patients. The genu of the corpus callosum was frequently damaged (7/34), as well as the cingulum bundle (7/34) and the inferior longitudinal fasciculi (6/34). The 5 most frequently injured white matter tracts were all located in frontal and temporal lobes, corresponding to the rostral portions of the anterior and middle fossae.

Almost one third of the patients with mild TBI had normal findings on conventional 3T MR images of the brain (subjects 4, 8, 13, 18, 19, 21–24, 27, and 32 in On-line Table 1), yet 10 of these 11 patients had at least 1 structure with FA values in the range defined as having microstructural injury.

DTI results were significantly correlated with cognitive reaction time, as measured by the mean reaction time score in the Attention Network Task. Figure 2A shows the correlation between mean reaction time and the number of white matter structures with microstructural injury detected by DTI ($r = 0.49$, $P = .012$). In contradistinction, Fig 2B shows that the number of traumatic microhemorrhages detected by T2* MPGR did not correlate with mean reaction time ($r = -0.08$, $P = .70$).

Discussion

Conventional MR imaging and CT often underestimate the extent of axonal injury following a TBI. Patient reports of postconcussion syndrome may be dismissed in the context of

normal findings on CT or conventional MR imaging. Even when focal structural lesions such as traumatic microhemorrhages are identified by routine clinical neuroimaging, their prognostic value for patient outcome is uncertain.^{6,7,39} In this 3T DTI study, we showed variable extent of microstructural injury in normal-appearing white matter in a cohort of 34 patients with isolated mild TBI. This study also demonstrated that 10 of 11 patients with mild TBI with no abnormalities on conventional 3T MR imaging had evidence of microstructural white matter injury on DTI. Most important, the extent of microstructural white matter injury on DTI correlated with impaired cognitive reaction time, unlike the number of traumatic microhemorrhages detected on conventional MR imaging.

Evidence of DAI in Mild TBI

Despite the high incidence of TBI in the population, there are relatively few studies of subjects with TBI with postconcussive symptoms.⁹ There are rare cases in which neuropathologic information can be acquired from human postmortem studies typically involving patients who die from other causes soon after their injury. For example, Blumberg et al⁴⁰ reported 5 patients with mild TBI who died of other causes, with DAI based on postmortem histopathology. Bigler⁹ reported that a patient with mild TBI had working memory deficits and, at autopsy, was noted to have hemosiderin-laden macrophages in the perivascular space and macrophages in the white matter particularly in the frontal lobe. A gross macroscopic inspection of the brain at autopsy was unrevealing, indicating the need for techniques that can probe microscopic structural changes.⁹

These studies and others indicate axonal shear injury to be the primary mechanism of damage in mild TBI.^{17,19} Most interesting, in a mouse model of TBI, reduced anisotropy on DTI correlated with the attenuation of axons stained with amyloid precursor protein, suggesting that DTI is indeed sensitive to the microstructural effects of traumatic axonal injury.³³ This mouse study showed that conventional MR imaging was not as sensitive as DTI to axonal injury, consistent with the results of our study in human patients with TBIs. This pattern

of conventional MR imaging underdiagnosing the extent of damage has been documented in previous studies of patients with TBI with mild-to-severe head injury.^{41,42} Although the exact mechanisms that cause changes in DTI measures such as FA are not fully understood, it is generally accepted that loss of the microstructural integrity of white matter reduces FA values.³⁰ Disruption of the parallel organization of fiber tracts, loss of myelination, and increased permeability between internal and external axonal environments are plausible consequences of DAI.^{17,43,44}

DAI and Pattern of DTI Lesions

To study the pattern of microstructural axonal injury, we defined a white matter pathway to be damaged if the FA value was reduced to values <2.5 SDs below the mean FA of the corresponding structure in the control group. Although DTI can change significantly when broad age ranges are considered,²⁸ we did not match the age of the control group (used to derive an objective criterion indicating damage in FA within each region of interest) to the age of the patient group overall, or to each patient specifically. Thus, this criterion might change with age in a systematic fashion, which could, in turn, impact the data reported. The highest rate of FA changes, however, is in the early years of life. A recent study shows that, when using a region-of-interest analysis, only FA of the centrum semiovale shows a correlation with age in a young adult group.⁴⁵ Furthermore, no significant correlations existed in any of our regions of interest measured between age and FA in either the healthy group or the control group, suggesting that criterion estimates may be fairly stable over the age range in this study. Given the relative stability of FA in adults and the conservative threshold chosen to define a lesion, it is unlikely that age had a significant impact on the categorization of patient results.

With the 2.5-SD threshold, in a healthy population, an FA measure under this threshold would occur <0.62% of the time. That means that only approximately 4 false-positives would be expected in the multiple comparisons of On-line Table 2 if the patients with TBI did not differ from the control sample. However, as seen in On-line Table 2, there are many more locations throughout the brain where reduced FA, falling beyond this criterion for damage, occurs after a mild TBI. Given the conservative nature of this threshold, it is likely that smaller or minor white matter lesions would not be detected by this statistical test. Nevertheless, the data clearly show that frontal and temporal lobe fibers, especially the anterior corona radiata and uncinate fasciculus, tend to be selectively damaged. This pattern of damage is consistent with a rotational shearing mechanism that would cause the greatest damage to tracts that are the farthest from the axis of rotation at the neck. Other common areas of damage include the genu of the corpus callosum, cingulum bundle, and inferior longitudinal fasciculi, which are also rostrally located.

Methodology of DTI Measurements

The DTI sequence used in this study contained 55 diffusion-encoding directions. There has been debate in the literature about the optimal number and orientational distribution of diffusion-encoding directions; however, the emerging consensus is that diffusion tensor estimation is more robust with

data acquired from many diffusion-encoding directions rather than repeated scans of the minimal (ie, 6) number of directions.^{46,47} The rationale for sampling more directions is that this reduces the orientational dependence and increases the accuracy and precision of diffusion tensor parameters such as FA, mean diffusivity, and eigenvalues and eigenvectors. In other words, measurement errors will not be as dependent on relative orientation of the measured diffusion tensor compared with the set of diffusion gradient directions. According to 1 Monte Carlo computer simulation study,⁴⁶ at least 20 unique directions are necessary for a robust estimation of anisotropy, whereas at least 30 directions are required for a robust estimation of tensor orientation (ie, the primary eigenvector) and mean diffusivity. This has been validated in real data from the human brain, which show that there is less bias and greater precision in FA measurements made with greater numbers of diffusion-encoding directions.⁴⁷

Although region-of-interest analysis is the most commonly used method for DTI research and has many merits, there are limitations to its use in the study of TBI. Region-of-interest analysis only lends itself to sample a finite number of regions, despite the fact that axonal injury is often diffuse. The rater for this study placed regions of interest only on normal-appearing white matter, avoiding areas that appeared damaged on conventional MR imaging. Hence, it is likely that the extent of damage determined from this region-of-interest analysis of FA maps is underestimated.

Another method for analyzing DTI is a voxel-based approach. Salmond et al²⁵ used this technique in a study of 16 chronic TBI survivors, reporting FA changes in a number of white matter tracts that revealed a heterogeneous distribution of damage among the cohort. Although voxel-based analysis is operator-independent, fast, and suited for group analyses, there are concerns as to the accuracy of the final measurement due to errors that may arise from the required spatial normalization and coregistration processes. The accuracy of the normalization may be compromised by the presence of focal lesions and atrophy in some patients, abnormalities that are heterogeneous in their spatial extent and distribution across subjects. In our study, we chose to use a region-of-interest technique to avoid confounds from such normalization and coregistration errors. An added advantage of the region-of-interest approach is that it is appropriate for individual analysis, unlike voxel-based techniques that have yet to establish their validity in single-subject analysis.

Correlation of DTI with Cognitive Deficits

Our finding of a lack of correlation between conventional MR imaging results and patient outcome in TBI is consistent with recent studies. Scheid et al⁷ defined DAI in 66 patients with chronic TBI of all severities on the basis of T2*-weighted gradient-echo hypointensities at 3T, which correspond to traumatic microhemorrhages. Although the number of microhemorrhages correlated with injury severity on the basis of the Glasgow Coma Scale at presentation, there was no correlation with functional outcome scored with the Glasgow Outcome Scale. A follow-up 3T MR imaging study included 18 patients with “pure DAI,” defined as traumatic microhemorrhages in the absence of other posttraumatic abnormalities on conventional MR imaging. These patients had evidence of cognitive

impairments, especially memory and executive function. However, there was no correlation between the number of microhemorrhages and global cognitive performance. A 1T MR imaging study of 80 patients with acute mild TBI demonstrated no correlation of conventional MR imaging lesions with neurocognitive tests of memory, learning, attention, and executive function at long-term follow-up.³⁹

There is mounting evidence that individual differences in microstructural white matter integrity account for variation in a wide range of cognitive skills. For example, groups have shown significant correlations of frontoparietal white matter FA values to memory performance and of frontostriatal FA measurements to cognitive control.⁴⁸⁻⁵² However, there is a dearth of prior work relating DTI to neurocognitive function in TBI. Two prior DTI studies of TBI showed that reduced white matter FA values are correlated with the Glasgow Coma Score at presentation^{24,53} and with the modified Rankin Scale score at hospital discharge.²⁴ A prior DTI investigation has evaluated neurocognitive status, finding that ADC is associated with impaired learning and working memory in patients with chronic TBI and that there are significant bilateral decreases in anisotropy in major white matter tracts in the temporal, frontal, parietal, and occipital lobes.²⁵

In a more recent DTI study of TBI, Kraus et al⁵⁴ examined a group of 20 patients with mild TBI and demonstrated that these subjects had reduced FA in the corticospinal tract (which corresponds to our superior corona radiata, posterior limb of the internal capsule, and cerebral peduncle), sagittal stratum (which corresponds to our forceps major), and superior longitudinal fasciculus. In their study, a 1-SD threshold (in contrast to the 2.5-SD threshold used in our study) below the control mean FA was used to indicate reduced anisotropy. Using this criterion, Kraus et al found an average of 5.9 regions of interest with reduced FA in their subjects with mild TBI, but, most important, also reported that control subjects had, on average, 3.6 regions of interest with reduced FA. Thus, with such a criterion, it is difficult to assess whether FA reduced by 1 SD is due to normal interindividual variability in white matter integrity or is truly a result of DAI. In contradistinction, with a 2.5-SD threshold, none of our control subjects had reduced FA, suggesting that FA values below this are likely pathologic in nature. Kraus et al also found that the number of structures with reduced FA correlated with executive, attentional, and memory measures. This is consistent with our finding that the extent of posttraumatic microstructural axonal injury on DTI correlates with reduced cognitive reaction time, suggesting that DTI can reveal a biologic substrate for cognitive impairments in TBI.

Anterior corona radiata fibers pass through the Brodmann area 32, which consists of the dorsal anterior cingulate. Additionally, uncinate fasciculus fibers pass through the Brodmann area 11, which is part of the frontal cortex, covering the medial portion of the frontal lobe and connecting to the temporal lobe at Brodmann areas 20, 28, 34, and 36. DTI research in schizophrenia indicates that FA reduction in this pathway corresponds to poor verbal and visual memory performance.^{55,56} The relative frequency of injury to the anterior corona radiata and the uncinate fasciculus, as well as to the cingulum and the genu of the corpus callosum, may explain the impairment of cognitive reaction time found in this study

of mild TBI. Future studies will more closely examine the neuronal circuitry involved in cognitive domains commonly impaired following TBI to predict cognitive deficits on the basis of physical injury. This research will also investigate whether relationships of normal interindividual variation of cognitive function and white matter integrity are also evident in the extended range of function and integrity that exist in patients with TBI. Prospective longitudinal assessment of patients with TBI from the acute phase through the chronic phase is needed to understand the relationship between the evolution of microstructural white matter injury and the recovery of function after TBI, which is underway at the Cognitive Neurobiological Research Consortium in Traumatic Brain Injury.

Conclusion

We find that the extent of microstructural white matter injury on DTI in patients with mild TBI with postconcussive syndrome is associated with poorer reaction time in a simple cognitive task, whereas the number of traumatic microhemorrhages on conventional 3T MR imaging is not. This study provides preliminary evidence that DTI may serve as a microstructural imaging biomarker for long-term neurocognitive impairments in TBI.

References

1. Langlois JA, Rutland-Brown W, Wald MM. **The epidemiology and impact of traumatic brain injury: a brief overview.** *J Head Trauma Rehabil* 2006;21:375-78
2. Dikmen S, McLean A Jr, Temkin NR, et al. **Neuropsychologic outcome at one-month postinjury.** *Arch Phys Med Rehabil* 1986;67:507-13
3. van der Naalt J, Hew JM, van Zomeren AH, et al. **Computed tomography and magnetic resonance imaging in mild to moderate head injury: early and late imaging related to outcome.** *Ann Neurol* 1999;46:70-78
4. Mittl RL, Grossman RI, Hiehle JF, et al. **Prevalence of MR evidence of diffuse axonal injury in patients with mild head injury and normal head CT findings.** *AJNR Am J Neuroradiol* 1994;15:1583-89
5. Hammoud DA, Wasserman BA. **Diffuse axonal injuries: pathophysiology and imaging.** *Neuroimaging Clin N Am* 2002;12:205-16
6. Scheid R, Preul C, Gruber O, et al. **Diffuse axonal injury associated with chronic traumatic brain injury: evidence from T2*-weighted gradient-echo imaging at 3T.** *AJNR Am J Neuroradiol* 2003;24:1049-56
7. Scheid R, Walther K, Guthke T, et al. **Cognitive sequelae of diffuse axonal injury.** *Arch Neurol* 2006;63:418-24
8. Himanen L, Portin R, Isoniemi H, et al. **Cognitive functions in relation to MRI findings 30 years after traumatic brain injury.** *Brain Inj* 2005;19:93-100
9. Bigler ED. **Neuropsychological results and neuropathological findings at autopsy in a case of mild traumatic brain injury.** *J Int Neuropsychol Soc* 2004;10:794-806
10. Arcia E, Gualtieri CT. **Neurobehavioural performance of adults with closed-head injury, adults with attention deficit, and controls.** *Brain Inj* 1994;8:395-404
11. Hellawell DJ, Taylor RT, Pentland B. **Cognitive and psychosocial outcome following moderate or severe traumatic brain injury.** *Brain Inj* 1999;13:489-504
12. Kaplan CP, Corrigan JD. **The relationship between cognition and functional independence in adults with traumatic brain injury.** *Arch Phys Med Rehabil* 1994;75:643-47
13. Levin HS. **Memory deficit after closed head injury.** *J Clin Exp Neuropsychol* 1990;12:129-53
14. Stuss DT, Ely P, Hugenholtz H, et al. **Subtle neuropsychological deficits in patients with good recovery after closed head injury.** *Neurosurgery* 1985;17:41-47
15. Ragnarsson KT. **Results of the NIH consensus conference on "rehabilitation of persons with traumatic brain injury."** *Restor Neurol Neurosci* 2002;20:103-08
16. Medana IM, Esiri MM. **Axonal damage: a key predictor of outcome in human CNS diseases.** *Brain* 2003;126:515-30
17. Povlishock JT, Katz DI. **Update of neuropathology and neurological recovery after traumatic brain injury.** *J Head Trauma Rehabil* 2005;20:76-94
18. Smith DH, Meaney DF, Shull WH. **Diffuse axonal injury in head trauma.** *J Head Trauma Rehabil* 2003;18:307-16
19. Gennarelli TA, Graham DI. **Neuropathology of the head injuries.** *Semin Clin Neuropsychiatry* 1998;3:160-75

20. Wallesch CW, Curio N, Galazky I, et al. **The neuropsychology of blunt head injury in the early postacute stage: effects of focal lesions and diffuse axonal injury.** *J Neurotrauma* 2001;18:11–20
21. Wallesch CW, Curio N, Kutz S, et al. **Outcome after mild-to-moderate blunt head injury: effects of focal lesions and diffuse axonal injury.** *Brain Inj* 2001;15:401–12
22. Fork M, Bartels C, Ebert AD, et al. **Neuropsychological sequelae of diffuse traumatic brain injury.** *Brain Inj* 2005;19:101–08
23. Himanen L, Portin R, Isoniemi H, et al. **Longitudinal cognitive changes in traumatic brain injury: a 30-year follow-up study.** *Neurology* 2006;66:187–92
24. Huisman TA, Schwamm LH, Schaefer PW, et al. **Diffusion tensor imaging as potential biomarker of white matter injury in diffuse axonal injury.** *AJNR Am J Neuroradiol* 2004;25:370–76
25. Salmond CH, Menon DK, Chatfield DA, et al. **Diffusion tensor imaging in chronic head injury survivors: correlations with learning and memory indices.** *Neuroimage* 2006;29:117–24
26. Basser PJ, Pierpaoli C. **Microstructural and physiological features of tissues elucidated by quantitative-diffusion-tensor MRI.** *J Magn Reson B* 1996;111:209–19
27. Ulug AM, van Zijl PC. **Orientation-independent diffusion imaging without tensor diagonalization: anisotropy definitions based on physical attributes of the diffusion ellipsoid.** *J Magn Reson Imaging* 1999;9:804–13
28. Mukherjee P, McKinsty RC. **Diffusion tensor imaging and tractography of human brain development.** *Neuroimaging Clin N Am* 2006;16:19–43, vii
29. Watts R, Liston C, Niogi S, et al. **Fiber tracking using magnetic resonance diffusion tensor imaging and its applications to human brain development.** *Ment Retard Dev Disabil Res Rev* 2003;9:168–77
30. Arfanakis K, Houghton VM, Carew JD, et al. **Diffusion tensor MR imaging in diffuse axonal injury.** *AJNR Am J Neuroradiol* 2002;23:794–802
31. Huisman TA. **Diffusion-weighted imaging: basic concepts and application in cerebral stroke and head trauma.** *Eur Radiol* 2003;13:2283–97
32. Lee ZI, Byun WM, Jang SH, et al. **Diffusion tensor magnetic resonance imaging of microstructural abnormalities in children with brain injury.** *Am J Phys Med Rehabil* 2003;82:556–59
33. Mac Donald CL, Dikranian K, Song SK, et al. **Detection of traumatic axonal injury with diffusion tensor imaging in a mouse model of traumatic brain injury.** *Exp Neurol* 2007;205:116–31. Epub 2007 Feb 12
34. Kay T, Harrington DE, Adams R, et al. **Definition of mild traumatic brain injury.** *J Head Trauma Rehabil* 1993;8:86–87
35. McLean A Jr, Dikmen S, Temkin N, et al. **Psychosocial functioning at 1 month after head injury.** *Neurosurgery* 1984;14:393–99
36. Jiang H, van Zijl PC, Kim J, et al. **DTIStudio: resource program for diffusion tensor computation and fiber bundle tracking.** *Comput Methods Programs Biomed* 2006;81:106–16. Epub 2006 Jan 18
37. Mori S, Wakana S, Van Zijl PC. *MRI Atlas of Human White Matter.* Amsterdam: Elsevier; 2005
38. Fan J, McCandliss BD, Fossella J, et al. **The activation of attentional networks.** *Neuroimage* 2005;26:471–79
39. Hughes DG, Jackson A, Mason DL, et al. **Abnormalities on magnetic resonance imaging seen acutely following mild traumatic brain injury: correlation with neuropsychological tests and delayed recovery.** *Neuroradiology* 2004;46:550–58
40. Blumbergs PC, Scott G, Manavis J, et al. **Staining of amyloid precursor protein to study axonal damage in mild head injury.** *Lancet* 1994;344:1055–56
41. Anderson CV, Wood DM, Bigler ED, et al. **Lesion volume, injury severity, and thalamic integrity following head injury.** *J Neurotrauma* 1996;13:59–65
42. Gale SD, Johnson SC, Bigler ED, et al. **Trauma-induced degenerative changes in brain injury: a morphometric analysis of three patients with preinjury and postinjury MR scans.** *J Neurotrauma* 1995;12:151–58
43. Inglese M, Makani S, Johnson G, et al. **Diffuse axonal injury in mild traumatic brain injury: a diffusion tensor imaging study.** *J Neurosurg* 2005;103:298–303
44. Povlishock JT, Erb DE, Astruc J. **Axonal response to traumatic brain injury: reactive axonal change, deafferentation, and neuroplasticity.** *J Neurotrauma* 1992;9(suppl 1):S189–200
45. Snook L, Plewes C, Beaulieu C. **Voxel based versus region of interest analysis in diffusion tensor imaging of neurodevelopment.** *Neuroimage* 2007;34:243–52. Epub 2006 Oct 27
46. Jones DK. **The effect of gradient sampling schemes on measures derived from diffusion tensor MRI: a Monte Carlo study.** *Magn Reson Med* 2004;51:807–15
47. Landman BA, Farrell JA, Jones CK, et al. **Effects of diffusion weighting schemes on the reproducibility of DTI-derived fractional anisotropy, mean diffusivity, and principal eigenvector measurements at 1.5T.** *Neuroimage* 2007;36:1123–38
48. Liston C, Watts R, Tottenham N, et al. **Frontostriatal microstructure modulates efficient recruitment of cognitive control.** *Cereb Cortex* 2006;16:553–60
49. Nagy Z, Westerberg H, Klingberg T. **Maturation of white matter is associated with the development of cognitive functions during childhood.** *J Cogn Neurosci* 2004;16:1227–33
50. Niogi SN, McCandliss BD. **Left lateralized white matter microstructure accounts for individual differences in reading ability and disability.** *Neuropsychologia* 2006;44:2178–88. Epub 2006 Mar 9
51. Olesen PJ, Nagy Z, Westerberg H, et al. **Combined analysis of DTI and fMRI data reveals a joint maturation of white and grey matter in a fronto-parietal network.** *Brain Res Cogn Brain Res* 2003;18:48–57
52. Tuch DS, Salat DH, Wisco JJ, et al. **Choice reaction time performance correlates with diffusion anisotropy in white matter pathways supporting visuo-spatial attention.** *Proc Natl Acad Sci U S A* 2005;102:12212–17. Epub 2005 Aug 15
53. Benson RR, Meda SA, Vasudevan S, et al. **Global white matter analysis of diffusion tensor images is predictive of injury severity in traumatic brain injury.** *J Neurotrauma* 2007;24:446–59
54. Kraus MF, Susmaras T, Caughlin BP, et al. **White matter integrity and cognition in chronic traumatic brain injury: a diffusion tensor imaging study.** *Brain* 2007;130:2508–19
55. Nakamura M, McCarley RW, Kubicki M, et al. **Fronto-temporal disconnectivity in schizotypal personality disorder: a diffusion tensor imaging study.** *Biol Psychiatry* 2005;58:468–78. Epub 2005 Jun 22
56. Nestor PG, Kubicki M, Gurrera RJ, et al. **Neuropsychological correlates of diffusion tensor imaging in schizophrenia.** *Neuropsychology* 2004;18:629–37