

Are your **MRI contrast agents** cost-effective?

Learn more about generic **Gadolinium-Based Contrast Agents**.



**FRESENIUS  
KABI**

caring for life

**AJNR**

## **Onyx Embolization of Distal Aneurysms of the Posterior Circulation**

M. Saravanan, A. Clifton and D. Johnson

*AJNR Am J Neuroradiol* published online 12 February 2009  
<http://www.ajnr.org/content/early/2009/02/12/ajnr.A1466.citation>

This information is current as of April 23, 2024.

### Onyx Embolization of Distal Aneurysms of the Posterior Circulation

We read with interest the article by Isokangas et al<sup>1</sup> about endovascular treatment of peripheral aneurysms of the posterior inferior cerebellar artery (PICA). We agree with the authors that most peripheral aneurysms seem secondary to arterial dissection and can be treated by endovascular techniques.<sup>1</sup> We have recent experience in treating 2 consecutive cases of patients with peripheral aneurysms of the posterior circulation with Onyx (Onyx 18 liquid embolic system; ev3, Irvine, Calif) embolization. We illustrate a case of a distal PICA aneurysm and a case of a distal aneurysm of the left superior cerebellar artery (SCA) treated by Onyx embolization with aneurysmal occlusion and no significant morbidity.<sup>2</sup> Small areas of cerebellar infarction after embolization developed in both patients, without any significant clinical sequelae.

The article by Isokangas et al<sup>1</sup> and our cases illustrate that distal aneurysms of the posterior circulation are now being frequently treated by endovascular techniques, including coiling and parent-vessel sacrifice with Onyx. Onyx embolization of distal aneurysms of the posterior circulation is an alternative and, we believe, a safe technique. It may have the advantage of reduced aneurysmal rupture, but

of course, there is always vessel occlusion and resultant infarction, but these infarcts are usually clinically well tolerated if embolization is performed distal to the perforators. It is very important for the interventionalist to understand and recognize the various endovascular treatment options available to treat these unstable lesions, which are associated with a high risk for rebleeding and mortality or morbidity if left untreated.

M. Saravanan

A. Clifton

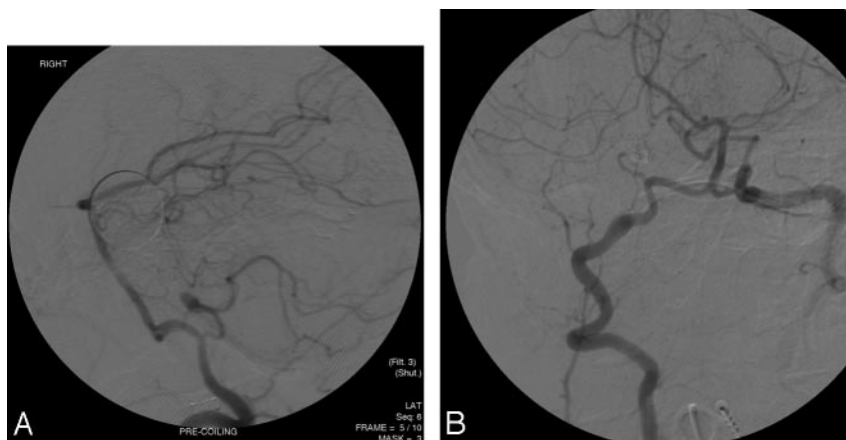
D. Johnson

Department of Neuroradiology  
Atkinson Morley Wing, St George's Hospital  
London, UK

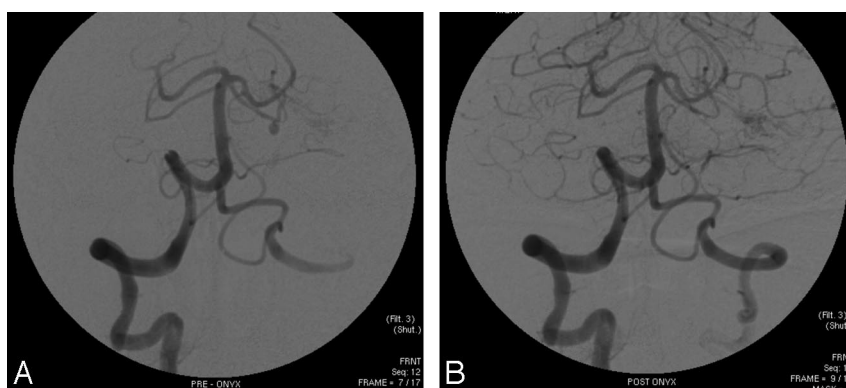
DOI 10.3174/ajnr.A1466

### References

1. Isokangas JM, Siniluoto T, Tikkakoski T, et al. Endovascular treatment of peripheral aneurysms of the posterior inferior cerebellar artery. *AJNR Am J Neuroradiology* 2008;29:1783–88
2. Guan YS, Wang MQ. Endovascular embolisation of intracranial aneurysms. *Angiology* 2008;59:342–51



**Fig 1.** Case 1. A 51-year-old woman presented with sudden-onset headache. CT angiography and CT scans showed a distal aneurysm of the right PICA with evidence of subarachnoid hemorrhage. Initial digital subtraction angiography demonstrated a small aneurysm distal to the tonsillomedullary segment of the right PICA (A). The aneurysm was treated by Onyx embolization with parent artery occlusion, and it remained stable during follow-up (B).



**Fig 2.** Case 2. A 73-year-old woman presented with sudden-onset headache. A CT scan of the brain showed subarachnoid hemorrhage with early hydrocephalus. Digital subtraction angiography demonstrated a small aneurysm of the distal left SCA (A). The aneurysm was treated with Onyx embolization with parent vessel occlusion, and it remained stable during follow-up (B).