

The So-Called Cranial Dural Channels and Their Relationship with the Bridging Veins

With great interest, we read the paper “Dural Venous Channels: Hidden in Plain Sight—Reassessment of an Under-Recognized Entity” by M. Shapiro et al.¹ The authors should be commended for drawing the attention of readers to what is a common experience among neurointerventionalists performing cerebral angiographies on a daily basis: the extreme variation of the cerebral venous—including the dural—system. In the literature and in everyday practice, we used to call these channels “convexial sinuses,” “accessory sinuses,” “tributary sinuses,” or even “no-name sinuses” when located in the convexial dura. Therefore, it is a common finding, but certainly their recognition requires a minimum angiographic experience and attention. We definitely concur that their frequency is at least 26% as the authors found, if not higher. These flattened channels may be very short or very long.² In the latter, the bridging veins emptying into them appear away from the typical sinuses, and this is the reason why a bridging vein fistula³ is sometimes found in a convexial location.

However, we should not forget that we are talking about images and radiologic impressions. Therefore, we have to clarify the following point: do they really represent a part of the dural sinus network, as the name “dural channel” implies, or is it simply the intradural course of the bridging vein, which may be short or longer? In the first case, the channel should be indistinguishable from the rest of the dural venous sinuses and histologically equivalent to a sinus, whereas in the second, we are dealing with a vein covered by or embedded in the dura but still a vein. Although we cannot answer this question in an absolute way for all observed cases, we can certainly state that often we are dealing with the intradural course of the bridging vein and not with a “dural,” properly speaking, channel. In our dural anatomy project, we have seen several bridging veins with such an intradural course (Figure). The same configuration can be seen, though extremely rarely, also in the spinal cord (anecdotal data), where no sinuses exist. In our study, we have not found yet a dural channel as meant by the authors;¹ however, it may well be related to the small number of the cases studied until now. Therefore, we are not sure if the proposed unifying name “dural venous channels” is a good idea.

Regarding the statement “They may play a role in the angioarchitecture of dural arteriovenous fistulas that appear to

drain directly into the cortical vein,” it is unclear if the authors mean that these dural channels may represent the actual location of the shunt. In our experience, the shunt is not located in that channel. Until now, we have not seen a fistula located in such a channel, in a tentorial one (tentorial sinus), or in a falcine or a convexial one, despite years of observation trying to distinguish features implying such a location. On the contrary, detailed analyses of the angiographic images, sometimes also correlated with surgical views, convince us that the exact location of the shunt is the junction of the bridging vein with the dura.³ This is why bridging vein fistulas occur even without such a “dural venous channel.”

Disclosures: Gerasimos Baltasvias—UNRELATED: Employment: International Neuroscience Institute (INI); RELATED: Grant: Gesellschaft für die Förderung der Wissenschaft in der Neurochirurgie e.V, Hannover, Germany.*; RELATED: Employment: Neuroradiology, Hannover Medical School, Germany. Heinrich Lanfermann—UNRELATED: Employment: Director of the Institute of Diagnostic and Interventional Neuroradiology, Hannover Medical School, Germany.

REFERENCES

- Shapiro M, Srivatanakul K, Raz E, et al. **Dural venous channels: hidden in plain sight—reassessment of an under-recognized entity.** *AJNR Am J Neuroradiol* 2020;41:1434–40 [CrossRef Medline](#)
- Baltasvias G, Bhatti A, Valavanis A. **Lateral convexial tributary sinus of superior sagittal sinus. A rare anatomic variation and the importance of its recognition.** *Clin Neurol Neurosurg* 2013;115:2268–69 [CrossRef Medline](#)
- Baltasvias G, Parthasarathi V, Aydin E, et al. **Cranial dural arteriovenous shunts. Part 1. Anatomy and embryology of the bridging and emissary veins.** *Neurosurg Rev* 2015;38:253–63 [CrossRef Medline](#)

Gerasimos Baltasvias
International Neuroscience Institute
Hannover, Germany
Neuroradiology Department
Medical School Hannover
Hannover, Germany

Vincenzo Paterno
International Neuroscience Institute
Hannover, Germany

Heinrich Lanfermann
Neuroradiology Department
Medical School Hannover
Hannover, Germany

<http://dx.doi.org/10.3174/ajnr.A6972>

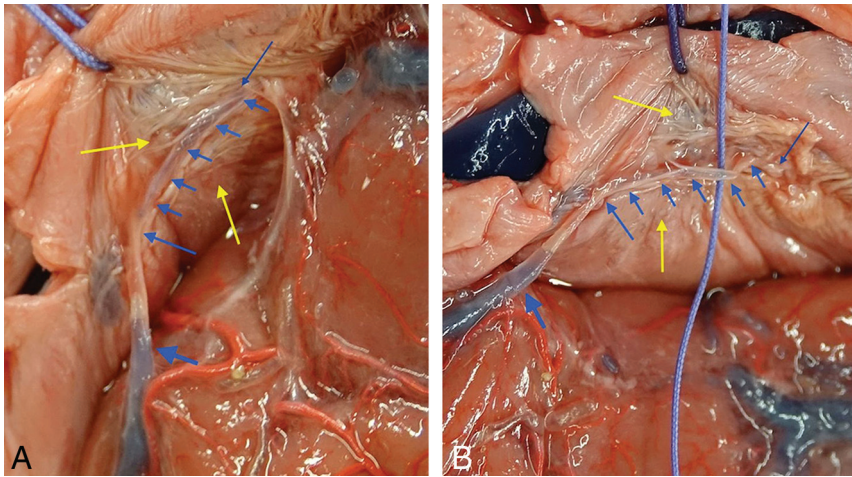


FIGURE. A, Cadaveric preparation showing a bridging vein (*thick blue arrow*) reaching the dura (*blue arrow*) at the lateral wall of the superior sagittal sinus and falx (*yellow arrows*), continuing (incomplete silicon penetration), embedded into the dura (*multiple short blue arrows*) to its piercing point (*thin blue arrow*), where it enters the sinus. Even macroscopically, one may see the bridging vein buried, not just adherent to and still easily distinguishable from the dura. The vein can be microsurgically prepared and separated from the dura, as it is shown in *B* (photo slightly tilted to the right compared with *A*).