

Are your **MRI contrast agents** cost-effective?

Learn more about generic **Gadolinium-Based Contrast Agents**.



**FRESENIUS  
KABI**

caring for life

**AJNR**

**Minimally Invasive Stent Screw–Assisted  
Internal Fixation Technique Corrects  
Kyphosis in Osteoporotic Vertebral Fractures  
with Severe Collapse: A Pilot "Vertebra  
Plana" Series**

This information is current as  
of May 7, 2024.

A. Cianfoni, R.L. Delfanti, M. Isalberti, P. Scarone, E.  
Koetsier, G. Bonaldi, J.A. Hirsch and M. Pileggi

*AJNR Am J Neuroradiol* published online 21 April 2022  
<http://www.ajnr.org/content/early/2022/04/21/ajnr.A7493>

# Minimally Invasive Stent Screw–Assisted Internal Fixation Technique Corrects Kyphosis in Osteoporotic Vertebral Fractures with Severe Collapse: A Pilot “Vertebra Plana” Series

 A. Cianfoni,  R.L. Delfanti,  M. Isalberti,  P. Scarone,  E. Koetsier,  G. Bonaldi,  J.A. Hirsch, and  M. Pileggi



## ABSTRACT

**BACKGROUND AND PURPOSE:** Fractures with “vertebra plana” morphology are characterized by severe vertebral body collapse and segmental kyphosis; there is no established treatment standard for these fractures. Vertebroplasty and balloon kyphoplasty might represent an undertreatment, but surgical stabilization is challenging in an often elderly osteoporotic population. This study assessed the feasibility, clinical outcome, and radiologic outcome of the stent screw–assisted internal fixation technique using a percutaneous implant of vertebral body stents and cement-augmented pedicle screws in patients with non-neoplastic vertebra plana fractures.

**MATERIALS AND METHODS:** Thirty-seven consecutive patients with vertebra plana fractures were treated with the stent screw–assisted internal fixation technique. Vertebral body height, local and vertebral kyphotic angles, outcome scales (numeric rating scale and the Patient’s Global Impression of Change), and complications were assessed. Imaging and clinical follow-up were obtained at 1 and 6 months postprocedure.

**RESULTS:** Median vertebral body height restoration was 7 mm (+74%), 9 mm (+150%), and 3 mm (+17%) at the anterior wall, middle body, and posterior wall, respectively. Median local and vertebral kyphotic angles correction was 8° and 10° and was maintained through the 6-month follow-up. The median numeric rating scale score improved from 8/10 preprocedure to 3/10 at 1 and 6 months ( $P < .001$ ). No procedural complications occurred.

**CONCLUSIONS:** The stent screw–assisted internal fixation technique was effective in obtaining height restoration, kyphosis correction, and pain relief in patients with severe vertebral collapse.

**ABBREVIATIONS:** ant = anterior; BKP = balloon kyphoplasty; IQR = interquartile range; LKA = local kyphotic angle; mid = middle; NRS = numeric rating scale; PGIC = Patient’s Global Impression of Change; post = posterior; SAIF = stent screw–assisted internal fixation; VB = vertebral body; VBH = vertebral body height; VKA = vertebral kyphotic angle; VP = vertebra plana; VBS = Vertebral Body Stenting System; VCF = vertebral compression fracture

**P**ainful osteoporotic vertebral compression fractures (VCFs) are commonly treated with traditional vertebral augmentation techniques, particularly vertebroplasty and balloon kyphoplasty

(BKP), which reinforce the anterior column, arrest wedge deformity, and palliate pain. The VCFs characterized by severe vertebral body (VB) collapse (>70% VB height loss) are generally termed “vertebra plana” (VP)<sup>1</sup> and demonstrate extreme osseous structural loss and resorption with anterior and middle column injury. Furthermore, they may present with intravertebral pseudoarthrosis (also termed cleft or Kümmel disease), posterior wall retropulsion, and pediculo-somatic junction fractures. The accompanying kyphosis can limit breathing<sup>2</sup> and activities of daily living and is likely associated with an increased mortality risk.<sup>3</sup>

Ideally, treatment of these fractures should stabilize, restore height, correct sagittal spinal alignment, correct kyphotic deformity, and achieve pain relief. Although standard augmentation techniques are effective in achieving pain palliation,<sup>1,4–6</sup> they do not address middle column and pediculo-somatic junction fractures.<sup>7</sup> Furthermore, secondary loss of stability has been reported at follow-up in VP cases treated with augmentation.<sup>8,9</sup> At the


Received October 17, 2021; accepted after revision February 9, 2022.

From the Departments of Neuroradiology (A.C., R.L.D., M.I., M.P.), Neurosurgery (P.S.), and Pain Management Center (E.K.), Neurocenter of Southern Switzerland, Lugano, Switzerland; Department of Interventional and Diagnostic Neuroradiology (A.C.), Inselspital University Hospital of Bern, Bern, Switzerland; Faculty of Biomedical Sciences (E.K.), Università della Svizzera Italiana, Lugano, Switzerland; Neurosurgical Department (G.B.), Casa di Cura Igea, Milan, Italy; and Department of Radiology (J.A.H.), Massachusetts General Hospital, Harvard Medical School, Boston, Massachusetts.

A. Cianfoni and R.L. Delfanti share first co-authorship.

M. Pileggi and J.A. Hirsch share last co-authorship.

Please address correspondence to Rachel Delfanti, MD, Rolling Oaks Radiology, 415 Rolling Oaks D, Suite 125, Thousand Oaks, CA 91361; e-mail: Racheldelfanti@gmail.com; @JoshuaAHirsch; @Marco\_Pileggi

 Indicates open access to non-subscribers at [www.ajnr.org](http://www.ajnr.org)

<http://dx.doi.org/10.3174/ajnr.A7493>

same time, these fractures often affect elderly and fragile patients, making surgical stabilization problematic<sup>10,11</sup> because stand-alone posterior fixation techniques carry high risk of failure in conditions of poor bone quality,<sup>12,13</sup> while anterior or circumferential approaches are associated with higher intraoperative blood loss and perioperative complications.<sup>14</sup> Thus, there is no standard treatment for these challenging VCFs.<sup>1,15</sup>

The stent screw–assisted internal fixation (SAIF) technique includes percutaneous insertion and balloon-expansion of 2 vertebral body stents (Vertebral Body Stenting System [VBS]; DePuy Synthes–Johnson & Johnson), followed by placement of cannulated and fenestrated pedicular screws (Injection pin, 2B1, Milan, Italy) in the lumen of the stents and cement augmentation through the screws. SAIF is currently being used for the treatment of severe osteoporotic and neoplastic fractures in 5 international centers.<sup>16–18</sup>

The purpose of this study was to assess the feasibility and safety of performing SAIF in this cohort of patients with non-neoplastic VP. In addition, height restoration and kyphosis correction of the target vertebrae and the clinical outcome in terms of pain relief were studied.

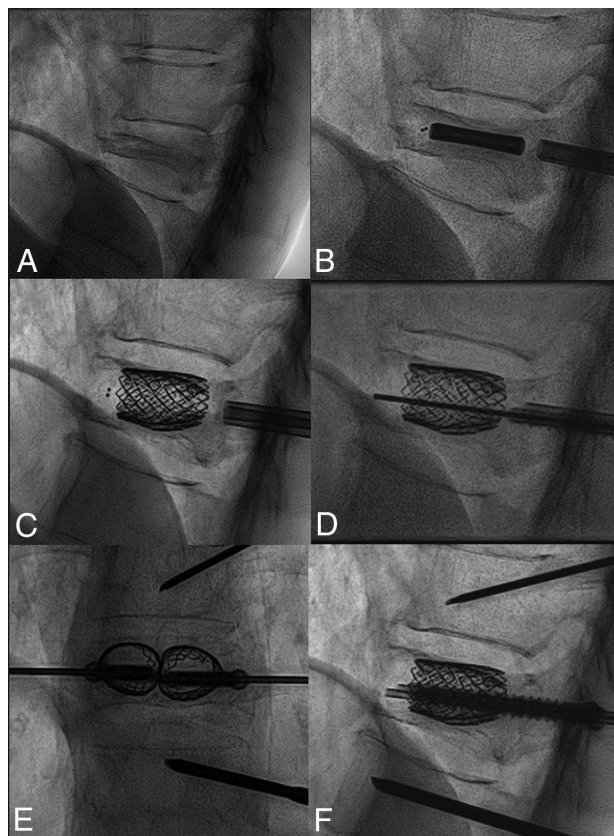
## MATERIALS AND METHODS

### Patient Selection

This retrospective analysis included all thoracic and lumbar non-neoplastic VP treated with the stand-alone SAIF technique at a single institution between August 2017 and June 2020. Cases without comparable pre- and postoperative imaging (pre- and postoperative standing plain films, and/or pre- and postoperative CT/MR imaging) were excluded. The decision to treat with SAIF was made by a multidisciplinary group (composed of interventional neuroradiologists, spine surgeons, and pain specialists) for recent (<1 month) or nonhealed fractures causing persistent pain despite conservative treatment ( $\geq 5$  on the numeric rating scale [NRS]; range, 0–10) or progressive collapse with kyphotic deformity. Nonhealed fractures were defined as osteoporotic fractures occurring >1 month earlier or at an unknown time with persistent pain and evidence of pseudoarthrosis (characterized by an intrasomatic cavity filled with gas or fluid and fracture mobility) and/or bone edema on MR imaging (STIR pulse sequence). Fractures were graded according to the AO Spine Spinal Section of the German Orthopedic and Trauma Society osteoporotic fracture classification system.<sup>19</sup> Patients with neurologic deficits that required decompressive laminectomy and patients treated with SAIF combined with posterior instrumentation were excluded. All patients gave informed consent. The local ethics committee of Canton Ticino and EOC institutional review board approved the study.

### SAIF Procedure

All procedures were performed percutaneously with the patient under general anesthesia, with biplane fluoroscopic guidance using a previously described technique.<sup>16</sup> Two VBSs were balloon-expanded in the VB with the intent to reduce local kyphosis. Transpedicular cannulated-fenestrated screws (Injection Pin 2B1; HealthManagement.org) were inserted over a Kirschner wire inside the VBS lumen and augmented with high-viscosity polymethylmethacrylate (Vertaplex HV; Stryker) under fluoroscopic

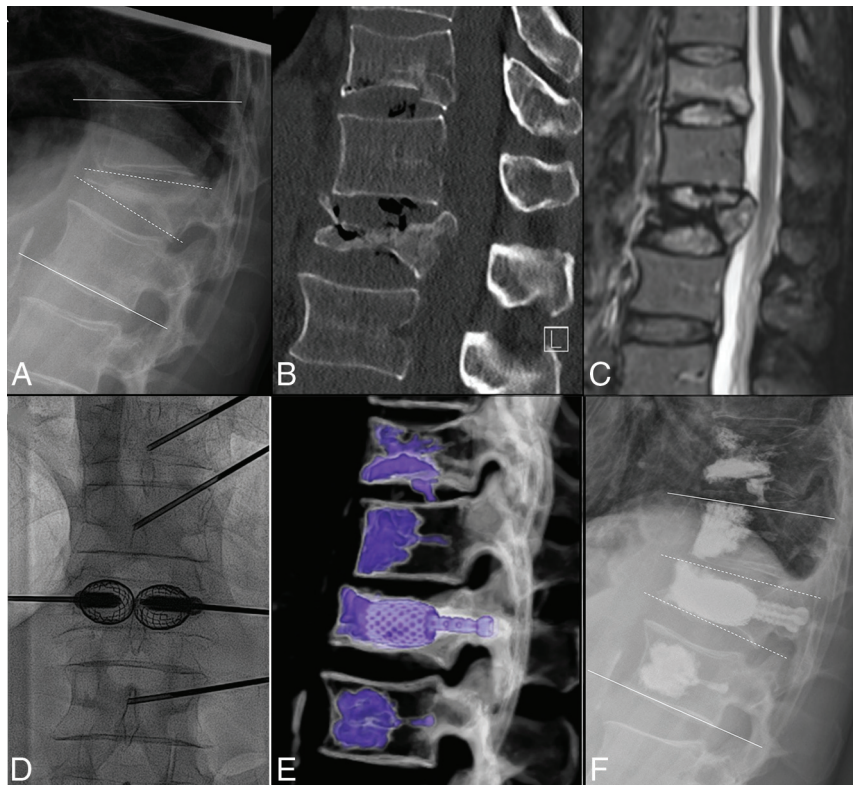


**FIG 1.** A, Procedural steps of the SAIF technique. Preprocedural lateral view of a T11 VP fracture. B, Balloon-mounted vertebral body stent insertion in the vertebral body. C, Balloon expansion of the stents. D, Access trocars are exchanged with transpedicular, cannulated-fenestrated screws over a Kirschner wire. Anterior-posterior and lateral views (E and F) obtained before cement injection through the screws.

control. Concomitant adjacent vertebroplasty was performed to treat milder VCFs (non-VP fracture: ie, with a minor degree of collapse) or with prophylactic intent when deemed appropriate per institutional protocol.<sup>20</sup> The main procedural steps are summarized in Fig 1.

### Clinical and Imaging Assessment and Follow-up

Intraoperative and postoperative complications were recorded according to the Clavien-Dindo classification.<sup>21</sup> In patients with pre- and postoperative cross-sectional imaging (CT and/or MR imaging), the VB height (VBH) was measured on midsagittal images at the anterior wall (ant-VBH), middle body (mid-VBH), and posterior wall (post-VBH) (Fig 2). The percentage of VBH gain was calculated as the ratio of gained height/preprocedural height. In patients with standing x-rays, the local kyphotic angle (LKA, kyphotic angle of the 2 adjacent vertebral bodies) and the vertebral kyphotic angle (VKA, kyphotic angle of the fractured vertebral body)<sup>22</sup> were measured pre- and postprocedure (Fig 2) and at follow-up. The percentage of kyphotic correction was calculated as the ratio of gained height/preprocedural height. All radiologic measurements were performed by 2 fellowship-trained neuroradiologists with 4 and 3 years of experience, respectively, not involved in the procedures.



**FIG 2.** A, Standing plain film shows a L1 VP with kyphotic angulation. *White lines* along the endplates of T12 and L2 indicate the LKA, while the *dashed white lines* along the L1 endplates indicate the VKA. B, Sagittal CT shows a pseudoarthrosis with a gas cleft in L1 and increased vertebral body height in supine decubitus positioning, in keeping with a mobile fracture. An additional fracture of T11 was treated with vertebroplasty. Sagittal fat-suppressed T2WI (C) shows posterior wall retropulsion and central canal stenosis without cord compression and an additional milder fracture at T11. Anterior-posterior intraprocedural fluoroscopic image (D) demonstrates SAIF implants, with pedicular screws inserted in the expanded stents before cement injection. Volume-rendering postprocedure CT (E) shows the SAIF treatment of L1 and vertebral augmentation at T11, T12, and L2. Postprocedural standing plain film (F) shows reduction of the LKA from 28° to 16° and of the VKA from 30° to 11°.

Preprocedural imaging was assessed to detect a cleft with pseudoarthrosis on CT/MR imaging and/or fracture mobility; fractures were categorized as mobile when VBH on standing views was reduced compared with supine views (Fig 2).

Clinical follow-up was performed at 1 and 6 months postoperatively and included the NRS (range, 0–10) and the Patient's Global Impression of Change scale (PGIC; range, 1 = extremely worse, 4 = unchanged, to 7 extremely better).<sup>23</sup> Kyphotic angles, mobilization of the implants, and refractures of the treated segment were assessed with standing x-rays.

### Statistical Analysis

Analyses used SPSS, Version 20.0.0 (IBM). Descriptive statistics for demographic and clinical data were expressed as median with interquartile range (IQR). Differences in VBH, LKA, VKA, and NRS scores before and after treatment were tested by the Wilcoxon matched-pairs test; comparison between mobile and nonmobile fracture groups was tested by the Wilcoxon unpaired test. A *P* value < .05 was considered statistically significant.

## RESULTS

### Patients, Procedures, and Safety

The consecutive series of patients with vertebra plana treated with SAIF consisted of 42 cases; 5 were excluded due to lack of

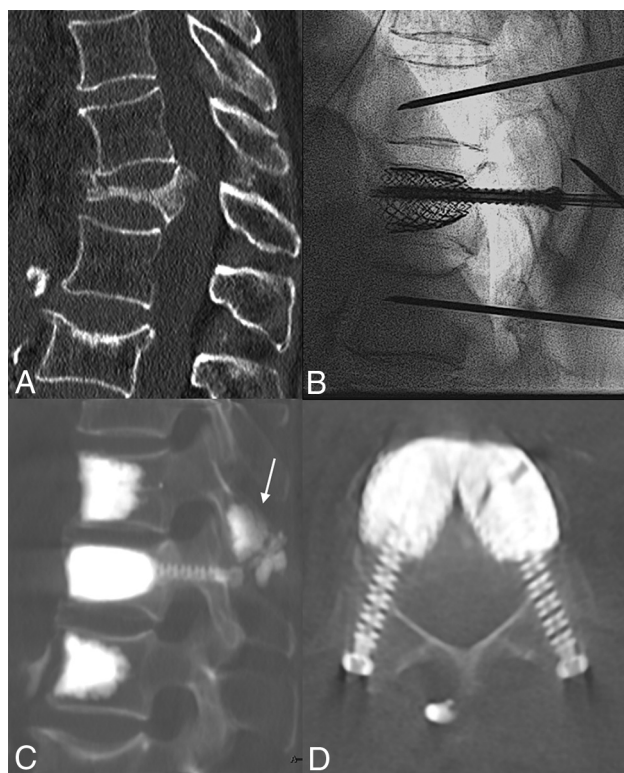
comparable pre- and postprocedure imaging. We, thus, included 37 SAIF procedures performed in 37 patients (11:26 male/female ratio; mean age, 81.6 years; range, 65–98 years). Between T3 and L4, 19/37 (51.3%) thoracic and 18/37 (48.6%) lumbar (overall, 27/37) (73%) fractures were located at the thoracolumbar junction (T10–L2). Thirty-four of 37 fractures were classified as osteoporotic fracture 4; three/37 fractures were classified as osteoporotic fracture 5 because of spinous process fracture (1/37) or mild posterior ligamentous complex lesions/edema (2/37) for which surgical instrumentation was withheld on the basis of the multidisciplinary spine care group recommendations. In 35/37 patients (94.6%), prophylactic vertebroplasty of adjacent levels was also performed (2/35 at the vertebra above, 33/35 above and below) at the operator's choice per institutional protocol. All procedures were successfully completed without symptomatic cement leakage at the index level or clinical or technical complications.

### Follow-up

Follow-up data with imaging and the patients' outcome scales were available for 32/37 (86.5%; among them, 30 patients had comparable pre- and postprocedure CT/MR imaging and 29 patients had pre- and postprocedure standing x-rays) patients at 1 month and for 28/37 (75.7%) at 6 months. The remaining patients were contacted by a nurse on the phone to ascertain that no specific

**Radiologic outcome: median measurements of anterior, middle, and posterior VBH, LKA, and VKA pre- and postoperatively (with IQR), for all fractures, mobile and nonmobile fracture groups**

	Preoperative (IQR)	Postoperative (IQR)	Median Gain	Correction Loss at 6 Months (IQR)
Ant VBH				
All	9.5 mm (8.0–13.0)	17 mm (15.0–19.25)	7 mm, +74% ( $P < .001$ )	
Mobile	11.5 mm (9.0–15.25)	18 mm (16.5–19.5)	7 mm, +64% ( $P < .001$ )	
Nonmobile	11 mm (5.5–12.5)	19 mm (16.5–17.5)	8 mm, +73% ( $P = .03$ )	
Mid VBH				
All	6 mm (5.0–7.75)	15.5 mm (13.0–17.25)	9 mm, +150% ( $P < .001$ )	
Mobile	6.5 mm (5.75–9.5)	16 mm (15.0–18.0)	9 mm, +138% ( $P < .001$ )	
Nonmobile	5 mm (4.5–5.5)	15.5 mm (13.5–16.75)	11 mm, +220% ( $P = .03$ )	
Post VBH				
All	17.5 mm (16.0–19.0)	20 mm (18.0–22.0)	3 mm, +17% ( $P < .001$ )	
Mobile	18 mm (16.0–19.25)	20 mm (18.5–23.5)	3 mm, +17% ( $P < .001$ )	
Nonmobile	17 mm (15.0–18.0)	21 mm (20.0–22.0)	4.5 mm, +26% ( $P = .04$ )	
LKA				
All	25° (12.0–29.0)	14° (6.0–22.0)	8° ( $P < .001$ )	1° (0.0–1.0)
Mobile	25° (15.5–31.5)	14° (6.0–22.0)	8° ( $P < .001$ )	1° (0.0–1.7)
Nonmobile	21.5° (11.25–27.75)	13° (4.5–15.0)	4.5° ( $P = .009$ )	1° (0.5–1.0)
VKA				
All	21° (12.0–27.0)	9° (5.5–12.0)	10° ( $P < .001$ )	0° (0.0–1.0)
Mobile	23° (12.0–27.0)	9° (5.5–12.0)	11° ( $P < .001$ )	0° (0.0–1.0)
Nonmobile	19.5° (13.25–22.5)	7° (3.75–12.0)	9.5° ( $P = .006$ )	0° (0.0–1.0)



**FIG 3.** Sagittal CT (A) shows a T12 VP, with segmental kyphosis and a T11 spinous process fracture. Intraoperative fluoroscopic lateral view (B) shows fracture reduction by the SAIF technique before cement augmentation. Postprocedural sagittal (C) and axial (D) CT images show the final results obtained with the SAIF construct. There is cement augmentation of the T11 spinous process fracture (arrow), which was particularly tender at palpation, and the prophylactic augmentation of the adjacent levels.

spinal problems had occurred, but in the absence of imaging and formal clinical data, those patients were not included in this analysis.

**Radiologic Outcome**

The Table summarizes the results.

**VBH.** Pre- and postoperative cross-sectional studies (CT or MR imaging) were available in 30/37 (81.1%) patients. In this group, the median ant-VBH, mid-VBH, and post-VBH were 9.5 mm (IQR = 8.0–13.0 mm), 6 mm (IQR = 5.0–7.75 mm), and 17.5 mm (IQR = 16.0–19.0 mm), respectively, preprocedure, and 17 mm (IQR = 15.0–19.25 mm), 15.5 mm (IQR = 13.0–17.25 mm), and 20 mm (IQR = 18.0–22.0 mm) postprocedure; the median height gain was 7 mm at the ant-VBH (+74%; range, 2–15 mm), 9 mm at the mid-VBH (+150%; range, 4–13 mm), and 3 mm at the post-VBH (+17%; range, 0–7 mm). All differences were statistically significant ( $P < .001$ ).

**LKA and VKA.** Pre- and postoperative standing x-rays were available for 29/37 (78.4%) patients.

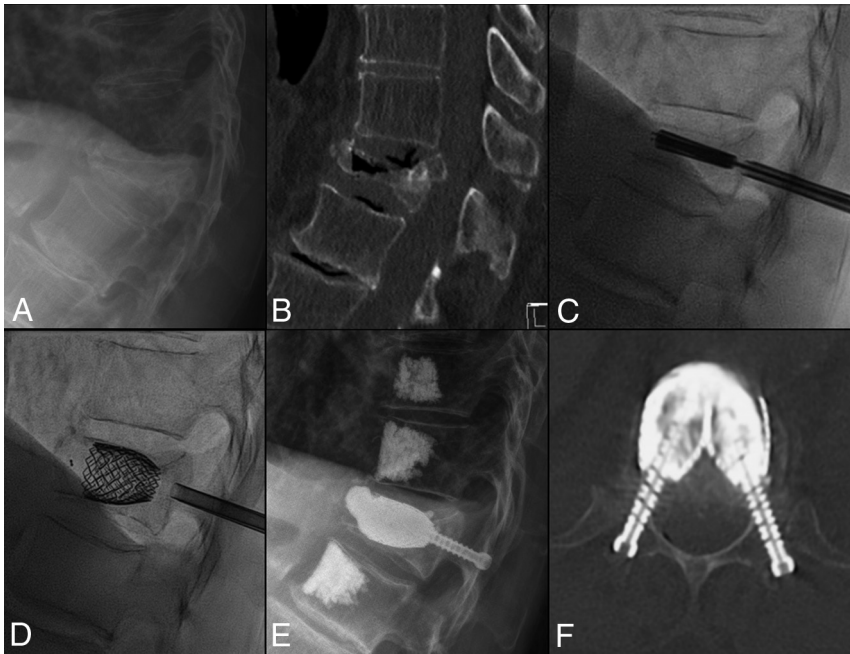
In this group, the median LKA was 25° preoperatively (IQR = 12.0°–29.0°), and 14° postoperatively (IQR = 6.0°–22.0°). The median gain was 8° (range, 0°–19°) and was statistically significant ( $P < .001$ ).

The median VKA was 21° preoperatively (IQR = 12.0°–27.0°) and 9.0° postoperatively (IQR = 5.5°–12.0°). The median gain was 10° (range, 1°–23°) and was statistically significant ( $P < .001$ ).

In the patients with 6 months' follow-up (28/37), the median LKA and VKA gains were substantially maintained, respectively, at 7° and 9°.

**Mobile and Nonmobile Fractures.** Among 29 patients with preoperative standing x-rays available, a mobile fracture was present in 19 (65.5%) patients.

In this group, the median VBH gain was 7.0 mm (IQR = 5.5–8.5 mm) at the ant-VBH, 9 mm (IQR = 6.5–11.0 mm) at the mid-



**FIG 4.** Standing plain film (A) and sagittal CT (B) show a T12 VP with pseudoarthrosis, gas cleft, and fracture mobility. Lateral intraprocedural fluoroscopic images before (C) and after (D) stent expansion with consequent fracture reduction. Postoperative standing plain film (E) demonstrates T12 height restoration and kyphosis correction, stable at 6 months' follow-up (F). Axial CT (F) at the T12 level shows the stent-cement complex reconstructing the vertebral body and the transpedicular screws cemented inside the stents acting as "anchors" to the posterior elements.

VBH, and 3 mm (IQR = 2.0–3.5 mm) at the post-VBH; the median correction of VKA and LKA was 11° (IQR = 5.0°–17.0°) and 8° (IQR = 7.0°–12.5°), respectively.

In patients with a nonmobile fracture (10/29), the median VBH gain was 8 mm (IQR = 7.0–9.75 mm) at the ant-VBH, 11 mm (IQR = 9.5–11.75 mm) at the mid-VBH, and 4.5 mm (IQR = 2.5–5.75 mm) at post-VBH; the median correction of VKA and LKA was 9.5° (IQR = 5.5°–15.5°) and 4.5° (IQR = 3.25°–7.75°), respectively.

The VBH and VKA corrections did not show significant differences between mobile and nonmobile fractures, while the LKA gain appeared greater in the mobile group, compared with nonmobile group, without reaching statistical significance ( $P = .07$ ).

#### Refractures during Follow-up

No refracture occurred. No salvage surgery or new procedure was necessary at the index level during the available follow-up.

#### Pain Assessment

The median preoperative NRS pain score was 8 (range, 5–10; IQR = 7.0–9.0), while it was 3 (range, 0–8; IQR = 2.0–5.0) after 1 month and 3 (range, 0–7; IQR = 2.0–4.0) after 6 months. The differences were significant ( $P < .001$ ). The median PGIC score was 6 (corresponding to "much better") after 1 month (range, 4–7; IQR = 5.0–7.0) and remained 6 after 6 months (range, 3–7; IQR = 6.0–7.0). No significant difference was observed between mobile and nonmobile fractures in patients' outcome scales ( $P = .35$ ).

## DISCUSSION

In this osteoporotic plana series, the SAIF technique was both feasible and safe. SAIF resulted in vertebral height restoration, kyphosis correction, and pain palliation. These results were sustained at 6 months' follow-up.

Vertebral compression fractures with VP morphology are considered severe fractures,<sup>24,25</sup> and surgical stabilization is generally recommended to restore segmental stability, allow early mobilization, and avoid pseudoarthrosis.<sup>10,26–28</sup> Kyphosis correction is important because kyphotic deformity is an independent risk factor for breathing difficulties and pulmonary complications, increasing morbidity and mortality.<sup>29,30</sup>

Open surgical treatment is typically recommended, including anterior instrumentation to reconstruct the anterior spinal column.<sup>14</sup> However, these approaches may result in implant failure due to high strain<sup>31,32</sup> and anterior or anterolateral approaches carrying higher risks of blood loss and respiratory complications in elderly and fragile patients.<sup>33</sup>

Vertebroplasty or BKP is less invasive and might provide pain relief but may represent an undertreatment for these severe fractures.<sup>4,6,8,34,35</sup>

Most published reports on the treatment of vertebral compression by BKP alone measured the postprocedure improvement of the VKA,<sup>36</sup> but this measure might not translate into an effective segmental kyphosis correction.<sup>1,37</sup> BKP might also be limited in effective kyphosis correction by the deflation effect before cement placement.<sup>38,39</sup> The use of third-generation, rigid, intrasomatic distraction devices, such as SpineJack (Stryker) has been reported as a potential minimally invasive transpedicular replacement of expandable cages and, combined with posterior instrumentation, has been reported as a possible solution to treat VP fractures.<sup>27</sup>

The SAIF technique applies a treatment rationale that is well-suited to patients with severe vertebral collapse. The rigid stents obtain and maintain predictable fracture reduction, avoid deflation effect, and create room for cement, thus reducing the risk of leakage. The metallic mesh of the VBS scaffolds the vertebral body from within, offering ample cross-sectional support for the disc endplates. Cement injection then solidifies the structure and support. Percutaneous pedicle screws anchor the VBS-cement complex to the posterior elements. In addition, the screws offer osteosynthesis for pedicular fractures and act to transfer the spinal load to the neural arch, unloading the middle column.<sup>16</sup> The "reinforced concrete" construct rebuilds the VB, offering a 360° nonfusion internal stabilization of the vertebra (Figs 3 and 4). Two biomechanical studies provide support for this approach in both neoplastic and osteoporotic models.<sup>7,40</sup>

In this series, SAIF obtained high degrees of VB height restoration, and VBH gain was much higher than previously reported with BKP.<sup>1</sup> Yokoyama et al,<sup>41</sup> using BKP, obtained 3.6-, 2.0-, and 0.5-mm VBH gain at the anterior, middle, and posterior VB, respectively. By means of the same measurements, SAIF obtained a median gain of 7.0, 9.0, and 3.0 mm.

LKA on standing plain radiographs was used to assess kyphosis correction. LKA has been demonstrated to be a valid and reliable measure of thoracic kyphosis in patients with osteoporosis, in addition to VKA.<sup>37</sup> The LKA correction is usually less than the VKA correction because it is also influenced by the adjacent disc height loss but more reliably assesses the real effect of the treatment on segmental kyphosis (Fig 2).

In the present series, the LKA and VKA median correction was 8° and 10°, respectively, outperforming the previously reported results achieved with BKP, in which the LKA correction ranged between 1.94° and 6.5° and the VKA correction ranged between 4.2° and 7.3°.<sup>37,42-44</sup> Diel et al<sup>45</sup> reported an average correction of LKA of 4.2° using VBS. Even when surgical posterior fixation was combined with vertebral augmentation, the LKA correction ranged between 5° and 9° in 3 studies.<sup>11</sup> A recent prospective study reported an LKA correction of 9° at 1-year follow-up, obtained with augmentation, posterior instrumentation, and arthrodesis, followed by a plastic thoracolumbar orthosis to be worn for 6 months postsurgery.<sup>26</sup> SAIF results on VBH and kyphosis correction were comparable with those obtained with 360° surgical approaches, but with a reduced complication rate.<sup>31</sup>

At 6-month follow-up, the achieved kyphosis correction was substantially stable, with an average loss of correction of only 1° at 6 months. In keeping with the previously reported results of Becker et al<sup>1</sup> and Yokoyama et al,<sup>41</sup> the LKA gain tended to be greater in the mobile fracture group, though the difference did not reach statistical significance, likely due to small numbers in the nonmobile group. Nevertheless, significant VBH and VKA correction was also obtained in nonmobile fractures. These results might be explained by the efficient distraction forces exerted by the stents and the avoidance of the deflation effect, with polymethylmethacrylate anchoring the entire complex to the vertebral body.

The axis of insertion of the vertebral body stent into the VB is of paramount importance to optimize craniocaudal distraction, fracture reduction, and height restoration. Pedicular access should, therefore, be adapted to optimize device placement inside the VB along an axis parallel to the anticipated alignment of the original prefracture endplates. The distraction performed perpendicular to this axis approximates the original prefracture shape of the VB and allows the device to achieve maximum expansion and fracture reduction.<sup>46</sup> With the plana morphology, trocar access is usually through the lower half of the pedicle (Figs 3 and 4).

Prophylactic vertebroplasty of adjacent levels, the role of which remains controversial, was performed in 35/37 patients. High-quality evidence supporting improved patient outcome has not been confirmed.<sup>47</sup> Of note, this study was performed in Switzerland where prophylactic augmentation is more commonly performed than in the United States.

Patients treated with SAIF had satisfactory pain relief and an overall subjective impression of improvement as measured by the

NRS and the PGIC score, respectively. While pain relief has been similarly reported by standard augmentation techniques,<sup>48</sup> the SAIF approach achieves greater improvement in kyphosis, potentially improving biomechanics, ambulation, and breathing function.

Patients requiring laminectomy were excluded from this series, but SAIF can be combined with decompression and posterior instrumentation when needed.

The main limitations of this study are the retrospective design and lack of a control group. Follow-up was generally limited to 6 months because our clinical practice does not require further medical visits for this fragile elderly population in the absence of persistent or new back pain. The single-center design limits its generalizability, and larger, multicenter prospective studies are warranted. Finally, the augmentation of the adjacent vertebral bodies (either to treat milder VCFs or for prophylactic intent) is an additional potential confounder with respect to pain relief. Of note, these specific vertebral body stents and percutaneous fenestrated screws lack US Food and Drug Administration approval, and these procedures have, thus far, all been performed in Europe.

## CONCLUSIONS

This study suggests that SAIF can be performed safely in patients with severe vertebral collapse. SAIF was effective in obtaining vertebral body height restoration, kyphosis correction, and pain relief in this cohort with stability of these results at the 6-month follow-up assessment. Based on these preliminary results, SAIF could overcome some of the limitations of standard vertebral augmentation and present a minimally invasive option in patients with osteoporotic vertebra plana.

Disclosure forms provided by the authors are available with the full text and PDF of this article at [www.ajnr.org](http://www.ajnr.org).

## REFERENCES

1. Becker S, Tuschel A, Chavanne A, et al. **Balloon kyphoplasty for vertebra plana with or without osteonecrosis.** *J Orthop Surg (Hong Kong)* 2008;16:14-19 [CrossRef Medline](#)
2. Schlaich C, Minne HW, Bruckner T, et al. **Reduced pulmonary function in patients with spinal osteoporotic fractures.** *Osteoporos Int* 1998;8:261-67 [CrossRef Medline](#)
3. Kado DM, Huang MH, Karlamangla AS, et al. **Hyperkyphotic posture predicts mortality in older community-dwelling men and women: a prospective study.** *J Am Geriatr Soc* 2004;52:1662-67 [CrossRef Medline](#)
4. Pedicelli A, Lozupone E, Gatto A, et al. **Vertebra plana: reappraisal of a contraindication to percutaneous vertebroplasty.** *Eur J Radiol* 2013;82:2303-08 [CrossRef Medline](#)
5. Sigaux J, Guignard S, Tuilier T, et al. **Efficacy and feasibility of vertebroplasty for severe vertebral fracture: a retrospective study of 12 vertebroplasties.** *Joint Bone Spine* 2013;80:328-31 [CrossRef Medline](#)
6. Young C, Munk PL, Heran MK, et al. **Treatment of severe vertebral body compression fractures with percutaneous vertebroplasty.** *Skeletal Radiol* 2011;40:1531-36 [CrossRef Medline](#)
7. La Barbera L, Cianfoni A, Ferrari A, et al. **Stent-screw assisted internal fixation of osteoporotic vertebrae: a comparative finite element analysis on SAIF technique.** *Front Bioeng Biotechnol* 2019;7:291 [CrossRef Medline](#)
8. Laredo JD. **Expert's comment concerning Grand Rounds case entitled "Kümmell's disease: delayed post-traumatic osteonecrosis of the vertebral body" (by R. Ma, R. Chow, F. H. Shen).** *Eur Spine J* 2010;19:1071-72 [CrossRef Medline](#)

9. Wagner AL, Baskurt E. Refracture with cement extrusion following percutaneous vertebroplasty of a large interbody cleft. *AJNR Am J Neuroradiol* 2006;27:230–31 [CrossRef Medline](#)
10. Dickman CA, Fessler RG, MacMillan M, et al. Transpedicular screw-rod fixation of the lumbar spine: operative technique and outcome in 104 cases. *J Neurosurg* 1992;77:860–70 [CrossRef Medline](#)
11. Lu W, Wang L, Xie C, et al. Analysis of percutaneous kyphoplasty or short-segmental fixation combined with vertebroplasty in the treatment of Kümmell disease. *J Orthop Surg Res* 2019;14:311 [CrossRef Medline](#)
12. El Saman A, Meier S, Sander A, et al. Reduced loosening rate and loss of correction following posterior stabilization with or without PMMA augmentation of pedicle screws in vertebral fractures in the elderly. *Eur J Trauma Emerg Surg* 2013;39:455–60 [CrossRef Medline](#)
13. Sawakami K, Yamazaki A, Ishikawa S, et al. Polymethylmethacrylate augmentation of pedicle screws increases the initial fixation in osteoporotic spine patients. *J Spinal Disord Tech* 2012;25:E28–35 [CrossRef Medline](#)
14. Sudo H, Ito M, Kaneda K, et al. Anterior decompression and strut graft versus posterior decompression and pedicle screw fixation with vertebroplasty for osteoporotic thoracolumbar vertebral collapse with neurologic deficits. *Spine J* 2013;13:1726–32 [CrossRef Medline](#)
15. Yang H, Pan J, Wang G. A review of osteoporotic vertebral fracture nonunion management. *Spine (Phila Pa 1976)* 2014;39:26 (Spec No.):B4–6 [CrossRef Medline](#)
16. Cianfoni A, Distefano D, Isalberti M, et al. Stent-screw-assisted internal fixation: The SAIF technique to augment severe osteoporotic and neoplastic vertebral body fractures. *J Neurointerv Surg* 2019;11:603–09 [CrossRef Medline](#)
17. Cianfoni A, Distefano D, Scarone P, et al. Stent screw-assisted internal fixation (SAIF): clinical report of a novel approach to stabilizing and internally fixing vertebrae destroyed by malignancy. *J Neurosurg Spine* 2020;32:507–18 [CrossRef Medline](#)
18. Distefano D, Scarone P, Isalberti M, et al. The “armed concrete” approach: stent-screw-assisted internal fixation (SAIF) reconstructs and internally fixates the most severe osteoporotic vertebral fractures. *J Neurointerv Surg* 2021;13:63–68 [CrossRef Medline](#)
19. Schnake KJ, Blattert TR, Hahn P, et al; Spine Section of the German Society for Orthopaedics and Trauma. Classification of osteoporotic thoracolumbar spine fractures: recommendations of the spine section of the German Society for Orthopaedics and Trauma (DGOU). *Global Spine J* 2018;8:46S–49S [CrossRef Medline](#)
20. Kobayashi N, Numaguchi Y, Fuwa S, et al. Prophylactic vertebroplasty: cement injection into non-fractured vertebral bodies during percutaneous vertebroplasty. *Acad Radiol* 2009;16:136–43 [CrossRef Medline](#)
21. Dindo D, Demartines N, Clavien PA. Classification of surgical complications: a new proposal with evaluation in a cohort of 6336 patients and results of a survey. *Ann Surg* 2004;240:205–13 [CrossRef Medline](#)
22. Ulmar B, Brunner A, Gühring M, et al. Inter- and intraobserver reliability of the vertebral, local and segmental kyphosis in 120 traumatic lumbar and thoracic burst fractures: evaluation in lateral x-rays and sagittal computed tomographies. *Eur Spine J* 2010;19:558–66 [CrossRef Medline](#)
23. Maughan EF, Lewis JS. Outcome measures in chronic low back pain. *Eur Spine J* 2010;19:1484–94 [CrossRef Medline](#)
24. Ito M, Kaneda K, et al. Osteopenia: vertebrectomy and fusion. In: Herkowitz H, Dvorak J, Bell GR, et al. *The Lumbar Spine*. 3rd ed. Lippincott Williams and Wilkins; 2004:683–89
25. Sudo H, Ito M, Abumi K, et al. One-stage posterior instrumentation surgery for the treatment of osteoporotic vertebral collapse with neurological deficits. *Eur Spine J* 2010;19:907–15 [CrossRef Medline](#)
26. Katsumi K, Hirano T, Watanabe K, et al. Surgical treatment for osteoporotic thoracolumbar vertebral collapse using vertebroplasty with posterior spinal fusion: a prospective multicenter study. *Int Orthop* 2016;40:2309–15 [CrossRef Medline](#)
27. Vanni D, Pantalone A, Magliani V, et al. Corpectomy and expandable cage replacement versus third generation percutaneous augmentation system in case of vertebra plana: rationale and recommendations. *J Spine Surg* 2017;3:379–86 [CrossRef Medline](#)
28. Rajasekaran S, Kanna RM, Schnake KJ, et al. Osteoporotic thoracolumbar fractures-how are they different?-classification and treatment algorithm. *J Orthop Trauma* 2017;31(Suppl 4):S49–56 [CrossRef Medline](#)
29. Hirsch JA, Chandra RV, Carter NS, et al. Number needed to treat with vertebral augmentation to save a life. *AJNR Am J Neuroradiol* 2020;41:178–82 [CrossRef Medline](#)
30. Hinde K, Maingard J, Hirsch JA, et al. Mortality outcomes of vertebral augmentation (vertebroplasty and/or balloon kyphoplasty) for osteoporotic vertebral compression fractures: a systematic review and meta-analysis. *Radiology* 2020;295:96–103 [CrossRef Medline](#)
31. Oda I, Abumi K, Yu BS, et al. Types of spinal instability that require interbody support in posterior lumbar reconstruction: an in vitro biomechanical investigation. *Spine (Phila Pa 1976)* 2003;28:1573–80 [Medline](#)
32. Singh V, Mahajan R, Das K, et al. Surgical trend analysis for use of cement augmented pedicle screws in osteoporosis of spine: a systematic review (2000-2017). *Global Spine J* 2019;9:783–95 [CrossRef Medline](#)
33. Kanayama M, Ishida T, Hashimoto T, et al. Role of major spine surgery using Kaneda anterior instrumentation for osteoporotic vertebral collapse. *J Spinal Disord Tech* 2010;23:53–56 [CrossRef Medline](#)
34. Jacobson RE, Granville M, Hatgis J, et al. Low volume vertebral augmentation with Cortoss® cement for treatment of high degree vertebral compression fractures and vertebra plana. *Cureus* 2017;9:e1058 [CrossRef Medline](#)
35. Gangi A, Sabharwal T, Irani FG, Standards of Practice Committee of the Society of Interventional Radiology, et al. Quality assurance guidelines for percutaneous vertebroplasty. *Cardiovasc Intervent Radiol* 2006;29:173–78 [CrossRef Medline](#)
36. Wang B, Zhao CP, Song LX, et al. Balloon kyphoplasty versus percutaneous vertebroplasty for osteoporotic vertebral compression fracture: a meta-analysis and systematic review. *J Orthop Surg Res* 2018;13:264 [CrossRef Medline](#)
37. Pradhan BB, Bae HW, Kropf MA, et al. Kyphoplasty reduction of osteoporotic vertebral compression fractures: correction of local kyphosis versus overall sagittal alignment. *Spine (Phila Pa 1976)* 2006;31:435–41 [CrossRef Medline](#)
38. Wang D, Zheng S, Liu A, et al. The role of minimally invasive vertebral body stent on reduction of the deflation effect after kyphoplasty: a biomechanical study. *Spine (Phila Pa 1976)* 2018;43:E341–47 [CrossRef Medline](#)
39. Feltes C, Fountas KN, Machinis T, et al. Immediate and early post-operative pain relief after kyphoplasty without significant restoration of vertebral body height in acute osteoporotic vertebral fractures. *Neurosurg Focus* 2005;18:E5 [CrossRef Medline](#)
40. La Barbera L, Cianfoni A, Ferrari A, et al. Stent screw-assisted internal fixation (SAIF) of severe lytic spinal metastases: a comparative finite element analysis of the SAIF technique. *World Neurosurg* 2019;128:E370–77 [CrossRef Medline](#)
41. Yokoyama K, Kawanishi M, Yamada M, et al. In not only vertebroplasty but also kyphoplasty, the resolution of vertebral deformities depends on vertebral mobility. *AJNR Am J Neuroradiol* 2013;34:1474–78 [CrossRef Medline](#)
42. Voggenreiter G. Balloon kyphoplasty is effective in deformity correction of osteoporotic vertebral compression fractures. *Spine (Phila Pa 1976)* 2005;30:2806–12 [CrossRef Medline](#)
43. Xu C, Liu HX, Xu HZ. Analysis of related factors on the deformity correction of balloon kyphoplasty. *AJNR Am J Neuroradiol* 2014;35:202–06 [CrossRef Medline](#)



44. Lee JH, Kwon JT, Kim YB, et al. **Segmental deformity correction after balloon kyphoplasty in the osteoporotic vertebral compression fracture.** *J Korean Neurosurg Soc* 2007;42:371–76 [CrossRef Medline](#)
45. Diel P, Röder C, Perler G, et al. **Radiographic and safety details of vertebral body stenting: results from a multicenter chart review.** *BMC Musculoskelet Disord* 2013;14:233 [CrossRef Medline](#)
46. Cianfoni A. **If you aim at height restoration, mind the access!** In: Beall D, Brook AI, Chambers MR, et al. *Vertebral Augmentation: The Comprehensive Guide to Vertebroplasty, Kyphoplasty, and Implant Augmentation.* Thieme; 2020:237–40
47. Yen CH, Teng MM, Yuan WH, et al. **Preventive vertebroplasty for adjacent vertebral bodies: a good solution to reduce adjacent vertebral fracture after percutaneous vertebroplasty.** *AJNR Am J Neuroradiol* 2012;33:826–32 [CrossRef Medline](#)
48. Halvachizadeh S, Stalder AL, Bellut D, et al. **Systematic review and meta-analysis of 3 treatment arms for vertebral compression fractures: a comparison of improvement in pain, adjacent-level fractures, and quality of life between vertebroplasty, kyphoplasty, and nonoperative management.** *JBJS Rev* 2021;9 [CrossRef Medline](#)