

Are your **MRI contrast agents** cost-effective?

Learn more about generic **Gadolinium-Based Contrast Agents**.



**FRESENIUS
KABI**

caring for life

AJNR

Imaging the Tight Orbit: Radiologic Manifestations of Orbital Compartment Syndrome

C. Maier, N. Thieme, B. Beck-Broichsitter, N.L. Beetz, T.C. Walter-Rittel, K. Rubarth, M. Heiland, K. Kreuzer, S. Koerdt and J.O. Voss

This information is current as of April 19, 2024.

AJNR Am J Neuroradiol published online 30 March 2023
<http://www.ajnr.org/content/early/2023/03/30/ajnr.A7840>

Imaging the Tight Orbit: Radiologic Manifestations of Orbital Compartment Syndrome

C. Maier, N. Thieme, B. Beck-Broichsitter, N.L. Beetz, T.C. Walter-Rittel, K. Rubarth, M. Heiland, K. Kreutzer, S. Koerdt, and J.O. Voss



ABSTRACT

BACKGROUND AND PURPOSE: Orbital compartment syndrome is a sight-threatening emergency caused by rising pressure inside the orbit. It is usually diagnosed clinically, but imaging might help when clinical findings are inconclusive. This study aimed to systematically evaluate imaging features of orbital compartment syndrome.

MATERIALS AND METHODS: This retrospective study included patients from 2 trauma centers. Proptosis, optic nerve length, posterior globe angle, morphology of the extraocular muscles, fracture patterns, active bleeding, and superior ophthalmic vein caliber were assessed on pretreatment CT. Etiology, clinical findings, and visual outcome were obtained from patient records.

RESULTS: Twenty-nine cases of orbital compartment syndrome were included; most were secondary to traumatic hematoma. Pathologies occurred in the extraconal space in all patients, whereas intraconal abnormalities occurred in 59% (17/29), and subperiosteal hematoma in 34% (10/29). We observed proptosis (affected orbit: mean, 24.4 [SD, 3.1] mm versus contralateral: 17.7 [SD, 3.1] mm; $P < .01$) as well as stretching of the optic nerve (mean, 32.0 [SD, 2.5] mm versus 25.8 [SD, 3.4] mm; $P < .01$). The posterior globe angle was decreased (mean, 128.7° [SD, 18.9°] versus 146.9° [SD, 6.4°]; $P < .01$). In 69% (20/29), the superior ophthalmic vein was smaller in the affected orbit. No significant differences were detected regarding the size and shape of extraocular muscles.

CONCLUSIONS: Orbital compartment syndrome is characterized by proptosis and optic nerve stretching. In some cases, the posterior globe is deformed. Orbital compartment syndrome can be caused by an expanding pathology anywhere within the orbit with or without direct contact to the optic nerve, confirming the pathophysiologic concept of a compartment mechanism.

ABBREVIATIONS: EOM = extraocular muscles; OCS = orbital compartment syndrome

The orbital compartment syndrome (OCS) is a sight-threatening emergency caused by increasing pressure inside the orbital cavity. The tissues in the orbital pyramid are bound by 4 osseous walls and anteriorly by the orbital septum, canthal ligaments, and tarsal plates of the eyelids. There is only limited capacity for volume expansion through protrusion of the eye bulb. Therefore, rapidly expanding orbital lesions can increase

intraorbital pressure precipitously, compromising intraorbital structures. Common space-occupying pathologies underlying the volume expansion are traumatic or iatrogenic intraorbital/retrobulbar bleeding, emphysema, and infection.¹ The pathophysiology of the resulting neuropathy is still unclear. Different theories exist including direct compression of vulnerable neurosensory orbital tissues and ischemia. Ischemia may be attributed to arterial occlusion or compression of venous outflow channels in the context of increased intraorbital pressure.¹⁻⁴

The key symptom of a fulminant OCS is progressive vision impairment with the risk of permanent vision loss. Early signs on the ophthalmologic examination include a relative afferent pupillary defect, deficient pupillary light reflex, increased intraocular pressure, or impaired motility.^{1,5} Clinical symptoms can be missing initially, but when the rising intraorbital pressure exceeds the mean arterial pressure, a critical reduction in tissue perfusion and oxygen supply results. The pathophysiology is considered to be similar to that of compartment syndrome in the extremities.⁶⁻⁸ Progressively tense and painful proptosis with a hard eyeball reflects an orbit under pressure also known as a tight orbit.⁹

Received November 27, 2022; accepted after revision March 4, 2023.

From the Departments of Radiology (C.M., N.T., N.L.B., T.C.W.-R.) and Oral and Maxillofacial Surgery (B.B.-B., M.H., K.K., S.K., J.O.V.), Charité-Universitätsmedizin Berlin, corporate member of Freie Universität Berlin, Humboldt-Universität zu Berlin, Berlin, Germany; Department of Radiology (C.M.), Center for Advanced Imaging Innovation and Research, New York University School of Medicine, New York, New York; Department of Oral and Maxillofacial Surgery (B.B.-B.), Katharinenhospital Stuttgart, Stuttgart, Germany; and Berlin Institute of Health (K.R., J.O.V.), Berlin, Germany.

C. Maier and N. Thieme contributed equally to this work.

Please address correspondence to Christoph Maier, MD, Department of Radiology, Charité-Universitätsmedizin Berlin, corporate member of Freie Universität Berlin, Humboldt-Universität zu Berlin, and Berlin Institute of Health, Augustenburger Platz 1, 13353 Berlin, Germany; e-mail: christoph.maier@charite.de

Indicates article with online supplemental data.

<http://dx.doi.org/10.3174/ajnr.A7840>

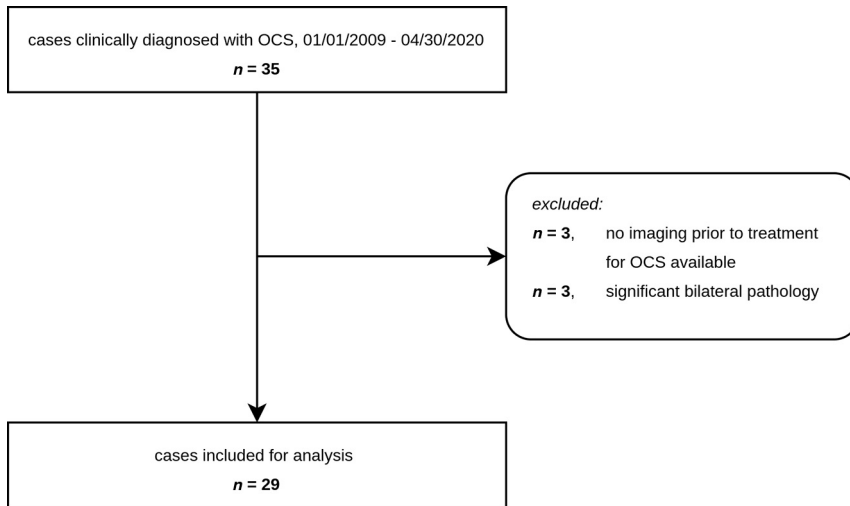


FIG 1. Patient flow chart.

Rapid recognition of the condition and initiation of surgical decompression is paramount to avert permanent vision loss. OCS is considered a clinical diagnosis characterized by proptosis and a firm globe, reduced visual acuity, and impaired ocular motility. However, clinical examination can be impeded in patients who are unconscious or who have received opioids (impairing pupillary reflexes), in children, and in the presence of profuse periorbital hematoma, which limits palpation of the globe. Various case series have proposed imaging features that may aid the diagnosis in clinically ambiguous cases.^{10,11} The purpose of this study was to systematically evaluate radiologic signs in a patient cohort with posttraumatic OCS.

MATERIALS AND METHODS

Study Design and Patient Collective

Ethics approval was granted by our institution's ethical review board (file number EA4/098/20, Charité–Universitätsmedizin Berlin). For this retrospective study, all patients clinically diagnosed with OCS at the Department of Maxillofacial Surgery of 2 academic level I trauma centers between January 1, 2009, and April 30, 2020, were retrieved from the electronic medical system. A subset of these patients had been included in a previously published study on clinical parameters of OCS (16 cases; timeframe, January 1, 2012, to May 31, 2015).¹² Three patients were excluded because no CT imaging covering the orbits had been performed before the initiation of surgical or medical treatment for OCS. Three further patients were excluded because the bony landmarks required for image analysis were obscured or shifted by severe, bilateral, midfacial injuries. A flow chart of included patients is shown in Fig 1.

Clinical Data

Clinical information was extracted from electronic and paper medical records, including the etiology, initial clinical findings, ophthalmologic status, therapeutic procedures (surgical and/or medical), long-term anticoagulant or antiplatelet medication, and final outcome.

Image Acquisition

Due to the retrospective nature of our study, imaging protocols were heterogeneous with regard to parameters such as scanner hardware, acquisition mode (incremental-versus-helical), IV contrast agent administration, radiation dose, and reconstruction kernels. In all cases included in the analysis, the orbits were completely depicted and image quality was sufficient. When available, the soft-tissue kernel was used for the analysis (in 4/29 cases, only bone kernel images were available for analysis). Section thickness ranged from 0.5 to 1.25 mm. IV contrast had been administered in 14/29 cases.

Image Analysis

All images were analyzed using Visage 7.1.15 (Visage Imaging). Type and localization of the orbital pathology, possible concomitant craniofacial fractures, active intraorbital bleeding (if contrast-enhanced imaging was available), and the caliber of the superior ophthalmic vein were qualitatively assessed (C.M., 6 years of experience in head and neck imaging).

Proptosis, optic nerve length, and posterior globe angle were quantified. Each patient's unaffected orbit served as an intraindividual control. Globe displacement or motility disorders in the affected orbit often made it impossible to assess the relevant anatomy on both sides in 1 imaging plane. Therefore, we modified established methods for these parameters^{10,13} as follows, with measurements being obtained in a plane reformatted respective to the pertinent anatomy, separately for each side. Proptosis is the distance between the interzygomatic line and the corneal apex; optic nerve length, the distance between the orbital aperture of the optic canal and the scleral contour at the optic nerve head; and posterior globe angle, the angle between the tangents at the scleral contours, measured in a plane bisecting the optic nerve head, and the center of the lens. The size and shape of the extraocular muscles (EOM) were assessed on the plane perpendicular to the axis of the optic nerve, where the EOM size is maximal. Size was defined as cross-sectional area, assuming an elliptical shape:

$$A = \pi \times \frac{\text{Long Axis} \times \text{Short Axis}}{2}$$

Muscle shape was analyzed by determining the eccentricity of the elliptical cross-section, in which a value of zero represents a perfect circle and higher values indicate more oblong shapes:

$$e = \sqrt{1 - \left(\frac{\text{Short Axis}}{\text{Long Axis}}\right)^2}$$

Because the superior rectus muscle cannot be reliably discriminated from the levator palpebrae superioris muscle on CT, these 2 muscles were measured together (termed "superior group"). In a few cases, EOM size and superior ophthalmic vein caliber could not be determined because these structures were obscured by

Clinical data^a

Variable	All Patients (n = 29)
Age (yr) ^b	62 [SD, 23] (22–102)
Sex	
Female	14/29 (48)
Male	15/29 (51)
Initial trauma mechanism	
Stumbling/fall	16/29 (55)
Assault	7/29 (24)
Motor vehicle crash	3/29 (10)
Fall from great height	2/29 (7)
Unknown	1/29 (3)
Affected eye	
Left	22/29 (76)
Right	7/29 (24)
Antithrombotic medication	
None	11/29 (38)
Antiplatelet	7/29 (24)
Anticoagulation	5/29 (17)
Antiplatelet + anticoagulation	2/29 (7)
Unknown	4/29 (14)

^a Unless indicated, data are number of patients, and data in parentheses are percentages.

^b Data are means, and range is given in parentheses.

surrounding hematoma or because of excessive image noise. In addition to analyzing the pretherapeutic CT studies, follow-up MR imaging was evaluated for potential causes of vision loss in the globe, optic nerve, and brain parenchyma when available.

Statistical Analysis

Data are reported as means, and the 95% confidence intervals were computed. To test for statistical significance, we used the *t* test or paired *t* test. Statistical analysis was performed using R statistical and computing software, Version 3.5.2 (<http://www.r-project.org/>).

RESULTS

Clinical Parameters

A total of 29 patients were included in the study. Clinical parameters are summarized in the Table. All patients had been initially admitted to the hospital for craniofacial trauma involving the orbits. Of note, however, in 3 cases, OCS was diagnosed only after orbital fractures had already been treated surgically.

Initial visual examination results in the emergency department varied, ranging from relative afferent pupillary defect, impaired pupillary light reflex, anisocoria, or even blindness of the patient. Other clinical findings included a tense, painful hard eyeball; proptosis; impaired ocular motility; monocular hematoma; and hyposphagma or chemosis.

The OCS was treated by surgical intervention in most cases (27/29 patients). Conservative treatment was pursued in 1 patient without substantial visual impairment and in 1 moribund patient for whom the legal guardian declined a surgical intervention. Surgical decompression was achieved by different approaches, mainly lateral canthotomy and cantholysis or in combination with a transseptal orbital incision. In 2 patients, additional bony wall decompression was performed. Adjuvant treatment in patients undergoing surgery included antibiotics, mainly β -lactam compounds, and steroids.

Conservative treatment included systemic mannitol, carbonic anhydrase inhibitors, as well as local travoprost and timolol.

Vision could be preserved or restored in 20 patients. Visual acuity ranged from hand movement and counting fingers to full vision and was also influenced by pre-existing conditions. In 6 patients, loss of vision persisted at discharge (of note, the ophthalmic artery had been sacrificed by catheter embolization in 1 patient due to surgically uncontrollable hemorrhage). In 3 patients, visual outcome could not be fully evaluated because of the death of the patient or dementia.

Qualitative Imaging Results

Various space-occupying lesions were found in the affected orbits. While intraorbital hematoma was observed in all patients, intraorbital emphysema occurred in 31% (9/29) of patients, and intraorbitally displaced bone fragments, in 17% (5/29). Regarding the sublocalizations of these intraorbital lesions, the extraconal space was affected in all patients, whereas the intraconal space was affected in 59% (17/29), and the subperiosteal space, in 34% (10/29).

In total, ≥ 1 concomitant craniofacial fracture was detected in 86% of patients (25/29). The most frequent fracture patterns were in the orbital floor ($n = 11$), zygoma ($n = 9$), and medial orbital wall ($n = 6$), but more serious injuries involving the anterior skull base or complex midfacial fractures at various Le Fort levels were also observed.

Active bleeding was observed in 50% (7/14) of patients who had been examined with contrast-enhanced CT. The superior ophthalmic vein in the affected orbit was smaller than in the contralateral side in 20 cases, larger in 1 case, equivalent in 7 cases, and could not be assessed in 1 case.

Follow-up MR imaging performed after treatment for OCS was available in 4/29 patients. Notably, diffusion restriction in the optic nerve was observed in 1 patient with permanent vision loss (Online Supplemental Data).

Quantitative Imaging Results

Figure 2 summarizes the quantitative imaging findings in a typical case of OCS; see the Online Supplemental Data for additional illustrative figures. OCS resulted in marked proptosis (Fig 3A, affected orbit: mean, 24.4 [SD, 3.1] mm [95% CI, 23–26 mm] versus the contralateral orbit: 17.7 [SD, 3.1] mm [95% CI, 17–19 mm]; $P < .01$) as well as stretching of the optic nerve (Fig 3B, affected orbit: mean, 32.0 [SD, 2.5] mm [95% CI, 31–33 mm] versus the contralateral orbit: 25.8 [SD, 3.4] mm [95% CI, 25–27 mm]; $P < .01$). We also observed a decrease of the posterior globe angle, though variability was higher for this parameter (Fig 3C, affected orbit: mean, 128.7° [SD, 18.9°] [95% CI, 121°–136°] versus the contralateral orbit: 146.9° [SD, 6.4°] [95% CI, 144°–149°]; $P < .01$).

To characterize the size and shape of the EOM, we determined the cross-sectional area and eccentricity, respectively. Eccentricity is a measure of the “roundness” of such shapes with a value of zero representing a perfect circle and higher values indicating more oblong shapes. We did not find significant differences in the muscle cross-sectional area between the affected orbit and the contralateral control (Online Supplemental Data) (affected orbit: mean, 98.7 [SD, 40.3] mm² [95% CI, 82–115 mm²] versus the contralateral orbit: 102.3 [SD, 23.0] mm² [95% CI, 93–111 mm²] for

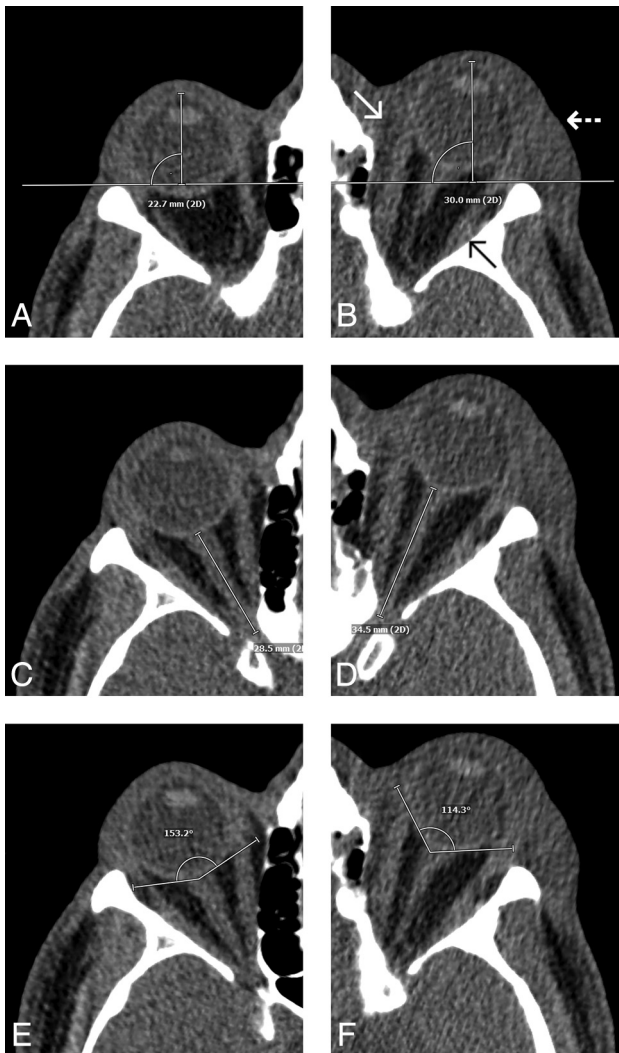


FIG 2. Representative case with traumatic left-sided OCS due to intraorbital hematoma in the extraconal space (*white arrow*) and in the subperiosteal space (*black arrow*). Imaging is helpful to differentiate intraorbital hematoma from periorbital hematoma (*dashed white arrow*), which is anterior to the orbital septum and therefore does not lead to compartment syndrome. Intraorbital hematoma in this case results in increased proptosis (A and B), optic nerve stretching (C and D), and a decreased posterior globe angle (E and F). Besides stretching of the optic nerve, subtle thinning of the nerve and loss of normal undulation can be observed. Note that the angulation is slightly different for each side because the planes of measurement were reconstructed separately relative to the respective anatomic landmarks.

the medial rectus; 86.7 [SD, 25.9] mm² [95% CI, 76–98 mm²] versus 82.8 [SD, 20.0] mm² [95% CI, 75–91 mm²] for the inferior rectus; 88.1 [SD, 40.0] mm² [95% CI, 72–104 mm²] versus 85.1 [SD, 22.9] mm² [95% CI, 76–94 mm²] for the lateral rectus; 84.9 [SD, 22.8] mm² [95% CI, 76–94 mm²] versus 90.4 [SD, 23.2] mm² [95% CI, 81–100 mm²] for the superior group). Likewise, no significant differences were detected in the eccentricity of any of the muscles (Online Supplemental Data) (affected orbit: mean, 0.92 [SD, 0.05] [95% CI, 0.91–0.94] versus the contralateral orbit: 0.95 [SD, 0.02] [95% CI, 0.94–0.95] for the medial rectus; 0.93 [SD, 0.04] [95% CI, 0.91–0.94] versus 0.94 [SD, 0.03] [95% CI, 0.93–

0.95] for the inferior rectus; 0.93 [SD, 0.04] [95% CI, 0.91–0.95] versus 0.95 [SD, 0.04] [95% CI, 0.93–0.96] for the lateral rectus; and 0.93 [SD, 0.03] [95% CI, 0.92–0.95] versus 0.94 [SD, 0.01] [95% CI, 0.93–0.94] for the superior group).

Visual Outcome

To evaluate whether imaging findings can help predict clinical outcome, we correlated the differences in quantitative parameters between the affected orbit and the contralateral orbit with visual outcome (Fig 4). The difference in proptosis was similar in both groups (lost vision: mean, 5.95 [SD, 2.92] mm versus preserved vision: 6.64 [SD, 2.63] mm; $P = .6$). Likewise, no significant differences were detected in optic nerve length difference (lost vision: mean, 6.55 [SD, 2.33] mm versus preserved vision: 5.82 [SD, 2.67] mm; $P = .5$) or posterior globe angle difference (lost vision: mean, 20.9° [SD, 23.7°] versus preserved vision: 16.8° [SD, 17.4°]; $P = .7$).

DISCUSSION

In this retrospective study, we systematically evaluated the radiologic signs of OCS, which is a rare-but-vision-threatening emergency, requiring prompt recognition and treatment. To our knowledge, this retrospective data set comprising 29 patients with trauma represents the largest systematic study on OCS reported to date. We observed that OCS invariably led to marked proptosis and optic nerve stretching in the affected orbit, and a reduced posterior globe angle occurred in some cases.

In this study, intraorbital volume expansion was mostly due to hematoma and emphysema, occurring in intraconal, extraconal, and/or subperiosteal locations. In a substantial number of the cases, the space-occupying lesions were not in direct contact with the optic nerve, which is in keeping with a compartment hypothesis. Along this line, previous experimental cadaver studies have demonstrated that volume expansion inside the orbital cavity causes a rapid rise in intraorbital and intraocular pressure.^{14,15} It seems reasonable that this increase in pressure damages the delicate neuronal structures in the retina and/or optic nerve. In one of our patients who coincidentally underwent MR imaging after emergency decompression for OCS, we observed marked diffusion restriction in the optic nerve, consistent with infarction. However, the exact pathophysiology of neuronal damage in OCS is still not fully understood because direct pressure damage, arterial occlusion, and/or venous congestion may be implicated. We observed that the diameter of the superior ophthalmic vein in the affected orbit was overwhelmingly reduced, probably representing venous collapse secondary to increased intraorbital pressure. Venous collapse might serve as a clue that compromised venous drainage plays a role in optic nerve damage in OCS, which can occur at lower pressures than frank arterial infarction. In the setting of sudden vision loss following facial trauma, other mechanisms of visual compromise such as direct injury of the globe, traumatic optic neuropathy, or orbital apex syndrome also have to be considered.^{16–18} It is crucial to differentiate these conditions by ophthalmologic examination and/or imaging studies because the treatment approach depends on the underlying pathophysiology.

Because our collective was recruited from patients under the care of maxillofacial surgeons, all patients had craniofacial trauma involving the orbit. OCS was accompanied by fractured orbital

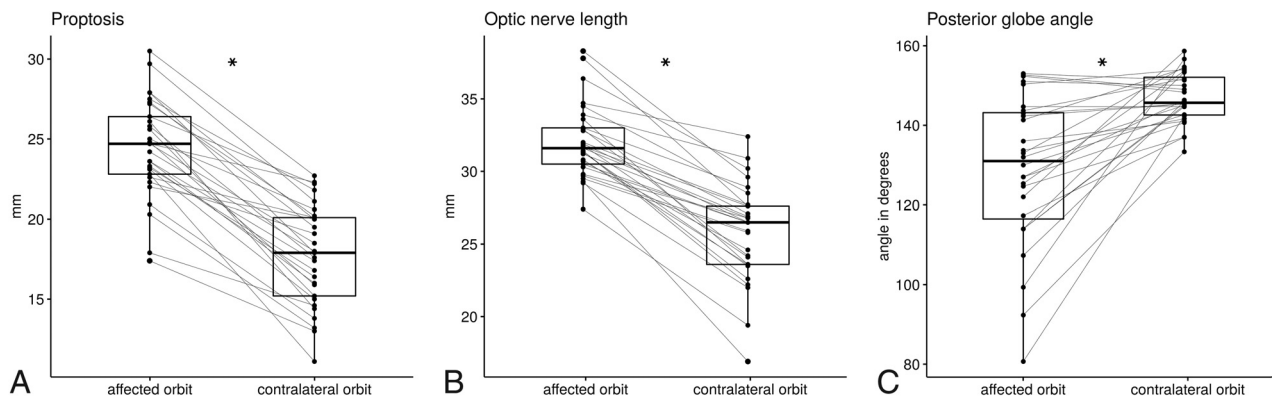


FIG 3. Quantitative imaging data. Boxplots show the distribution of proptosis, defined as the distance between the interzygomatic line and the corneal apex (A); optic nerve length, defined as the distance between the orbital aperture of the optic canal and the scleral contour at the optic nerve head (B); and posterior globe angle, as measured by drawing tangents on the scleral contours at the optic nerve head (C). Each affected orbit is connected to its contralateral control by a *thin line*. The asterisk indicates $P < .05$.

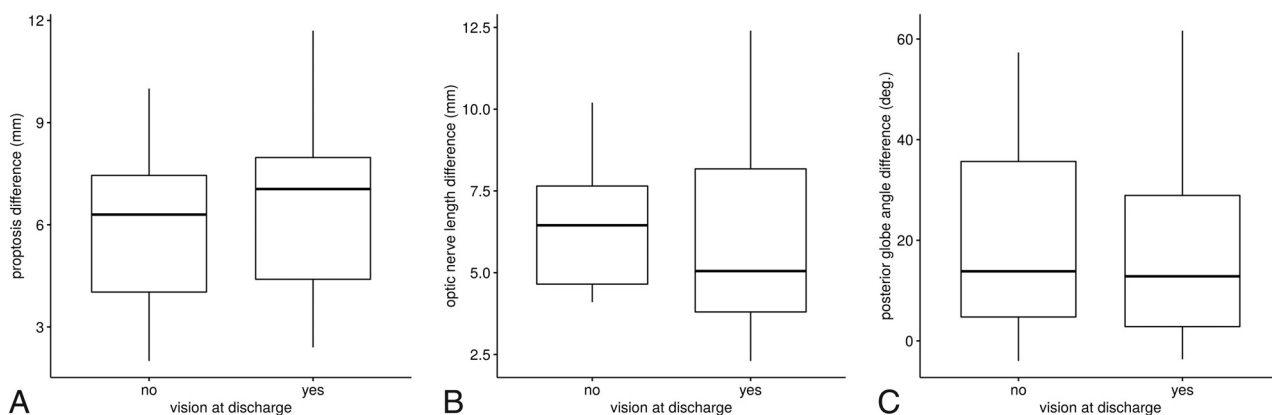


FIG 4. Differences between the affected orbit and the contralateral orbit in patients with vision loss at discharge ($n = 6$) and in patients with preserved vision ($n = 20$) regarding proptosis (A), optic nerve length (B), and posterior globe angle (C). No significant differences were detected. For 3 patients, data on visual outcome were unavailable.

walls in the overwhelming majority of patients. In only 3 cases was OCS diagnosed after fractures involving the orbital walls had already been surgically addressed. Whether OCS in these 3 cases was due to the primary trauma or occurred as a complication of surgery or a combination of both cannot be determined with certainty in this retrospective study. OCS occurred even in the presence of fracture patterns that expand the bony orbit, eg, dislocated fractures of the orbital floor. This finding may be explained by the periosteal sleeve and/or intraorbital fibrous septa remaining intact, thereby precluding a decompressive effect of the fracture. Alternatively, the amount of hematoma and emphysema may exceed the volume gained through expansion of the osseous wall. Similarly, Zogheib et al¹⁹ recently reviewed 18 cases of OCS with concomitant displaced orbital fractures. OCS can also result from a range of nontraumatic lesions.¹ While we only investigated a trauma collective, we assume that nontraumatic OCS leads to a similar imaging phenotype as described here.

Various measurements based on orbital CT have been proposed in the literature to stratify the severity of OCS and to predict possible clinical outcomes. In a series of 10 patients, Dalley et al¹⁰ reported that the severity of posterior globe tenting correlated with visual impairment, with a posterior globe angle of $<120^\circ$ indicating severe proptosis and unfavorable outcomes. A posterior

globe angle of 120° – 130° was reported to correlate with mild visual impairment and good clinical recovery.¹⁰ Using a different angle of measurement between the medial rectus insertion and the optic nerve, Oester et al¹¹ also found that deformity of the posterior globe was more pronounced in patients who lost their vision. In our data, we found no significant differences in the quantitative imaging parameters between patients who lost vision in the affected orbit and patients with preserved vision.

These results must be interpreted with caution, however, because it can be expected that the elapsed time between the initial trauma (or symptom onset) and intervention is a decisive factor on visual outcome. Moreover, interindividual differences in the anatomy (size of the orbital cavity), time point of imaging, as well as the extent and timeframe of volume expansion might affect and influence the visual outcome or impairment. We performed extensive chart reviews trying to establish this timeframe. Unfortunately, this data point could not be determined with the necessary accuracy because the documented clinical histories were terse, owing to the emergency nature of the condition and because the initial time course was unclear in some patients transferred from other hospitals. Furthermore, the level of detail of the visual examinations at discharge was heterogeneous due to the retrospective nature of our study. While some patients received

consults from the ophthalmologic service, not all patients did (especially when subjective vision was satisfactory).

One of the limitations of our study is that the specificity of these imaging findings cannot be derived from our data. In clinical practice, it is not unusual to observe some amount of intraorbital hematoma on CT after facial trauma. However, only a small minority develops compartment syndrome.²⁰ Determining the specificity of the proposed triad retrospectively is challenging because a “fair control group” would need to be matched not only for the volume of the space-occupying pathology but also for clinical parameters. Because the diagnosis of OCS still remains clinical, a prospective evaluation based on imaging diagnosis is limited.

Further research is necessary to clarify which patients require urgent decompression. Due to the time delay inherently associated with imaging studies, radiologic evaluation should be reserved for ambiguous cases.²¹

In summary, the proposed imaging phenotype should not be understood as diagnostic of OCS but as an indication that OCS might be present, implying that urgent clinical attention is warranted. In this context, we have to bear in mind that CT can detect only structural abnormalities. By contrast, the clinical examination can also reveal visual impairment or other functional deficits. Principally, OCS remains a clinical diagnosis, and imaging procedures must not delay emergency decompression if the diagnosis has already been established on clinical grounds. However, CT can be a decisive factor in decision-making when the clinical examination is limited, eg, in children, in patients who are unconscious or who have received opioids (impairing pupillary reflexes), and in the presence of profuse periorbital hematoma, which impairs palpation of the globe.

CONCLUSIONS

Proptosis and optic nerve stretching are signs of vision-threatening OCS, which may require urgent surgical decompression. In more severe cases, the posterior globe may be tented. In this collective of traumatic OCS, we have found that the expanding pathology can be located anywhere in the orbit, with or without direct contact with the optic nerve. Coexisting “decompressing” fractures do not exclude OCS. Clinicians who are not specialized in maxillofacial surgery or ophthalmology may be unaware of the condition. Radiologists can play a key role in patient management by raising the suspicion of OCS and initiating an urgent referral to a specialist.

ACKNOWLEDGMENTS

Dr Jan Voss is a participant in the Berlin Institute of Health Charité Clinician Scientist Program funded by the Charité–Universitätsmedizin Berlin and the Berlin Institute of Health.

Disclosure forms provided by the authors are available with the full text and PDF of this article at www.ajnr.org.

REFERENCES

1. Lima V, Burt B, Leibovitch I, et al. **Orbital compartment syndrome: the ophthalmic surgical emergency.** *Surv Ophthalmol* 2009;54:441–49 [CrossRef Medline](#)
2. Bailey WK, Kuo PC, Evans LS. **Diagnosis and treatment of retrobulbar hemorrhage.** *J Oral Maxillofac Surg* 1993;51:780–82 [CrossRef Medline](#)
3. Hargaden M, Goldberg SH, Cunningham D, et al. **Optic neuropathy following simulation of orbital hemorrhage in the nonhuman primate.** *Ophthalmic Plast Reconstr Surg* 1996;12:264–72 [CrossRef Medline](#)
4. Vassallo S, Hartstein M, Howard D, et al. **Traumatic retrobulbar hemorrhage: emergent decompression by lateral canthotomy and cantholysis.** *J Emerg Med* 2002;22:251–56 [CrossRef Medline](#)
5. Ballard SR, Enzenauer RW, O'Donnell T, et al. **Emergency lateral canthotomy and cantholysis: a simple procedure to preserve vision from sight threatening orbital hemorrhage.** *J Spec Oper Med* 2009;9:26–32 [CrossRef Medline](#)
6. Oestern HJ. **Compartment syndrome: definition, etiology, pathophysiology** [in German]. *Unfallchirurg* 1991;94:210–15 [Medline](#)
7. Reszel PA, Janes JM, Spittell JA. **Ischemic necrosis of the peroneal musculature: a lateral compartment syndrome.** *Proc Staff Meet Mayo Clin* 1963;38:130–36 [Medline](#)
8. Von Volkman R. **Ischämische Muskellähmungen und kontrakturen (Ischemic muscle paralysis and contractures).** *Zentralbl Chir* 1881;8:801–03
9. Alford EL, Soparkar CN. **Management of the ‘tight orbit’ and associated visual loss.** *Curr Opin Otolaryngol Head Neck Surg* 2013;21:417–22 [CrossRef Medline](#)
10. Dalley RW, Robertson WD, Rootman J. **Globe tenting: a sign of increased orbital tension.** *AJNR Am J Neuroradiol* 1989;10:181–86 [Medline](#)
11. Oester AE, Sahu P, Fowler B, et al. **Radiographic predictors of visual outcome in orbital compartment syndrome.** *Ophthalmic Plast Reconstr Surg* 2012;28:7–10 [CrossRef Medline](#)
12. Voss JO, Hartwig S, Doll C, et al. **The “tight orbit”: incidence and management of the orbital compartment syndrome.** *J Craniomaxillofac Surg* 2016;44:1008–14 [CrossRef Medline](#)
13. Gibson RD. **Measurement of proptosis (exophthalmos) by computerised tomography.** *Australas Radiol* 1984;28:9–11 [CrossRef Medline](#)
14. Stanley RJ, McCaffrey TV, Offord KP, et al. **Space-occupying orbital lesions: can critical increases in intraorbital pressure be predicted clinically?** *Laryngoscope* 1989;99:19–22 [CrossRef Medline](#)
15. Zoumalan CI, Bullock JD, Warwar RE, et al. **Evaluation of intraocular and orbital pressure in the management of orbital hemorrhage: an experimental model.** *Arch Ophthalmol* 2008;126:1257–60 [CrossRef Medline](#)
16. Badakere A, Patil-Chhablani P. **Orbital apex syndrome: a review.** *Eye Brain* 2019;11:63–72 [CrossRef Medline](#)
17. Perry M. **Acute proptosis in trauma: retrobulbar hemorrhage or orbital compartment syndrome—does it really matter?** *J Oral Maxillofac Surg* 2008;66:1913–20 [CrossRef Medline](#)
18. Rocca F, Boffano P, Guglielmi V, et al. **Role of the maxillofacial surgeon in the management of severe ocular injuries after maxillofacial fractures.** *J Emerg Trauma Shock* 2011;4:188–93 [CrossRef Medline](#)
19. Zogheib S, Sukkari G, Mjaess G, et al. **Displaced orbital fractures with concurrent orbital compartment syndrome: a case-based systematic review.** *Facial Plast Surg* 2022;38:274–78 [CrossRef Medline](#)
20. Kondoff M, Nassrallah G, Ross M, et al. **Incidence and outcomes of retrobulbar hematoma diagnosed by computed tomography in cases of orbital fracture.** *Can J Ophthalmol* 2019;54:606–10 [CrossRef Medline](#)
21. Erickson BP, Garcia GA. **Evidence-based algorithm for the management of acute traumatic retrobulbar haemorrhage.** *Br J Oral Maxillofac Surg* 2020;58:1091–96 [CrossRef Medline](#)